

Children and Adolescents with Knee Pain Need Diagnostics for Osteochondritis Dissecans

Christian Konrads* and Thomas Barthel

Orthopaedic Clinic Koenig-Ludwig-Haus, Center for Musculoskeletal Research, Julius-Maximilians-University Wuerzburg, Brettreichstr-11, 97074 Wuerzburg, Germany

Osteochondritis dissecans (OCD) of the knee is the most common osteochondral lesion. We see this disease particularly in children and adolescents. Patients usually present with unspecific knee pain. The cause of this condition is not completely known. Undiagnosed it can lead to early secondary arthritis.

OCD is a spatially limited pathology of the subchondral bone. An osteochondral fragment demarcates from the adjacent bone and becomes unstable. In the further course of the disease we find a demarcation on the cartilage surface. In end stage the osteochondral fragment dissecates and becomes a loose body in the joint. It can promote mechanical symptoms like joint blockage [1].

In the 16th century Ambroise Paré firstly described loose bodies in knee joints. In 1887 the German surgeon Franz König introduced the designation “osteochondritis dissecans” [2].

Although the etiology ultimately remains unclear, experts believe causes for OCD might be insufficient perfusion of the subchondral bone and repetitive microtraumata [3,4]. Studies in twins suggest a genetic component in etiology [5].

OCD can occur in different joints. Almost always it appears on convex joint surfaces. In 75% of cases with OCD the knee is involved; followed by ankle, elbow, hip, and shoulder [6,7]. It's prevalence for the knee in the western population is 6/10,000 inhabitants with a peak age between ten and 20. In up to 80 % of cases with OCD in the knee joint, the pathology is located in the lateral part of the medial femoral condyle; in 15 to 20% the pathology is located in the lateral femoral condyle [8]. In ten to five percent of all cases with involvement of the knee, OCD is found in the femoral trochlea or patella. Those atypical locations have a worse prognosis than OCD of the medial femoral condyle [9,10]. In up to 40 % the pathology involves both knees [11]. According to open or closed growth plates, we differentiate between juvenile or adult OCD; the juvenile form has a better prognosis [12].

Based on experience in our orthopaedic center and due to its unique pathoanatomic course, we recommend to distinguish OCD from other osteochondral lesions like flake fractures [13,14]. Classification of OCD is possible on the basis of x-rays, MRI, arthroscopy, or a combination of these [15-18]. In daily practice differentiation between stable or unstable lesions and between intact or broken cartilage surface is important. Synopsis of the mentioned diagnostic instruments with special emphasis on MRI is reasonable respecting the pathoanatomic course. For classification and treatment planning see Tables 1 and 2.

Stable OCD - stage 1 and 2- can be treated by physical conservation [19,20]. Non-operative treatment of stage 2 is sometimes unsuccessful, even in young patients with open growth plates. A failure rate of up to 50% was reported [21]. Then retrograde drilling is indicated in order to improve subchondral perfusion. In unstable OCD - stage 3 and 4- regularly operative treatment is indicated.

Crucial differentiation between stage 2 and 3 is possible in T2-weighted MRI: a hyperintense line under the dissecate indicates an unstable lesion. An additional instability criterium is discontinuity of the cartilage surface [22]. Figure 1 illustrates such a case, where

operative treatment is indicated: (1) debridement of the delimiting sclerosis, (2) cancellous bone grafting from the tibial head, and (3) refixation of the osteochondral fragment in one procedure.

Especially in children and adolescents suffering knee pain without trauma, we need to exclude OCD. After taking history and performing standard clinical examination, MRI is the best non-invasive diagnostic instrument. Its sensitivity and specificity (up to 100%) are very good and better than x-rays. There is no radiation exposure to the patient.

Stage	X-rays	MRI	Arthroscopy
I	normal	cartilage intact, normal signal change subchondral	normal
II	radiolucency and sclerosis	hypointense dissecate demarcation	cartilage on OCD-border softened, not demarcated
III _D	sclerosis, demarcated dissecate in situ	cartilage demarcation in T1 and hyperintense line in T2 under the dissecate in situ	dissecate demarcated, cartilage on OCD-border partially or completely interrupted
III _M	sclerosis, demarcated fragmented dissecate in situ	cartilage demarcation in T1 and hyperintense line in T2 under the fragmented dissecate	dissecate demarcated and fragmented, cartilage on OCD-border partially or completely interrupted
IV _D	empty dissecate bed, loose body	empty dissecate bed, loose body	empty dissecate bed, loose body, dissecate fixable
IV _M	empty dissecate bed, loose body	empty dissecate bed, loose body	empty dissecate bed, loose body, dissecate destroyed

D Dissecans; M Malacia, multi-fragmented

Table 1: Classification of osteochondritis dissecans [19].

Stage	Stability	Therapy
I	stable	conservative
II	stable	retrograde drilling
III _D	Unstable	bone grafting and refixation
III _M	Unstable	bone grafting and refixation (partially) or debridement/partial debridement, bone grafting, cartilage therapy
IV _D	Unstable	bone grafting and refixation
IV _M	Unstable	debridement, bone grafting, cartilage therapy

D Dissecans; M Malacia, multi-fragmented

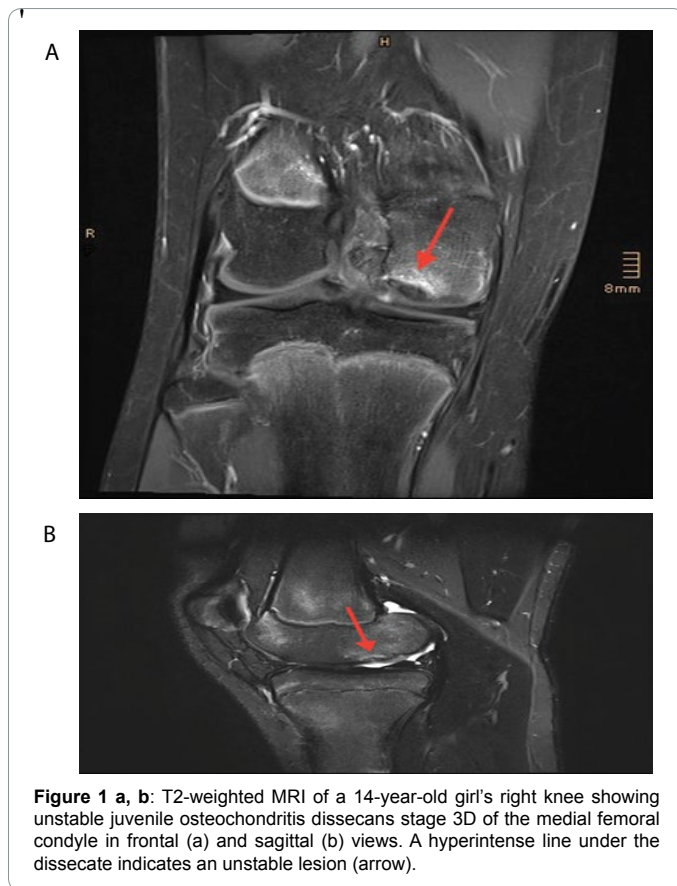
Table 2: Stage oriented therapy of osteochondritis dissecans of the knee [14].

*Corresponding author: Christian Konrads, Orthopaedic Clinic Koenig-Ludwig-Haus, Center for Musculoskeletal Research, Julius-Maximilians-University Wuerzburg, Brettreichstr-11, 97074 Wuerzburg, Germany, Tel: 004917655207825; E-mail: christian.konrads@gmail.com

Received November 24, 2015; Accepted December 16, 2015; Published December 21, 2015

Citation: Konrads C, Barthel T (2015) Children and Adolescents with Knee Pain Need Diagnostics for Osteochondritis Dissecans. Pain Manage Med 2: 107.

Copyright: © 2015 Konrads C, et al. This is an open-access article distributed under the terms of the Creative Commons Attribution License, which permits unrestricted use, distribution, and reproduction in any medium, provided the original author and source are credited.



Classification and stage depending orthopaedic treatment is important for a good outcome. Untreated OCD can progress leading to severe local joint damage and secondary joint destruction [23].

References

1. Schenck RC Jr, Goodnight JM (1996) Osteochondritis dissecans. *J Bone Joint Surg Am* 78: 439-456.
2. König F (2013) The classic: On loose bodies in the joint. 1887. *Clin Orthop Relat Res* 471: 1107-1115.
3. Shea KG, Jacobs JC Jr, Carey JL, Anderson AF, Oxford JT (2013) Osteochondritis dissecans knee histology studies have variable findings and theories of etiology. *Clin Orthop Relat Res* 471: 1127-1136.
4. Garrett JC (1991) Osteochondritis dissecans. *Clin Sports Med* 10: 569-593.

5. Gans I, Sarkissian EJ, Grant SF, Ganley TJ (2013) Identical osteochondritis dissecans lesions of the knee in sets of monozygotic twins. *Orthopedics* 36: e1559-1562.
6. Cahill BR (1995) Osteochondritis Dissecans of the Knee: Treatment of Juvenile and Adult Forms. *J Am Acad Orthop Surg* 3: 237-247.
7. Robertson W, Kelly BT, Green DW (2003) Osteochondritis dissecans of the knee in children. *Curr Opin Pediatr* 15: 38-44.
8. Flynn JM, Kocher MS, Ganley TJ (2004) Osteochondritis dissecans of the knee. *J Pediatr Orthop* 24: 434-443.
9. Hefti F, Beguiristain J, Krauspe R, Möller-Madsen B, Riccio V, et al. (1999) Osteochondritis dissecans: a multicenter study of the European Pediatric Orthopedic Society. *J Pediatr Orthop B* 8: 231-245.
10. Peterson L, Minas T, Brittberg M, Lindahl A (2003) Treatment of osteochondritis dissecans of the knee with autologous chondrocyte transplantation: results at two to ten years. *J Bone Joint Surg Am* 85-85A Suppl 2: 17-24.
11. Kutscha-Lissberg F, Singer P, Vécsei V, Marlovits S (2004) [Osteochondritis dissecans of the knee joint]. *Radiologe* 44: 783-788.
12. Federico DJ, Lynch JK, Jokl P (1990) Osteochondritis dissecans of the knee: a historical review of etiology and treatment. *Arthroscopy* 6: 190-197.
13. Dettlerline AJ, Goldstein JL, Rue JP, Bach BR Jr (2008) Evaluation and treatment of osteochondritis dissecans lesions of the knee. *J Knee Surg* 21: 106-115.
14. Konrads C, Schultheiß J, Reppenhagen S, Rudert M, Barthel T (2015) [Why does the knee hurt?]. *MMW Fortschr Med* 157: 53-56.
15. Bohndorf K (1998) Osteochondritis (osteochondrosis) dissecans: a review and new MRI classification. *Eur Radiol* 8: 103-112.
16. Dipaola JD, Nelson DW, Colville MR (1991) Characterizing osteochondral lesions by magnetic resonance imaging. *Arthroscopy* 7: 101-104.
17. Guhl JF (1982) Arthroscopic treatment of osteochondritis dissecans. *Clin Orthop Relat Res* : 65-74.
18. Mesgarzadeh M, Sapega AA, Bonakdarpour A, Revesz G, Moyer RA, et al. (1987) Osteochondritis dissecans: analysis of mechanical stability with radiography, scintigraphy, and MR imaging. *Radiology* 165: 775-780.
19. Bruns J (1997) [Osteochondrosis dissecans]. *Orthopade* 26: 573-584.
20. Wall EJ, Vourazeris J, Myer GD, Emery KH, Divine JG, et al. (2008) The healing potential of stable juvenile osteochondritis dissecans knee lesions. *J Bone Joint Surg Am* 90: 2655-2664.
21. Krause M, Hapfelmeier A, Möller M, Amling M, Bohndorf K, et al. (2013) Healing predictors of stable juvenile osteochondritis dissecans knee lesions after 6 and 12 months of nonoperative treatment. *Am J Sports Med* 41: 2384-2391.
22. O'Connor MA, Palaniappan M, Khan N, Bruce CE (2002) Osteochondritis dissecans of the knee in children. A comparison of MRI and arthroscopic findings. *J Bone Joint Surg Br* 84: 258-262.
23. Kijowski R, Blankenbaker DG, Shinki K, Fine JP, Graf BK, et al. (2008) Juvenile versus adult osteochondritis dissecans of the knee: appropriate MR imaging criteria for instability. *Radiology* 248: 571-578.

Citation: Konrads C, Barthel T (2015) Children and Adolescents with Knee Pain Need Diagnostics for Osteochondritis Dissecans. *Pain Manage Med* 2: 107.

OMICS International: Publication Benefits & Features

Unique features:

- Increased global visibility of articles through worldwide distribution and indexing
- Showcasing recent research output in a timely and updated manner
- Special issues on the current trends of scientific research

Special features:

- 700 Open Access Journals
- 50,000 editorial team
- Rapid review process
- Quality and quick editorial, review and publication processing
- Indexing at PubMed (partial), Scopus, EBSCO, Index Copernicus and Google Scholar etc
- Sharing Option: Social Networking Enabled
- Authors, Reviewers and Editors rewarded with online Scientific Credits
- Better discount for your subsequent articles

Submit your manuscript at: www.editorialmanager.com/medicalsciences