



ELSEVIER

Contents lists available at ScienceDirect

JSES International

journal homepage: www.jseinternational.org

Infection control and outcome of staged reverse shoulder arthroplasty for the management of shoulder infections



Sebastian Philipp Boelch, MD ^{a,*}, Laura Elisa Streck, MD ^{a,1}, Piet Plumhoff, MD ^a, Christian Konrads, MD ^b, Frank Gohlke, MD ^c, Kilian Rueckl, MD ^a

^a Department of Orthopaedic Surgery, University of Wuerzburg, Koenig-Ludwig-Haus, Wuerzburg, Germany

^b Department for Traumatology and Reconstructive Surgery, BG Trauma Center, University of Tübingen, Tübingen, Germany

^c Klinik für Schulter- und Ellenbogenchirurgie, Rhön-Klinikum, Bad Neustadt/Saale, Germany

ARTICLE INFO

Keywords:

Shoulder infection
periprosthetic infection
two stage
spacer
reverse shoulder arthroplasty
shoulder arthroplasty
outcome

Level of evidence: Level IV; Case Series; Treatment Study

Background: The treatment of septic arthritis, caused by either hematogenous seeding, injections, or surgery, can be challenging. Staged reverse shoulder arthroplasty (RSA) with temporary implantation of an antibiotic-loaded spacer is widely accepted but still discussed controversially. This study investigated the shoulder-specific bacterial spectrum, infection control rate, functional outcome, and infection-free survival rate after staged RSA in the mid- to long-term follow-up. It was hypothesized that staged RSA would show a high infection-free survival rate.

Methods: A total of 39 patients treated with staged RSA for primary septic arthritis (n = 8), secondary infection (n = 8), or periprosthetic infection (n = 23) were retrospectively included. The infection control rate was calculated based on cultures taken intraoperatively at spacer removal and RSA implantation. Infection-free survival was defined as no revision due to infection. The minimum follow-up period for functional outcome assessment was 2 years (n = 14; mean, 76 months; range, 31–128 months).

Results: *Cutibacterium* (26%) and coagulase-negative staphylococci (23%) were the predominant pathogens. The infection control rate was 90%. The cumulative infection-free survival rate was 91% after 128 months. Follow-up examinations showed a mean Constant score of 48 (range, 7–85), a mean QuickDASH (short version of Disabilities of the Arm, Shoulder and Hand questionnaire) score of 40.0 (range, 11.4–93.3), and a mean pain score of 1.6 (range, 0–7).

Conclusion: Staged RSA implantation was confirmed to be a reliable treatment option for primary, secondary, and periprosthetic infections of the shoulder. The infection control rate and infection-free survival rate are satisfactory. However, patients and surgeons must be aware of functional impairment even after successful treatment of infections.

© 2020 The Author(s). Published by Elsevier Inc. on behalf of American Shoulder and Elbow Surgeons. This is an open access article under the CC BY-NC-ND license (<http://creativecommons.org/licenses/by-nc-nd/4.0/>).

Infections of the shoulder (SIs) have a reported incidence of 0.3%–6%. These joint infections come along with serious morbidity and death.^{5,6,21,26} Chronic SIs appear as primary septic arthritis of the native joint, as secondary infections of an operated joint, or as periprosthetic infections. The clinical presentation of SIs is multifaceted, and definitions and treatment modalities are inconsistent. Next to the patient's history and clinical findings such as erythema, purulence, or even the presence of a sinus tract, preoperative

diagnosis of an SI relies on blood infection markers, imaging, and joint aspiration.²⁰

Although under debate, the most common pathogens for SIs are *Cutibacterium* and coagulase-negative Staphylococci.^{16,24,27} These bacteria are able to form biofilms, and thus, SIs might cause only mild symptoms, also regarded as low-grade infections.^{1,22,23} Therefore, it is not bewildering that the definition of “infection” is constantly refined.^{18,25} Still, the gold standard for the definition of joint infection is repeated pathogen detection from multiple-tissue sampling.^{16,17,19}

Hence, SI often remains a postoperative diagnosis. Even with negative tissue sample findings, there are cases in which a SI cannot ultimately be ruled out. In these cases, a SI rather appears to be “unlikely” as described by the latest shoulder-specific periprosthetic infection scoring system introduced by the International Consensus Meeting (ICM) in 2018.¹¹

The study received institutional review board approval from our university's review board (Ethik-Kommission der Universität Würzburg, no. 235/16-mk).

* Corresponding author: Sebastian Philipp Boelch, Department of Orthopaedic Surgery, University of Wuerzburg, Koenig-Ludwig-Haus, Brettreichstrasse 11, 97074 Wuerzburg, Germany.

E-mail address: s-boelch.klh@uni-wuerzburg.de (S.P. Boelch).

¹ These authors contributed equally to this work.

<https://doi.org/10.1016/j.jseint.2020.08.012>

2666-6383/© 2020 The Author(s). Published by Elsevier Inc. on behalf of American Shoulder and Elbow Surgeons. This is an open access article under the CC BY-NC-ND license (<http://creativecommons.org/licenses/by-nc-nd/4.0/>).

Joint preservation by either arthroscopic or, in selected cases, open débridement should be the aim of the treatment of primary and secondary SIs. Nonetheless, if joint-preserving attempts fail or if pannus infiltrates the cartilage and/or bone, sufficient débridement includes sacrificing the joint surfaces.

After meticulous débridement of the articular surface and eradication of the infection, the joint can only be restored by arthroplasty. In these cases, a 2-stage procedure is a reasonable treatment option.¹² The 2-stage procedure comprises infection control by removal of indwelling hardware, soft-tissue and bony débridement with implantation of an antibiotic-loaded spacer, and joint reconstruction with a prosthesis for pain resolution and restoration of function.

The aim of this study was to investigate our treatment regimen with staged reverse shoulder arthroplasty (RSA) after spacer implantation for the treatment of SIs. We describe (1) the specific bacterial spectrum of SIs, (2) the infection control rate with staged RSA, (3) the functional outcome, and (4) the infection-free survival rate after prosthesis implantation. It was hypothesized that staged RSA would show a high infection-free survival rate.

Materials and methods

Patients

Using a retrospective study design, we identified 41 patients who underwent staged reverse total shoulder arthroplasty after temporary implantation of a spacer for the treatment of SIs between 2007 and 2015. Two patients with implantation of an anatomic prosthesis at joint reconstruction were excluded; thus, this study comprised 39 patients with staged RSA.

The mean age was 72 years (range, 45-85 years). Women comprised 69% of patients. The mean body mass index (BMI) was 28.1 kg/m² (range, 18.3-47.5 kg/m²). Of the patients, 30% were obese (BMI > 30 kg/m²). Diabetes mellitus was present in 21% of patients, and rheumatic disease was noted in 9%. One patient (3%) was classified as American Society of Anesthesiologists (ASA) class 1; 38%, ASA class 2; and 59%, ASA class 3. A periprosthetic infection was diagnosed in 59% of patients, whereas primary and secondary infections were diagnosed in 21% each. One of the primary SIs was iatrogenic by cortisone infiltration. Among patients with secondary infections, 6 (75%) underwent osteosynthesis after fracture of the proximal humerus and 2 underwent rotator cuff surgery. The mean duration from surgery to spacer implantation was 24.5 months (range, 2-127 months).

Table I provides differences in the distributions of common risk factors for infection (diabetes mellitus, smoker, age, and BMI). In the subgroup with ASA class 3, the percentage of patients with primary infection was higher than the percentage with secondary infection (*P* = .030) but not the percentage with periprosthetic infection (*P* = .105). Furthermore, the ASA class was not different between secondary and periprosthetic infections (*P* = .947).

Table I
Distribution of risk factors in patients with primary, secondary, and periprosthetic infection

Risk factor	Type of infection, %			Difference between groups: <i>P</i> value (Fisher exact test)
	Primary	Secondary	Periprosthetic	
Rheumatoid arthritis	12.5	0.0	8.7	>.999
Diabetes mellitus	12.5	25.0	22.7	>.999
Smoker	0.0	12.5	13.6	.800
ASA class 3	100.0	50.0	47.8	.029*
BMI > 30 kg/m ²	12.5	39.1	62.5	.132

ASA, American Society of Anesthesiologists; BMI, body mass index.

* Statistically significant.

Definition of infection

Infection was retrospectively diagnosed based on the ICM 2018 infection scoring system by the patient’s history and clinical examination findings, as well as the following blood markers: C-reactive protein (CRP) level, white blood cell count, and erythrocyte sedimentation rate (ESR). In selected cases, preoperative joint aspiration was performed and the aspirate was evaluated. Tissue samples for culture and histopathologic assessment at spacer implantation were also obtained. According to ICM criteria, 44% of cases were considered definite infection; 20%, probable infection; 5%, possible infection; and 31%, infection unlikely.¹¹ However, these patients were included because the clinical presentation was highly suggestive of infection (eg, fever and chills) or because of positive microbiological culture findings obtained during previous surgery. According to the ICM 2018 criteria for prosthesis implantation following prior septic arthritis a 2-stage procedure was indicated.¹²

Treatment protocol

A deltopectoral approach was used in all cases. All hardware and sutures were removed, followed by soft-tissue and bone débridement. Tissue samples were collected for cultures and histopathologic evaluation. Irrigation was performed by means of a pulsatile pressure lavage. Then, a handmade spacer around a bent Steinmann pin was implanted using gentamicin-impregnated Palacos bone cement (Palacos R+G; Heraeus Medical, Wehrheim, Germany). In 35 cases (90%), vancomycin was added by manual mixing; in 1 case, premixed bone cement containing gentamicin and clindamycin (Copal G+C; Heraeus Medical) was used instead. Tailored antibiotics as recommended by antimicrobial stewardship were given for ≥14 days intravenously, followed by oral administration. The mean duration of the spacer interval was 13 weeks (range, 4-55 weeks). The time of spacer removal and RSA implantation was dependent on wound healing and the course of blood infection parameters. Stem fixation was performed using gentamicin-impregnated Palacos (Palacos R+G). The type of prosthesis used was the Aequalis Reversed II prosthesis (Wright, Middlesex, UK) in all but 1 patient, who needed a nickel-free coated Aequalis Reversed FX prosthesis.

Infection control

Infection control was defined as no bacterial growth from the tissue samples collected at RSA implantation by at least 5 biopsies.

Functional outcome

Follow-up examinations were conducted at a minimum follow-up of 2 years after RSA implantation. These included active range of motion, strength measurement in 90° of abduction and 30° of anteversion (IsoBex; MDS, Oberburg, Switzerland), a visual analog

scale (VAS) score for pain (from 0, indicating no pain, to 10, indicating worst pain), the Constant score, and the QuickDASH (short version of Disabilities of the Arm, Shoulder and Hand questionnaire) score.^{3,8}

Infection-free survival

Infection-free survival was evaluated by data either from the last presentation to our clinic or at follow-up examinations. Infection-free survival was defined as no revision or, in case of revision, absence of infection following the surgical report. Data on complications after RSA other than septic failure were also tabulated.

Statistical analysis

Statistical analysis was performed with SPSS Statistics (IBM, Armonk, NY, USA) and Excel (Microsoft, Redmond, WA, USA). The confidence level was 95%. *P* < .05 was considered significant. The Mann-Whitney *U* test was used for normally distributed nonpaired samples. The Welch test was used for non-normally distributed nonpaired samples. The *t* test was used for normally distributed paired samples. The Wilcoxon test was used for non-normally distributed paired samples. The Fisher exact test was performed to compare parametric data. The infection-free survival rate was calculated by Kaplan-Meier analysis. Groups were compared by use of the log-rank test.

Results

Shoulder-specific bacterial spectrum

Cutibacterium (26%) and coagulase-negative Staphylococci (23%) were the predominant pathogens (Table II).

Infection control rate

The infection control rate was 90%. In 4 cases, cultures from RSA showed bacterial growth: *Cutibacterium* and *Kocuria varians* in 1 case each and *Staphylococcus epidermidis* in 2 cases. One of these patients underwent revision for periprosthetic infection 44 months after RSA. The remaining 3 patients with failed infection control, as defined in this study, remained free of re-infection at 21, 31, and 99 months after RSA implantation.

Functional outcome

A total of 25 patients were lost to final follow-up: 8 died, 9 were unable to present to our hospital, and 8 did not respond to attempted contact. Therefore, for a major proportion of the patients, only the clinical and radiologic status assessed at the first

Table II

Detected pathogens at spacer implantation grouped by primary, secondary, and periprosthetic infection

	Primary infection (n = 5), % (n)	Secondary infection (n = 8), % (n)	Periprosthetic infection (n = 22), % (n)
CNS	20.0 (1)	37.5 (3)	18.2 (3)
<i>Cutibacterium</i>		12.5 (1)	31.8 (7)
<i>Cutibacterium</i> and CNS		12.5 (1)	
<i>Staphylococcus aureus</i>			13.6 (2)
Other			13.6 (3)
None	80 (4)	37.5 (3)	31.8 (7)

CNS, coagulase-negative staphylococci.

clinical and radiologic controls was available. The mean follow-up period was 76 months (range, 31–128 months). The mean pain level was low, and the QuickDASH showed an overall score slightly better than “moderate difficulties.” These results are presented in Table III.

Infection-free survival rate

The Kaplan-Meier analysis of all 39 patients showed a cumulative infection-free survival rate of 91%. There was no significant difference between staged RSA for periprosthetic infection and that for primary or secondary infection, as depicted in Figure 1 (*P* = .288). Two patients had a re-infection: One patient underwent revision 13 months after RSA because of septic loosening. Tissue cultures at revision revealed the same germ, *Staphylococcus viridans*, as detected during the spacer implantation. However, tissue samples taken at the RSA implantation yielded no growth. The other patient underwent revision for septic loosening 44 months after RSA. At revision, the same germ was found as at primary RSA implantation (*Staphylococcus epidermidis*). But again, septic loosening occurred 14 days after a dental operation for an infected tooth.

We observed 2 more aseptic complications: One acromial fracture occurred 3 months after surgery without trauma. Conservative treatment with an abduction brace was successful. One traumatic periprosthetic humeral fracture occurred 4 years after surgery and was successfully treated with osteosynthesis and RSA retention.

Discussion

This study evaluated the mid- to long-term results of staged RSA with temporary implantation of an antibiotic-loaded articulating spacer for the treatment of primary, secondary, and periprosthetic infections of the shoulder joint. The bacterial spectrum was comparable to that in previous reports in the literature, with *Cutibacterium* and coagulase-negative Staphylococci being the predominant pathogens.^{9,24} With the described treatment strategy, we found a remarkably high infection control rate of 90% and a good cumulative survival rate of 91%. In the group of 14 patients with clinical follow-up, no re-infections were observed. However, although we observed moderate patient satisfaction, functional outcomes remained only satisfactory, mostly related to poor active range of motion.

There are limitations to this study. Although we can report on a long cumulative follow-up period of almost 11 years for infection-free survival, only 79% of patients underwent a documented follow-up assessment at >1 year and only 64% did so at >2 years. However, with the inclusion of 39 patients, our study reports on more patients than other studies focusing on staged RSA implantation. Jacquot et al¹³ published results on 14 patients undergoing 2-stage total shoulder arthroplasty exchange, with an infection-free survival rate of 64% after a mean follow-up period of 36 months. Sabesan et al²⁴ investigated the outcomes of 17 patients with staged RSA implantation after SIs and found an infection control rate of 94% and an identical infection-free survival rate after a mean follow-up period of 46 months.

In contrast to other protocols, primary and secondary SIs following surgical interventions were included in our study. These patients had a particularly high number of infections without pathogen detection. Previous joint-preserving infection eradication attempts with concomitant antibiotic therapy before spacer implantation are the most likely explanation for the high number of infections without pathogen detection. However, according to the ICM 2018 publication, staged arthroplasty with implantation of a temporary spacer is justified in patients with primary septic

Table III
Functional outcome in patients after staged RSA implantation with minimum follow-up of 2 years

	n	Mean (range)
Abduction	18	64° (30°-170°)
Flexion	19	113° (20°-180°)
Extension	14	20° (0°-60°)
Internal rotation	13	56° (10°-90°)
External rotation	15	12° (0°-40°)
Strength	14	2.8 kg (1.0-5.9 kg)
Constant score	14	48 (7-85)
QuickDASH score	14	40.0 (11.4-93.2)
Pain score (VAS)	14	1.6 (0-7)

RSA, reverse shoulder arthroplasty; QuickDASH, short version of Disabilities of the Arm, Shoulder and Hand questionnaire; VAS, visual analog scale.

arthritis.¹² The inclusion of these patients in this study is warranted by 3 aspects: (1) Biofilm formation should also be considered in primary infections because this has been described not only on implant surfaces but also on necrotic bone.¹⁵ The predominant germs encountered in our material are known for biofilm formation.^{1,22,23} (2) Although not assessed in this study, the soft-tissue envelope after multiple joint-preserving surgical attempts is often worse than in patients with infected total shoulder arthroplasties. The demographic data and analysis of the numbers of surgical procedures prior to spacer implantation revealed no significant differences among primary, secondary, and periprosthetic infections (Table 1). (3) All articulating spacers were implanted with a stem after débridement and lavage of the humeral medullary canal.

Thus, the precondition for RSA might be comparable in these patients. This is underlined by the comparison of infection-free survival between the indication groups that showed no significant difference. However, removal of implants during revision surgery carries a high risk of periprosthetic humeral fracture and secondary bone loss. Reimplantation in the case of severe bone deficiency can be more demanding and may yield worse outcomes in terms of postoperative complications (eg, implant loosening).

Infection control was evaluated based on intraoperative tissue samples rather than a more complex diagnostic algorithm. So far, it is unclear to what extent the rapidly decreasing release of antibiotics can influence the sensitivity of tissue cultures at reimplantation. Although derived from data on the hip and knee, other

markers for ongoing infection during 2-stage arthroplasty exchange are even more controversial.^{4,10} Kusuma et al¹⁴ even reported lower values of CRP and ESR for infection persistence during 2-stage exchange at the knee. In a previous study regarding 2-stage exchange at the hip, we found low diagnostic value for the CRP level and ESR for the evaluation of infection eradication.⁴ Histopathologic tissue assessment at reimplantation is also of limited usefulness.^{4,7,14} Crucial for infection control after a 2-stage procedure is re-infection-free survival. In the current study, 2 re-infections were observed. One patient had an early re-infection after RSA, which should be considered a recurrence because the same pathogen was detected as at the 2-stage procedure. The reason for the second failure remains unclear. Given the short interval to dental surgery, new hematogenous spread seems plausible.

Because of the retrospective study design, we were not able to collect data on preoperative function. Additionally, the rate of follow-up with clinical examination is extremely low, at 35.9%. Regardless, as reported by a few other studies focusing on staged RSA, the functional outcome can be unsatisfactory. Although significant increases in the Constant score and Penn score after 2-stage RSA have been described, absolute postoperative scores are consistently low: Jacquot et al¹³ reported a Constant score of 44, and Sabesan et al²⁴ reported a mean Penn score of 66.4. Grubhofer et al⁹ found a postoperative absolute Constant score of 51.1 in their subgroup analysis of 26 patients treated with RSA after 2-stage exchange for periprosthetic SIs. Whereas the Constant score includes strength measurement, the QuickDASH is an exclusively patient-reported measure. The QuickDASH score and pain level showed reasonable subjective results. This discrepancy between functional outcomes and subjective satisfaction is remarkable. Therefore, it is mandatory to discuss limited expectations with the patient prior to surgery. On the other hand, the major proportion of our patients had severe comorbidities, such as a high ASA score, diabetes, and obesity, which have a negative impact on the immune response.² If a joint-preserving approach fails, the main intention of staged RSA is eradication of an infection that otherwise might well spread and become a life-threatening disease.

Conclusion

Staged RSA implantation is a reliable treatment option for primary, secondary, and periprosthetic SIs. The infection control rate

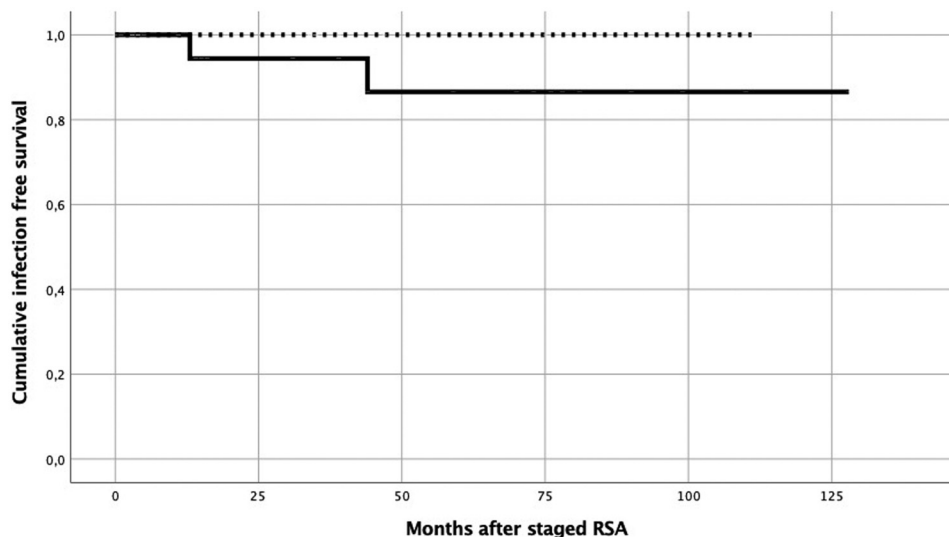


Figure 1 Kaplan-Meier curve for infection-free survival rate after staged reverse shoulder arthroplasty (RSA) implantation. The — indicates survival after staged RSA for primary or secondary infection. The - - - indicates survival for staged RSA after periprosthetic infection.

and the infection-free survival rate are promising. However, function remains poor, although the pain level is low. Both the patient and the surgeon should be aware of poor functional outcomes in a higher proportion.

Disclaimer

This publication was supported by the Open Access Publication Fund of the University of Wuerzburg

The authors, their immediate families, and any research foundations with which they are affiliated have not received any financial payments or other benefits from any commercial entity related to the subject of this article.

References

- Achermann Y, Goldstein EJ, Coenye T, Shirtliff ME. Propionibacterium acnes: from commensal to opportunistic biofilm-associated implant pathogen. *Clin Microbiol Rev* 2014;27:419–40. <https://doi.org/10.1128/CMR.00092-13>.
- Andersen CJ, Murphy KE, Fernandez ML. Impact of obesity and metabolic syndrome on immunity. *Adv Nutr* 2016;7:66–75. <https://doi.org/10.3945/an.115.010207>.
- Beaton DE, Wright JG, Katz JN, Upper Extremity Collaborative Group. Development of the QuickDASH: comparison of three item-reduction approaches. *J Bone Joint Surg Am* 2005;87:1038–46. <https://doi.org/10.2106/JBJS.D.02060>.
- Boelch SP, Weissenberger M, Spohn F, Rudert M, Luedemann M. Insufficient sensitivity of joint aspiration during the two-stage exchange of the hip with spacers. *J Orthop Surg Res* 2018;13:7. <https://doi.org/10.1186/s13018-017-0703-z>.
- Bohsali KI, Wirth MA, Rockwood CA Jr. Complications of total shoulder arthroplasty. *J Bone Joint Surg Am* 2006;88:2279–92. <https://doi.org/10.2106/JBJS.F.00125>.
- Cancienne JM, Brockmeier SF, Carson EW, Werner BC. Risk factors for infection after shoulder arthroscopy in a large Medicare population. *Am J Sports Med* 2018;46:809–14. <https://doi.org/10.1177/0363546517749212>.
- Cho WS, Byun SE, Cho WJ, Yoon YS, Dhurve K. Polymorphonuclear cell count on frozen section is not an absolute index of reimplantation in infected total knee arthroplasty. *J Arthroplasty* 2013;28:1874–7. <https://doi.org/10.1016/j.arth.2013.03.016>.
- Constant CR. Assessment of shoulder function. *Orthopade* 1991;20:289–94 [in German].
- Grubhofer F, Imam MA, Wieser K, Achermann Y, Meyer DC, Gerber C. Staged revision with antibiotic spacers for shoulder prosthetic joint infections yields high infection control. *Clin Orthop Relat Res* 2018;476:146–52. <https://doi.org/10.1007/s11999-0000000000000049>.
- Hoell S, Moeller A, Gosheger G, Harges J, Dieckmann R, Schulz D. Two-stage revision arthroplasty for periprosthetic joint infections: what is the value of cultures and white cell count in synovial fluid and CRP in serum before second stage reimplantation? *Arch Orthop Trauma Surg* 2016;136:447–52. <https://doi.org/10.1007/s00402-015-2404-6>.
- Javad P, Thorsten G. Shoulder. In: *Proceedings of the International Consensus on Periprosthetic Joint Infection 2018*; 2018.
- Javad P, Thorsten G. Hip and knee. In: *Proceedings of the International Consensus on Periprosthetic Joint Infection 2018*; 2018.
- Jacquot A, Sirveaux F, Roche O, Favard L, Clavert P, Mole D. Surgical management of the infected reversed shoulder arthroplasty: a French multicenter study of reoperation in 32 patients. *J Shoulder Elbow Surg* 2015;24:1713–22. <https://doi.org/10.1016/j.jse.2015.03.007>.
- Kusuma SK, Ward J, Jacofsky M, Sporer SM, Della Valle CJ. What is the role of serological testing between stages of two-stage reconstruction of the infected prosthetic knee? *Clin Orthop Relat Res* 2011;469:1002–8. <https://doi.org/10.1007/s11999-010-1619-7>.
- Muthukrishnan G, Masters EA, Daiss JL, Schwarz EM. Mechanisms of immune evasion and bone tissue colonization that make Staphylococcus aureus the primary pathogen in osteomyelitis. *Curr Osteoporos Rep* 2019;17:395–404. <https://doi.org/10.1007/s11914-019-00548-4>.
- Nelson GN, Davis DE, Namdari S. Outcomes in the treatment of periprosthetic joint infection after shoulder arthroplasty: a systematic review. *J Shoulder Elbow Surg* 2016;25:1337–45. <https://doi.org/10.1016/j.jse.2015.11.064>.
- Osmon DR, Berbari EF, Berendt AR, Lew D, Zimmerli W, Steckelberg JM, et al. Executive summary: diagnosis and management of prosthetic joint infection: clinical practice guidelines by the Infectious Diseases Society of America. *Clin Infect Dis* 2013;56:1–10. <https://doi.org/10.1093/cid/cis966>.
- Parvizi J, Gehrke T, Chen AF. Proceedings of the International Consensus on Periprosthetic Joint Infection. *Bone Joint J* 2013;95-B:1450–2. <https://doi.org/10.1302/0301-620X.95B11.33135>.
- Parvizi J, Zmistowski B, Berbari EF, Bauer TW, Springer BD, Della Valle CJ, et al. New definition for periprosthetic joint infection: from the Workgroup of the Musculoskeletal Infection Society. *Clin Orthop Relat Res* 2011;469:2992–4. <https://doi.org/10.1007/s11999-011-2102-9>.
- Ochsner PE, Borens O, Bodler P-M, Broger I, Eich G, Hefti F, et al. Infections of the musculoskeletal system. Basic principles, prevention, diagnosis and treatment. Grandvaux, Switzerland: Swiss Society for Infectious Diseases Expert Group “Infections of the Musculoskeletal System”; 2016.
- Pulido L, Ghanem E, Joshi A, Purtill JJ, Parvizi J. Periprosthetic joint infection: the incidence, timing, and predisposing factors. *Clin Orthop Relat Res* 2008;466:1710–5. <https://doi.org/10.1007/s11999-008-0209-4>.
- Renz N, Muller M, Perka C, Trampuz A. Implant-associated infections—diagnostics. *Chirurg* 2016;87:813–21 [in German]. <https://doi.org/10.1007/s00104-016-0234-x>.
- Rohde H, Burandt EC, Siemssen N, Frommelt L, Burdelski C, Wurster S, et al. Polysaccharide intercellular adhesin or protein factors in biofilm accumulation of Staphylococcus epidermidis and Staphylococcus aureus isolated from prosthetic hip and knee joint infections. *Biomaterials* 2007;28:1711–20. <https://doi.org/10.1016/j.biomaterials.2006.11.046>.
- Sabesan VJ, Ho JC, Kovacevic D, Iannotti JP. Two-stage reimplantation for treating prosthetic shoulder infections. *Clin Orthop Relat Res* 2011;469:2538–43. <https://doi.org/10.1007/s11999-011-1774-5>.
- Sendi P, Zimmerli W. Diagnosis of periprosthetic joint infections in clinical practice. *Int J Artif Organs* 2012;35:913–22. <https://doi.org/10.5301/ijao.5000150>.
- Sperling JW, Kozak TK, Hanssen AD, Cofield RH. Infection after shoulder arthroplasty. *Clin Orthop Relat Res* 2001;(382):206–16.
- Topolski MS, Chin PY, Sperling JW, Cofield RH. Revision shoulder arthroplasty with positive intraoperative cultures: the value of preoperative studies and intraoperative histology. *J Shoulder Elbow Surg* 2006;15:402–6. <https://doi.org/10.1016/j.jse.2005.10.001>.