

REVIEW

Endodontic management of traumatized permanent teeth: a comprehensive review

G. Krastl¹ , R. Weiger^{2,3}, A. Filippi^{3,4}, H. Van Waes⁵, K. Ebeleseder⁶, M. Ree⁷, T. Connert^{2,3} , M. Widbiller⁸ , L. Tjäderhane^{9,10}, P. M. H. Dummer¹¹  & K. Galler⁸

¹Department of Conservative Dentistry and Periodontology, Center of Dental Traumatology, University Hospital of Würzburg, Würzburg, Germany; ²Department of Periodontology, Endodontology and Cardiology, University School of Dental Medicine, Basel; ³Center of Dental Traumatology, University School of Dental Medicine, Basel; ⁴Department of Oral Surgery, University School of Dental Medicine, Basel; ⁵Department of Paediatric Dentistry, Clinic for Orthodontics and Paediatric Dentistry, University of Zürich, Zürich, Switzerland; ⁶University Clinic of Dental Medicine and Oral Health, Medical University Graz, Graz, Austria; ⁷Private Practice, Purmerend, Netherlands; ⁸Department of Conservative Dentistry and Periodontology, University Hospital Regensburg, Regensburg, Germany; ⁹Department of Oral and Maxillofacial Diseases, Helsinki University Hospital, University of Helsinki, Helsinki; ¹⁰Research Unit of Oral Health Sciences, Medical Research Center Oulu (MRC Oulu), Oulu University Hospital, University of Oulu, Oulu, Finland; and ¹¹School of Dentistry, College of Biomedical and Life Sciences, Cardiff University, Cardiff, UK

Abstract

Krastl G, Weiger R, Filippi A, Van Waes H, Ebeleseder K, Ree M, Connert T, Widbiller M, Tjäderhane L, Dummer PMH, Galler K. Endodontic management of traumatized permanent teeth: a comprehensive review. *International Endodontic Journal*, **54**, 1221–1245, 2021

The pulp plays a key role in the treatment of traumatic dental injuries (TDIs) and is strongly associated with the outcome, particularly in severe cases. A correct pulp diagnosis is essential as it forms the basis for developing the appropriate management strategy. However, many TDIs are complex, and their treatment requires a profound knowledge of the physiological and pathological responses of the affected tissues.

This comprehensive review will look at the dentine–pulp complex and its interaction with the surrounding tissues following TDIs. The literature up to 2020 was reviewed based on several searches on PubMed and the Cochrane Library using relevant terms. In addition to the recently revised guidelines of the International Association of Dental Traumatology, this article aims to provide background information with a focus on endodontic aspects and to gather evidence on which a clinician can make decisions on the choice of the appropriate endodontic approach for traumatized permanent teeth.

Keywords: avulsion, dental trauma, diagnosis, endodontic management, tooth fracture, tooth injuries.

Received 2 May 2020; accepted 5 March 2021

Introduction

Traumatic dental injuries (TDIs) are often associated with complex injury patterns, where correct diagnosis is of great importance as it forms the basis for

developing the appropriate management strategy. Most injuries can be broken down into smaller components and related to the affected tissues, namely dental hard tissues, dental pulp, periodontium, alveolar bone or gingiva (Ebeleseder 1994, Filippi *et al.*

Correspondence: Gabriel Krastl, Department of Conservative Dentistry and Periodontology, Center of Dental Traumatology, University Hospital of Würzburg, Pleicherwall 2, D-97070 Würzburg, Germany (e-mail: krastl_g@ukw.de).

This is an open access article under the terms of the Creative Commons Attribution License, which permits use, distribution and reproduction in any medium, provided the original work is properly cited.

2000, Andreasen *et al.* 2018). A traumatic dental injury should be considered an emergency and initially treated as such. Diagnostics involve detailed extra- and intraoral examinations, palpation, pulp testing, examination of tooth mobility or displacement as well as radiographic assessment. In addition, informative photographs are necessary, not only for the initial diagnosis but also for forensic reasons in order to prove that particular complications originate from the traumatic incident (Andreasen & Andreasen 1985). Crown fractures may reveal deep dentine wounds or pulpal exposure upon inspection, if necessary, after removal of a coronal fragment.

The time that has elapsed between injury and therapy is of importance, as it will influence the therapeutic approach and prognosis (Viduskalne & Care 2010). Crown–root fractures with pulp exposure or root fractures may not be obvious but become evident after careful radiographic examination. After dental trauma, radiographs provide information not only on potential fracture lines, but furthermore on the stage of root development, the size of pulp space and root canal (compared with the neighbouring teeth), resorptive processes or periapical lesions. Furthermore, initial radiographs serve as a reference for the follow-up appointments.

For the treatment of TDIs, multiple restorative, endodontic and periodontal factors have to be taken into account. The recently revised guidelines of the International Association of Dental Traumatology provide clear recommendations for the immediate and urgent care of TDIs (Bourguignon *et al.* 2020, Day *et al.* 2020, Fouad *et al.* 2020, Levin *et al.* 2020) but do not present detailed background information and do not report treatment outcome data. The present comprehensive review aims to provide an in-depth insight into the endodontic management of traumatized permanent teeth and empowers the clinician to select the appropriate endodontic approach by evaluating the outcomes of these treatments. The article focuses solely on the endodontic system and its interaction with the surrounding tissues. Conditions resulting from TDIs without endodontic relevance are not discussed.

A comprehensive literature search covering the period from 1966 to 2020 was conducted. The references were obtained via several searches on PubMed, and the Cochrane Library, using different keyword combinations including 'pulp', 'endodontic', 'dental trauma', 'traumatic dental injuries', 'crown fracture', 'crown root fracture', 'concussion', 'subluxation',

'extrusion', 'lateral luxation', 'intrusion' and 'avulsion'. Any relevant work published in the English language in peer-reviewed journals and presenting pertinent information related to the purpose of this overview was considered. In addition, bibliographies of all relevant papers and previous review articles were hand-searched and reference lists from textbooks with relevant information on TDIs were also reviewed. Finally, the personal databases of the authors were included in the search.

Assessing the status of the traumatized pulp

Assessing the status of an injured pulp is particularly important in order to establish a reference point for later follow-up. However, this task may be difficult for several reasons. Patient compliance is required, which might not be granted due to young patient age or distress after the traumatic impact, leading to false results. Commonly used sensibility tests are based on thermal or electric stimulation. Thermal tests activate hydrodynamic movement of fluid within dentinal tubules, which excites the A-delta fibres, whilst electric pulp tests result in a direct stimulation of the A-delta fibres (Jafarzadeh & Abbott 2010). Both tests are physiologically dependent on a functional vascular supply. Therefore, reaction to sensibility testing is used as an indirect indicator (surrogate) of a vital pulp. These limitations of conventional pulp testing make diagnostics following trauma challenging, as temporary loss of sensibility occurs frequently due to pulpal oedema after luxation injuries. In such cases, it may take a few to several weeks before a response to sensibility testing returns (Skieller 1960, Rock & Grundy 1981, Bastos *et al.* 2014). Thus, no reaction to sensibility testing after trauma does not necessarily indicate pulp necrosis, and it rather indicates damage to the pulpal tissues with consequences regarding prognosis, as an intact vascular supply is responsible for pulp survival. Additional difficulties may occur after repeated injuries, which can influence sensibility testing and the healing capacity of the pulp. Furthermore, neural regeneration progresses at a slower rate compared with vascular regeneration or may even not occur (Schendel *et al.* 1990, Kvinnsland *et al.* 1992), which again conflicts with the nature of sensibility testing.

On the other hand, vitality tests (e.g. laser Doppler flowmetry, ultrasound Doppler flowmetry, pulse oximetry) assess the blood supply of the pulp, thus offering a more objective approach. Whereas vitality

tests have been reported to have superior diagnostic accuracy compared with sensibility tests (Ghouth *et al.* 2018, Balevi 2019, Lima *et al.* 2019), there might be a high level of bias (Ghouth *et al.* 2019), and their complicated clinical application makes the benefits of these tests questionable (Alghaithy & Qualtrough 2017). Another factor that has to be considered when assessing pulpal status after dental trauma is the stage of root development. Immature teeth are not fully innervated and therefore associated with an increased excitation threshold (Fulling & Andreasen 1976), which may result in increased rates of false-negative results, particularly after electric pulp testing (Rock & Grundy 1981, Fuss *et al.* 1986). Colour changes may be concomitant observations in traumatized teeth and may result from pulpal haemorrhage (Andreasen 1986). Pink colour changes that occur shortly after the accident can be reversible. However, if the crown of the tooth turns progressively grey, this may indicate pulp necrosis (Malmgren & Hubel 2012).

All these factors have to be borne in mind when performing sensibility testing of the pulp after dental trauma, and obtaining the correct pulp diagnosis is only possible through combining and assimilating findings from the patients' history, analysis of the injury pattern, and further diagnostics and radiographic assessment, which are all an integral part of the diagnostic process.

Despite the limitations of conventional 2D radiography in visualizing three-dimensional anatomical structures, periapical (PA) radiographs combined with clinical examination remain the standard of care and should always be considered during the initial evaluation of the patient (Bourguignon *et al.* 2020).

Cone-beam computed tomography (CBCT) can provide valuable additional information, but its use should always be balanced against the potential risks (ESE 2019a). On the one hand, cases that appear straightforward on periapical radiographs might present a different and more complex situation when evaluated three-dimensionally (Cohenca & Silberman 2017). At the same time, it should be taken into account, that particularly in children, the tissues are more sensitive to the effects of ionizing radiation (Whitworth 2018) with children below age 10 years having a threefold probability of radiation-induced stochastic effects compared with those over 30 years of age (Horner *et al.* 2004). Thus, CBCTs should be considered in situations in which further imaging is required to obtain an accurate diagnosis and develop

a correct treatment plan and the image is likely to change the management of the injury (Bourguignon *et al.* 2020). This applies particularly to cases of complex dentoalveolar trauma, such as root fractures, where a communication of the fracture lines with the oral cavity appears likely and to complications such as root resorptions (Dula *et al.* 2014, ESE 2019a).

Endodontic management following crown fractures

Enamel cracks

Enamel cracks are the least harmful injuries to teeth. They are described as incomplete fractures of a tooth that remains morphologically intact, but the crack line may extend into the dentine (Ravn 1981a). An exact assessment of the depth of the crack and crack propagation prediction is not feasible (Krstl *et al.* 2011). Although a laboratory study identified enamel/dentine infractions as potential pathways for the invasion of microorganisms (Love 1996), an infection of a healthy pulp leading to necrosis is rather unlikely with a risk that has been reported to be less than 3.5% (Stalhane & Hedegard 1975, Ravn 1981a). However, the risk of pulp necrosis may increase in the presence of an undiagnosed concussion or subluxation of the affected tooth due to a compromised blood supply.

Adhesive sealing of enamel cracks has been reported to be effective in laboratory studies in order to prevent pulp infection (Love 1996). However, there is no clinical evidence whether sealing a crack increases the fracture resistance of the crown or prevents pulp necrosis or discolouration of the crack lines.

Dentine exposure

Most crown fractures expose dentine. In children, up to 70 000 tubules per mm² with a diameter of 2–5 µm that lead to the pulp may be exposed (Ketterl 1961, Garberoglio & Brannstrom 1976). Due to an age-related smaller volume of peritubular dentine, a large percentage of the total cross-sectional area near the pulp consists of the lumina of the dentinal tubules resulting in the fractured dentine being highly permeable (Mjor 2009). Defence mechanisms of the pulp such as the outward flow of dentinal fluid within the tubules and the ability of the pulp to elicit an immediate inflammatory response to external stimuli temporarily impede bacterial invasion and infection of the

pulp tissue (Olsburgh *et al.* 2002). The risk of pulp necrosis is further increased in cases of concomitant luxation injuries (Robertson *et al.* 2000). A definitive adhesive restoration should be placed as soon as possible after the accident. If this is not feasible during the initial emergency treatment, the placement of the restoration can be postponed, if the dentinal wound is sealed properly to prevent pulp infection. Immediate dentine sealing can be carried out using a dentine bonding agent and a layer of flowable composite. Temporary dentine protection with a calcium hydroxide cement or a glass-ionomer cement may be less effective but can be applied if subsequent treatment takes place within the next few days (Krastl *et al.* 2020).

Pulp exposure

When the pulp of a previously intact tooth is traumatically exposed, it can generally be assumed that the pulp is healthy and capable of regeneration. This is particularly true in young patients without pre-existing pulpal damage caused by caries or by earlier dental trauma, given there is no concomitant tooth luxation. Primate models studying the tissue reaction following experimental exposure of pulps to the oral environment demonstrated the presence of inflammatory cells in the pulp at the exposure site. However, during the first hours of exposure the tissue alterations rather reflect the damage resulting from the mechanical trauma with negligible superficial inflammatory changes (Cox *et al.* 1982, Heide & Mjor 1983). After 7 days of exposure, the inflammatory response has been reported to be more pronounced but does not extend more than 2 mm into the pulpal tissue (Cvek *et al.* 1982a). Thus, the conditions for vital pulp treatment (VPT) are favourable at least within the first days after trauma. Independent of the treatment strategy, it is essential that the tooth is isolated with rubber dam and disinfected prior to VPT (ESE 2019b). Furthermore, the usage of sterile instruments and magnification are highly recommended throughout the entire procedure.

Direct pulp capping aims to maintain the vitality of the entire pulp after application of a biomaterial directly onto the exposed tissue (ESE 2019b). Animal studies suggest that direct pulp capping may be successful even if delayed for 24 h (Cox *et al.* 1982, Pitt Ford & Roberts 1991). Nevertheless, direct pulp capping after trauma is usually recommended for small pulp exposures, which are treated shortly after the

injury (Cvek 1978, Krastl & Weiger 2014). Thus, partial pulpotomy is preferable for the majority of cases, particularly if a large area of the pulp is exposed and the treatment cannot be performed within the first few hours after the injury (Damaschke *et al.* 2019a, Krastl *et al.* 2020).

Partial pulpotomy is preferably performed using a small cylindrical diamond bur in a high-speed hand-piece under continuous irrigation and involves removing approximately 2 mm of the coronal pulp. Similar to direct capping, during partial pulpotomy rinsing the pulp wound with sodium hypochlorite (0.5–5%) or chlorhexidine (0.2–2%) is recommended to assist haemostasis and disinfection (ESE 2019b, Munir *et al.* 2020). Cotton wool or sponge pellets soaked in sodium hypochlorite can be applied with gentle pressure. If the remaining pulp is reduced to a healthy level, any bleeding is expected to stop within 5 min. If haemostasis has not occurred within this time frame, the removal of the entire coronal pulp (full pulpotomy) can be considered as the last measure to maintain vitality of the radicular pulp.

Before starting the capping procedure, the operator has to make sure that there is no blood clot on top of the exposed pulp. The selection of the capping material for direct pulp capping and partial pulpotomy primarily depends on its bioactive properties but should also take the risk of crown discoloration into account.

Calcium hydroxide is still commonly used as a pulp-capping material and has been reported to have high success rates (Damaschke *et al.* 2019a) despite its mechanical instability and the dissolution of the material over time (Bakland & Andreasen 2012). Thus, calcium hydroxide is highly dependent on the protection of a good-quality restoration to prevent bacterial invasion of the pulp (Bakland 2009). Hydraulic calcium silicate-based cements (HCSC) overcome the problem of mechanical instability, at the same time they offer excellent biological properties. The drawback of some of these materials is their discoloration potential caused by the included radiopacifiers and by absorption of blood components within the material (Lenherr *et al.* 2012, Krastl *et al.* 2013). Newer formulations of these materials that contain zirconium oxide or tantalum oxide appear more colour stable (Dettwiler *et al.* 2016, Mozynska *et al.* 2017, Lipski *et al.* 2018, Haikal *et al.* 2020).

A large variety of bioactive materials are available on the market, all of them sharing calcium silicate chemistry with desirable biological effects. However,

the use of light-curing liners and cements with calcium hydroxide or MTA additives as pulp-capping agents cannot be recommended at this time due to the paucity of reliable data regarding biocompatibility (Hebling *et al.* 2009, Camilleri *et al.* 2014, Dammaschke *et al.* 2019a). Likewise, dentine adhesives and composite resins are not biocompatible and therefore cannot be recommended as pulp-capping materials (Costa *et al.* 2000, Dammaschke *et al.* 2019a).

After application of a nonstaining hydraulic calcium silicate-based cement or a calcium hydroxide suspension on the exposed pulp, the pulp-capping material must be covered with a thin layer of a hard-setting material, to avoid unintentional removal during the restorative procedures that follow. Subsequently, the exposed dentine should be rinsed thoroughly and cleaned with water to minimize the negative impact of disinfecting solutions on the adhesive bond. The definitive adhesive restoration should ideally be applied during the same visit.

A hard tissue bridge with histological evidence of tubular dentine may form over the healed pulp tissue (Nair *et al.* 2008). However, in most cases, bridge formation after pulp-capping procedures is rather regarded as a repair process due to its unstructured mineralization and lack of native tubular morphology (Damaschke *et al.* 2019b).

In contrast to VPT of cariously exposed pulps where HCSCs clearly outperform calcium hydroxide in terms of clinical success (ESE 2019b), in the treatment of traumatically exposed pulps, the capping material (calcium hydroxide vs. HCSC) does not seem to be a decisive factor (Damaschke *et al.* 2019a). A retrospective study demonstrated a significantly higher success rate when a new-generation HCSCs was used instead of calcium hydroxide; however, the latter still achieved a clinical success rate of 93% (Rao *et al.* 2020). A randomized controlled trial demonstrated a similar pulp survival rate in traumatized immature teeth treated with partial pulpotomy regardless of whether calcium hydroxide or a new-generation HCSC was used as a capping material (Yang *et al.* 2020).

Thus, calcium hydroxide can still be used, but specific nonstaining hydraulic calcium silicate-based cements are the first choice (Parinyaprom *et al.* 2018, Abuelniel *et al.* 2020, Haikal *et al.* 2020).

Survival of the pulp after complicated crown fractures can be achieved in 43–90% with direct pulp capping (Fuks *et al.* 1982, Ravn 1982, Hecova *et al.* 2010, Wang *et al.* 2017) and 86–100% with partial

pulpotomy (Cvek 1978, 1993, Fuks *et al.* 1987, de Blanco 1996, Hecova *et al.* 2010, Wang *et al.* 2017). Given the greater success rates of partial pulpotomy compared with direct pulp capping, the indication for direct pulp capping can be questioned.

Partial pulpotomy after trauma is associated with very high success rates, particularly in immature teeth (90–100%), but also high success rates ranging from 70% to 100% in mature teeth (Cvek 1978, 1993, Fuks *et al.* 1987, de Blanco 1996, Hecova *et al.* 2010, Wang *et al.* 2017). With increasing age of the patient, alterations in terms of a reduced cell density and an increased amount of fibrous tissue may reduce the pulp tissue's regenerative capacity (Murray *et al.* 2002, Goodis *et al.* 2012). Nevertheless, VPT after trauma should not be reserved for children and adolescents only but should be considered for adults as well. However, particularly in teeth with completed root formation, even minor luxation injuries may compromise the nutritional supply to the pulp and therefore substantially affect the success of VPT (Ravn 1981b, Robertson *et al.* 2000, Lauridsen *et al.* 2012a,b,c).

Teeth that have undergone pulp preservation procedures should be periodically monitored to assess the treatment outcome (Jafarzadeh & Abbott 2010).

Endodontic management following root fractures

Intra-alveolar root fractures of permanent teeth with vital pulps result in an injury to the pulp tissues, primarily compromising the neurovascular supply coronal to the fracture line. Maxillary anterior teeth are most often affected in this way. The condition of the pulp following displacement of the coronal tooth fragment can only be estimated at the first clinical examination and continuous monitoring is necessary to make a final diagnosis of the pulpal status.

Previous traumatic events and the age of the patient have been suggested to impact on pulp survival (Andreasen *et al.* 2004a,b). The validity of any sensibility test is limited during the first weeks after the traumatic event. An initially negative response is not a clear indicator that the pulp will not recover. Pulp healing is more likely in immature teeth and in teeth with root fractures with a positive pulp reaction at the time of first examination following the accident (Andreasen & Kahler 2015).

A reddish discolouration of the crown may occur immediately after the injury in some cases as a result

of diffusion of blood components into dentine. This discolouration may either remain or disappear (transient coronal discolouration; Heithersay & Kahler 2013) and is not necessarily a sign of pulp necrosis.

The various root resorption processes that may occur following root fracture are usually related to marked osteoclastic activity during the healing process and do not require endodontic treatment (Andreasen & Andreasen 1988). External surface resorption may lead to a rounding of the fracture edges and may be associated with a widening of the fracture line during the initial phases of fracture healing (Andreasen & Hjorting-Hansen 1967). Internal surface resorption has been described as a circular radiolucent area starting at the intersection of root canal and fracture line due to a rounding of the fracture edges at the pulpal aspect of the fracture (Andreasen & Andreasen 1988). Internal tunnelling resorption likewise begins at the fracture line but burrows behind the predentine layer of the root canal walls. Furthermore, partial to complete obliteration is a common finding on follow-up radiographs taken after some months, affecting almost three quarters of the teeth with root fractures. In the majority of cases, either the apical fragment or both the apical and coronal fragment are affected, but rarely the coronal fragment alone (Andreasen & Andreasen 1988). In almost 80% of treated teeth with intra-alveolar fractures (below the alveolar bone crest level), favourable healing with either hard tissue fusion of the fragments (30%) or interposition of soft tissues (with or without bone formation) in-between the fragments (48%) has been demonstrated (Andreasen *et al.* 2004a). Surprisingly, in intra-alveolar cervical fractures the chance of pulp healing is greater compared with fractures located at the middle or apical third of the root. This might be explained by the larger fracture foramen (the diameter of the root canal where the fracture line is crossing) in the coronal fragment and the shorter distance needed to be revascularized in the cervical region (Andreasen *et al.* 2004a). Nevertheless, even if healing occurs initially, the prognosis of teeth with cervical root fractures is poor because the highly mobile coronal fragment is prone to further traumatic displacement (Andreasen *et al.* 2012). Orthodontic retainers may stabilize the tooth and increase its longevity (Tobiska & Krastl 2018), but clinical evidence is missing. However, if there is an initially undiagnosed communication of the fracture line to the oral environment via the gingival sulcus, the extraction of the coronal fragment is

inevitable (Andreasen *et al.* 2012). Preservation of the root and subsequent restorative treatment may still be possible following surgical extrusion (Kahnberg 1996). Apart from the fracture location, the extent of dislocation of the coronal fragment (i.e. displacement in any direction) and tooth mobility are positively associated with the risk of later pulp necrosis (Andreasen *et al.* 2004a).

Clinical signs indicating a loss of pulp vitality appear within the first 3–6 months, in some cases even later. The lack of a response to pulp sensibility testing is not conclusive for pulp necrosis (Bourguignon *et al.* 2020). Thus, at least two symptoms, such as recurrent negative response to vitality tests and a grey discoloration of the crown, should be present for a reliable clarification of the tentative diagnosis (Jacobsen 1980). Pulp necrosis followed by endodontic infection of the coronal fragment and inflammatory changes between fragments was detected in 22% of cases (Andreasen *et al.* 2004a). In these cases, a lateral lesion at the level of the fracture line is detected radiographically as a result of an infection of the coronal root canal system (Andreasen & Hjorting-Hansen 1967). This lesion can often be diagnosed within the first year, which underlines the necessity of regular follow-ups. In immature teeth, arrested root development is a typical sign of pulp deterioration. The pulp tissue apical to the root fracture most often remains unaffected and vital in nearly all cases (Cvek *et al.* 2008). By contrast, signs of early pulpal calcification can often be seen on follow-up radiographs, which may be interpreted as a reaction of a vital apical pulp to the injury.

Root canal treatment, if necessary, should be limited to the coronal segment and follow the common guidelines. Due to the large size of the canal at the fracture site in the coronal fragment, 'working length' determination, cleaning and shaping as well as canal filling may be challenging, and it is recommended to use suitable strategies, similar to the treatment of immature teeth. In the rare cases that present with a lesion around the apical fragment, a combined treatment approach with root canal treatment of the coronal segment as outlined above and subsequent surgical removal of the apical fragment is the therapy of choice. Shaping and filling both the coronal and the apical root canal by penetrating the tissue present in the fracture are unreliable and cannot be recommended.

The prognosis of teeth with intra-alveolar fractures following root canal treatment is favourable. Tooth

survival has been reported to average 72% (fracture mid-root) or 67% (fracture apical), respectively, within an observation time of 8 years (Andreasen *et al.* 2012). The overall survival rate of teeth with root fractures including endodontically treated teeth has been reported to approach 88% when teeth with cervical fractures are excluded as these teeth are often extracted due to an excessive mobility and a decreased resistance of the coronal fragment to a new impact (Cvek *et al.* 2008). There are only scarce data on pulp survival within the coronal fragment for concomitant crown fractures with exposed pulp. Cvek *et al.* (2004) described five teeth with root fractures whose pulps survived following partial pulpotomy. Endodontic therapies aiming at revascularization or revitalization of the diseased coronal pulp tissue in such teeth have not been subject of clinical investigations or case presentations so far.

Endodontic management following luxation injuries

Through mechanical trauma following luxation injuries, the pulp can be subjected to tension, compression or separation at the apical constriction. In less severe cases, the trauma at least causes bleeding or increased intrapulpal pressure, reduced circulation and transient loss of sensibility. Depending on several factors, pulp survival or repair (revascularization) is possible. For the clinician, it is important to understand these factors because – apart from sophisticated methods for pulp testing (see above) the vitality status of the pulp can be diagnosed only indirectly.

The main parameters influencing the development of pulp necrosis after acute trauma are the type and severity of luxation injury as well as the width of the apical foramen. Accordingly, concussion, subluxation, extrusion and lateral luxation are associated with different proportions of initial necrosis and subsequent healing that occur in the pulp (Andreasen & Vestergaard-Pedersen 1985; Table 1). It is therefore important to classify the injury accurately as soon as possible and document precisely. Otherwise, valuable information on the indications for endodontic treatment is lost. Systematic examination techniques including standardized examination charts, film holders, centric and eccentric radiographs and informative photographs are necessary not only for the initial diagnosis but also for forensic reasons in order to prove that particular complications originate from the traumatic incident (Andreasen & Andreasen 1985).

Nevertheless, loss of information on the extent and direction of tooth displacement may occur due to self-treatment or first aid given by laypeople. Increasingly, so-called 'selfie' photographs provide additional valuable information for the clinician (de Almeida Geraldino *et al.* 2017).

The width of the apical foramen plays an important role in traumatic tooth dislocation. The smaller it is, the more likely the pulp is disrupted and the less likely it is repaired by revascularization (Andreasen *et al.* 1986, Andreasen & Kahler 2015). A diameter of less than 1 mm has been described as critical (Kling *et al.* 1986) but does not necessarily exclude revascularization. Even for extruded and laterally luxated teeth, an apical diameter ranging between 0.1 and 1 mm can still lead to pulp survival in 39% and 22% of the cases, respectively (Andreasen *et al.* 1986).

Two corresponding situations follow the same principle: (i) in root fractures the fracture foramen plays the same role as the apical constriction, which means that the coronal part of the pulp is more likely to survive in cervical than in apical fractures and again is more likely to be repaired after traumatic necrosis (Andreasen 1989); and (ii) teeth involved in or after orthodontic movement are often associated with apical root resorption (Tieu *et al.* 2014), which means that the apical constriction is lost and the apical entrance for vessels is enlarged, resulting in a greater probability of successful revascularization.

An additional important aspect in the endodontic management of luxated teeth is the minimization of additional trauma resulting from the treatment. From the perspective of the pulp, repositioning of displaced teeth is an additional traumatic event; thus, spontaneous or orthodontic repositioning might appear preferable (Andreasen & Andreasen 2007). However, surgical or manual repositioning is often necessary for periodontal reasons, particularly in more severe luxations or in cases of occlusal interference. Rigid splints have been found to impair pulpal repair (Kristerson & Andreasen 1983) and are therefore not recommended from an endodontic perspective.

Infection is a great threat to the traumatized pulp. Therefore, local bacterial growth should be minimized. Before treatment is initiated, visible biofilms and local calculus should be removed from teeth and gingiva and a thorough disinfection by mouth rinse (chlorhexidine 0.1–0.2%) is recommended (Levin *et al.* 2020). Additional crown fractures with exposed dentinal tubules are a negative cofactor in the healing

Table 1 Post-traumatic healing of the pulp depending on the stage of root formation and type of tooth dislocation (Andreasen & Vestergaard-Pedersen 1985)

Type of injury	Open apex			Closed apex		
	Vital (%)	PCO (%)	Necrosis (%)	Vital (%)	PCO (%)	Necrosis (%)
Concussion	97	3	0	90	6	4
Subluxation	88	12	0	75	9	16
Extrusion	30	62	8	17	18	65
Lateral luxation	19	70	11	12	9	79

PCO, pulp canal obliteration.

of a traumatized pulp (Lauridsen *et al.* 2012a,b,c). Dentinal fluid from a healthy pulp flows out of the open tubules at the fracture site. However, if the blood circulation is reduced or lost, necrotic tissue dissolution generates negative osmotic pressure inside the pulp chamber resulting in an inflow of saliva (and bacteria) into the tubules (Stenvik *et al.* 1972, Andreasen 1995). Thus, the necrotic pulp tissue becomes infected and healing is impossible. The younger the patient, the larger is the diameter of the dentinal tubules, which means the pulp is more prone to infection. Other sources of infection are open dentine tubules in the cervical region or an infected blood clot in the socket (Cvek *et al.* 1990b). Apart from their undoubted benefit, fixed splints have to be seen as plaque accumulators. Therefore, similar to orthodontic treatment, appropriate oral hygiene instructions should be given including the recommendation of an antiseptic mouth rinse.

One more critical aspect in the endodontic management of luxated teeth is the prevention of overtreatment. Results of pulp sensitivity testing may not be consistent with the histological state of the pulp (Bhaskar & Rappaport 1973). Especially, a negative result obtained with any method does not necessarily indicate infected pulp necrosis. Pulp repair may occur in immature teeth, with a return of sensibility within weeks to months (Andreasen 1970, Andreasen & Vestergaard-Pedersen 1985, Andreasen *et al.* 1986, Andreasen 1989, Bourguignon *et al.* 2020).

Several radiographic signs indicate pulpal healing. Transient apical breakdown is a rare finding (4, 2%) in which a transient apical radiolucency occurs and resolves within months to years, partially together with a gradually vanishing grey discolouration (Andreasen *et al.* 1986). Pulp canal obliteration (PCO) indicates the re-establishment of the vascular supply of the pulp (Andreasen *et al.* 1987, McCabe & Dummer 2012, Bastos & Cortes 2018).

During the follow-up visits, a number of signs indicate infected pulp necrosis; however, due to the ischaemic mechanism of pulp necrosis in luxation injuries, most patients do not have pain or swelling. Tenderness to percussion is found only in teeth with acute periapical inflammation. The presence of two of the three main signs (discolouration, negative sensibility and increasing periapical radiolucency) justifies endodontic intervention (Jacobsen 1980, Andreasen & Andreasen 2007). Further clinical signs may include a sinus tract, mucosal swelling, formation of an abscess or persistent mobility. During the first weeks after dentoalveolar trauma, apical bone resorption or incomplete repositioning of the tooth may imitate an apical periodontitis. In immature teeth, arrest of root development indicates infected pulp necrosis. Rapid external infection-related root resorption (EIR) mainly occurs after intrusion and avulsion and is a rather rare finding in the other types of luxation injuries (Andreasen & Vestergaard-Pedersen 1985).

Last but not least, regular follow-ups are needed to ensure the initial pulpal diagnosis was made correctly, especially in cases with PCO and/or negative sensibility. Follow-ups, including clinical and radiographic examination, are recommended at least 2, 4, 6–8 weeks, 3, 6 months, 1 year after trauma and annually for 5 years post-trauma.

In doubt, shorter intervals should be chosen (Bourguignon *et al.* 2020).

Endodontic management following intrusion

Intruded teeth that are displaced axially into the alveolar bone usually elicit a high-pitched metallic percussion sound and are likely to give negative results to pulp sensibility tests (Bourguignon *et al.* 2020). In general, the biological principles influencing the development of pulp necrosis described for luxation

injuries also apply for intrusive luxations. However, intrusion is the most severe type of all luxation injuries, leading to considerable damage to the PDL and the pulp (Kenny *et al.* 2003). Pulp survival is only realistic if the pulp has not become disconnected from the blood supply as a result of the traumatic impact; alternatively, if the pulp becomes necrotic revascularization may occur. Both scenarios may be realistic in immature teeth but are highly unlikely in teeth with completed root formation (Andreasen & Vestergaard-Pedersen 1985, Ebeleseder *et al.* 2000, Medeiros & Mucha 2009, Tsilingaridis *et al.* 2012). In mature teeth, pulp necrosis, followed by root canal infection and apical periodontitis, is to be expected. Additionally, in severe intrusions with considerable mechanical damage to the cementoblast layer on the root surface, external infection-related root resorption (EIR) may be an inevitable consequence (Kenny *et al.* 2003). Thus, from an endodontic perspective, early initiation of root canal treatment is crucial to avoid infection and EIR of mature teeth. In the absence of root canal infection, the severely damaged root surface may still be prone to resorption; however, replacement resorption will emerge instead of EIR. It is beyond the scope of this review to go into further details on the management of teeth with replacement resorption and ankylosis.

Repositioning of the intruded tooth is usually necessary to obtain access to the root canal. There is no clear evidence whether the repositioning strategy (immediate surgical repositioning or orthodontic repositioning) has an influence on the survival of intruded teeth (Andreasen & Vestergaard-Pedersen 1985, Costa *et al.* 2017). Again, from an endodontic standpoint a repositioning method that allows early adequate root canal treatment is preferable.

In immature teeth that are intruded, revascularization may occur in one third of the cases, particularly if the apex is wide open (Andreasen *et al.* 2006). Thus, root canal treatment should not be initiated in these cases. However, these teeth should be monitored carefully in order to detect early signs of pulp necrosis and/or EIR, which may become visible 3 to 6 weeks after the injury (Patel *et al.* 2016).

Endodontic management following avulsion

Avulsion of permanent anterior teeth is one of the most serious dental injuries and makes up 0.5–16% of all dental traumata (Fouad *et al.* 2020).

Replantation is the treatment of choice in such situations. The extraoral storage conditions of the avulsed tooth, the diameter of the apical foramen, the length of the root canal and appropriate manipulation of the tooth influence the prognosis of the injured PDL and the pulp (Kling *et al.* 1986, Andreasen *et al.* 1995a,b,c,d). Avulsion of a tooth inevitably leads to necrosis of the disrupted pulp. In mature teeth (with closed apex), revascularization cannot occur after replantation. Instead, regardless of whether the crown is intact or not, bacteria that contaminated the surface of the root during the extra-alveolar period will enter the necrotic pulp tissue through various pathways including the apical foramen, lateral canals, exposed dentinal tubules or enamel–dentine cracks (Cvek *et al.* 1990a). Thus, infection of the pulp space is believed to be established as early as 2–3 weeks after replantation (Andreasen 1981, Tronstad 1988). There is consensus that in mature teeth, early root canal treatment is mandatory (Fouad *et al.* 2020).

Based on the assumption that calcium hydroxide may impair periodontal healing due to diffusion of hydroxyl ions through dentinal tubules to the root surface (Lengheden 1994, Lengheden & Jansson 1995), it was recommended to schedule the initiation of root canal treatment to 7–10 days after replantation (Andersson *et al.* 2012) in order to await the initial healing processes on the one hand, but to initiate treatment before pulp space infection is established on the other hand. However, the diffusion of calcium hydroxide through the dentinal tubules is limited by the buffering capacity of dentine and the presence of intact root cementum (Nerwich *et al.* 1993), and therefore, a clinically significant change in the pH on the root surface might not occur (Fuss *et al.* 1996). In any case, EIR can be prevented reliably if root canal treatment is initiated within 2 weeks post-replantation (Fouad *et al.* 2020). Depending on the severity of periodontal damage caused during extraoral storage either periodontal healing or tooth ankylosis can be expected (Kenny *et al.* 2003, Lauridsen *et al.* 2019). To increase the survival of teeth and achieve periodontal healing following replantation, immediate placement of alternative intracanal medicaments containing an antibiotic–corticosteroid paste, such as Ledermix (Riemser, Greifswald, Germany), has been proposed (Trope 2011). After experimental avulsion and replantation in an animal trauma models, this treatment approach was reported to promote favourable periodontal healing and reduce

root resorption (Bryson *et al.* 2002, Wong & Sae-Lim 2002). In a randomized controlled trial, a higher proportion of replanted teeth had periodontal healing if treated with Ledermix (8/12 teeth) compared with calcium hydroxide (6/15 teeth). However, there was no significant difference between the medicaments with $P = 0.17$. Ankylosis developed in the failing cases (Day *et al.* 2012).

In contrast to calcium hydroxide, Ledermix may be placed immediately or shortly following replantation (Andersson *et al.* 2012). Its main preventive mechanism against root resorption does not rely on an antibacterial effect, but on the direct inhibition of odontoclasts by detaching the resorbing cells from the root surface (Pierce *et al.* 1988b). Although both the steroid (triamcinolone acetonide) and the tetracycline (demeclocycline hydrochloride) components in Ledermix have antiresorptive properties, a similar effect was demonstrated when triamcinolone was used alone after delayed replantation of teeth (Chen *et al.* 2008). Thus, Odontopaste (ADM, Brisbane, Australia), which uses clindamycin as a substitute for the stain-inducing tetracycline component, but shares the same steroid component, is regarded as a reasonable nonstaining alternative to Ledermix (Dettwiler *et al.* 2016).

In teeth with wide-open apices, the treatment approach is directed towards the re-establishment of a blood supply as these teeth may have the potential to revascularize and continue their root development (Trope 2011). However, natural revascularization should only be considered as an option, if the individual rescue chain (storage conditions of the avulsed tooth) suggests that there is a reasonable chance for periodontal healing (Trope 2011). In a dog model, it was demonstrated that revascularization of the pulp in replanted immature teeth mainly occurs by ingrowth of newly formed blood vessels, which was visualized by microangiography in the entire pulp 30 days post-replantation in most cases (Skoglund *et al.* 1978). The revascularization process is influenced by the size of the apical foramen and particularly by the length of the root and can only occur in the absence of bacteria (Andreasen *et al.* 1995c). The longer the root, the greater is the distance to be revascularized and therefore the greater the chance of infection and the risk of EIR (Andreasen *et al.* 1995c). The likelihood of natural revascularization may exceed 40% under ideal conditions with an apical foramen greater than 2.75 mm and a pulp length less than 17 mm but may drop below 10% in immature

roots with a distance to be revascularized of more than 19.5 mm (Andreasen *et al.* 1995c). Topical treatment of the root surface with doxycycline before replantation has been reported to significantly increase the frequency of complete pulp revascularization by decreasing the frequency of microorganisms in the pulpal lumen (Cvek *et al.* 1990a). In contrast, systemic treatment with doxycycline failed to prevent or eliminate the contamination of the necrotic pulp tissue with microorganisms and therefore had no effect on the frequency of pulp revascularization (Cvek *et al.* 1990b). Nevertheless, the prescription of systemic doxycycline may be justified to promote periodontal healing in avulsed teeth according to the current guidelines (Hinckfuss & Messer 2009, Fouad *et al.* 2020).

In general, after replantation of immature teeth, the risk of EIR should be balanced against the chance of revascularization (Fouad *et al.* 2020). Thus, frequent follow-ups are mandatory for early detection of pulp necrosis and EIR if revascularization is attempted but fails.

Endodontic management of teeth located at the bone fracture line

Early studies indicated that teeth retained in an alveolar bone fracture line may become a nidus of infection or result in nonunion/delayed union of the fracture, and extraction of even teeth with vital pulps was recommended to reduce the chances of osteomyelitis and nonunion of the fracture (Chrcanovic 2014). Currently, treatment options for teeth within the alveolar fracture line vary from extraction to preservation and clinical and radiographic follow-up. The decision to extract or preserve these teeth is a complex process, and each case should be approached individually (Vladimirov & Petrov 2005, Anyanechi & Chukwuneke 2013, Sipahi Calis *et al.* 2017).

The endodontic diagnostics of teeth at the bone fracture line do not differ from the general dental trauma diagnostics and include clinical extra- and intraoral examination, radiological and endodontic examinations. Sensory deficit of the surrounding soft tissues (gingiva, lips, skin) should be recorded (e.g. with a sharp explorer), as it may relate to the negative pulp test results in teeth innervated by the same nerve branch. With contemporary surgical techniques, the incidence of permanent partial or complete loss of soft tissue sensation in the region

supplied by the inferior alveolar nerve is approx. 35% (Scott *et al.* 2014, Tay *et al.* 2015).

Eleven studies with over 2300 patients demonstrate that extracting or leaving the teeth in a fracture line had no significant impact on postoperative complications (Neal *et al.* 1978, de Amaratunga 1987, Ellis 2002, Baykul *et al.* 2004, Ramakrishnan *et al.* 2009, Bobrowski *et al.* 2013, Zanakis *et al.* 2015, McNamara *et al.* 2016, Aulakh *et al.* 2017, Christensen *et al.* 2017, Bang *et al.* 2018). Therefore, extraction of teeth associated with fracture lines should be avoided unless there is an absolute indication for their removal (Kamboozia & Punnia-Moorthy 1993, Vladimirov & Petrov 2005, Ramakrishnan *et al.* 2009, Mangone *et al.* 2011, Bobrowski *et al.* 2013, Chrcanovic 2014, McNamara *et al.* 2016, Aulakh *et al.* 2017, Christensen *et al.* 2017, Bang *et al.* 2018).

If the pulp is vital but exposed, or if the pulp is infected, immediate endodontic treatment (pulp capping, partial or total pulpotomy, or pulpectomy with root canal medication or filling) should be initiated without delay to prevent infection of the bone fracture line. Similarly, loss of pulp vitality during the follow-up or other clinical or radiographic indications of necrosis/pulpal infection should result in root canal treatment.

In the absence of other indications for endodontic treatment, permanent teeth maintained in the line of fracture should be followed up clinically and radiographically for at least 1 year even if the response to pulp vitality tests are negative in order to ensure that any unnecessary endodontic treatment is avoided (Kahnberg & Ridell 1979, Kamboozia & Punnia-Moorthy 1993, Brajdic *et al.* 2011, Chrcanovic 2014, Kumar *et al.* 2014, Aulakh *et al.* 2017, Bang *et al.* 2018). Reports have demonstrated an increase of 23–92% in positive responses to electric pulp testing during 6- to 12-month follow-ups (Kahnberg & Ridell 1979, Brajdic *et al.* 2011, Aulakh *et al.* 2017; Fig. 1), which indicates that an initial negative response should not lead to root canal treatment in the absence of symptoms or other indications for endodontic intervention.

The mean percentage of teeth requiring endodontic treatment during the follow-up in 19 studies was 29% (minimum 0%, maximum 56%; Larsen & Nielsen 1976, Chrcanovic 2014, Kumar *et al.* 2014, Lauridsen *et al.* 2016, Aulakh *et al.* 2017, Marotti *et al.* 2017, Bang *et al.* 2018). The risk of pulp necrosis or infection-related resorption between 1 and 2 years after treatment increases by only approximately 4%

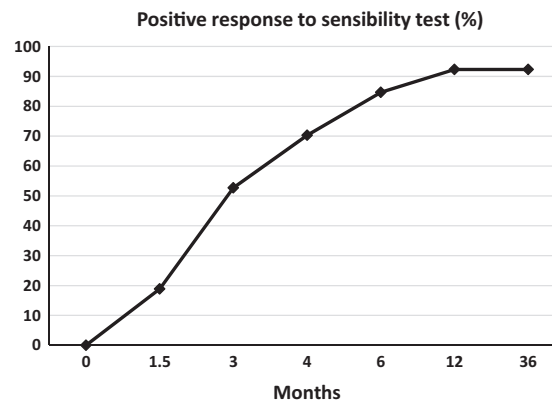


Figure 1 The rate of positive response to electric pulp testing over time of teeth with an initial negative response (adapted from Brajdic *et al.* 2011).

(Marotti *et al.* 2017; Fig. 2a). However, the 5-year estimated risk of marginal bone loss may be about twofold and for ankylosis over sixfold (Marotti *et al.* 2017), so periodical follow-up, for example during normal dental check-ups, is recommended.

If there is direct or indirect trauma to a tooth in a bone fracture line, such as fractures, luxation or intrusion, the prognosis of the tooth is dictated by the dental trauma rather than the alveolar bone fracture itself. In one study, 5.3% of teeth were lost during the follow-up, all with concomitant injuries (avulsion, root fracture or luxation; Marotti *et al.* 2017). If dental trauma is not present, the prognosis of remaining or returning pulp vitality is between 44% and 74% (Larsen & Nielsen 1976, Kahnberg & Ridell 1979, Oikarinen *et al.* 1990, Lauridsen *et al.* 2016, Aulakh *et al.* 2017, Marotti *et al.* 2017). In one study, a 92% return of vitality was reported (Brajdic *et al.* 2011). However, pulp necrosis is the most common complication (up to 62%) in teeth in an alveolar bone fracture line (Fig. 2a) and may depend on the location of the fracture in relation to the root apex (Fig. 2b; Lauridsen *et al.* 2016, Aulakh *et al.* 2017, Marotti *et al.* 2017). Concomitant injury, mature root development, age (over 30 years) and to a lesser extent the position of the fracture in relation to the root apex, incomplete fracture repositioning, mobility of the fragments after surgery and wider (>2 mm) horizontal fracture displacement increase the risk of pulp necrosis significantly (Chrcanovic 2014, Lauridsen *et al.* 2016, Marotti *et al.* 2017). Other potential complications are infection-related resorption (2.5–7.2%), ankylosis-related resorption (2.1–33%), marginal bone loss (2.4–

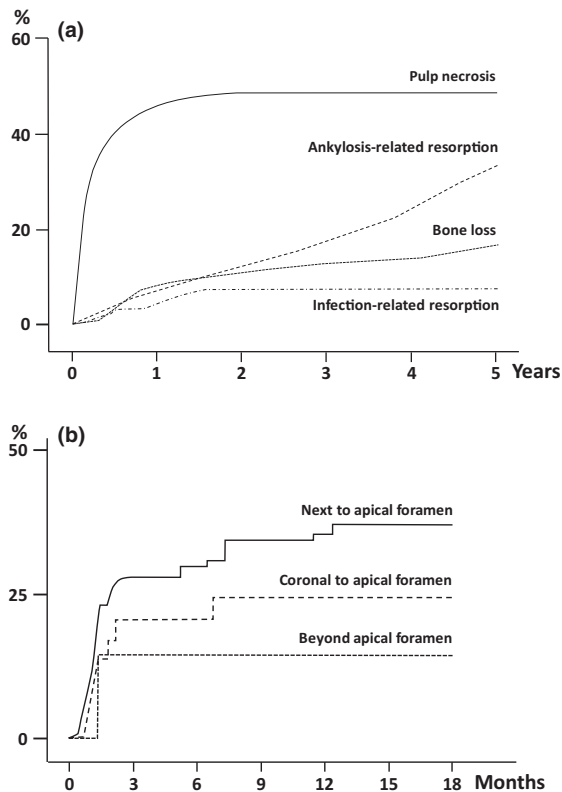


Figure 2 Complications for teeth involved in alveolar bone fracture. (a) The risk of complications for all teeth involved in alveolar bone fracture (adapted from Marotti *et al.* 2017). (b) The risk of pulp necrosis in mature tooth in relation to the location of the horizontal fracture line with complete repositioning (adapted from Lauridsen *et al.* 2016).

16.7%) and tooth loss (4–7.8%; estimated 5- or 10-year risk) and are much more common in mature than in immature teeth (Lauridsen *et al.* 2016, Marotti *et al.* 2017; Fig. 2a). PCO is also a frequent finding (28–79%; Lauridsen *et al.* 2016, Marotti *et al.* 2017). The development of tooth buds in the fracture line is not predictable (Koenig *et al.* 1994, Swei *et al.* 2006, Yamamoto *et al.* 2010), but preservation of tooth buds in the fracture line is recommended except in cases of infection (Swei *et al.* 2006, Chrcanovic 2014). Normal tooth eruption is common (82%; Koenig *et al.* 1994), but approximately half of the affected permanent teeth may develop morphological abnormalities (deficient root formation, abnormal bend of the root) or other complications (obliteration, external resorption; Swei *et al.* 2006) that need to be taken into consideration if endodontic treatment is indicated subsequently.

Endodontic management in cases of external infection-related resorption (EIR)

Infection-related root resorptions (also referred to as inflammatory root resorptions) typically occur after severe luxation injuries (mainly avulsions and intrusion) and are initiated by a combination of severe damage to the protective cementum layer on the root surface and pulp space infection, which is facilitated by the missing (avulsion) or considerably damaged (intrusion) neurovascular supply of the pulp tissue. Even if the crown is intact, bacteria may enter a necrotic pulp through exposed dentinal tubules or enamel–dentine cracks as early as 2–3 weeks after trauma (Andreasen 1981, Tronstad 1988). Once the pulpal infection is established, external root resorption is maintained by microorganisms and their toxins, which enter the inflammatory process in the PDL via opened dentinal tubules (Trope 2002).

Apart from the lack of response to pulp tests, teeth with EIR usually do not have any clinical signs of disease, and therefore, EIR is most often diagnosed only radiographically. Affected teeth are characterized by bowl-shaped radiolucencies along the root surface and corresponding defects in the adjacent alveolar bone. Numerous studies have reported the limitations of 2D radiography and demonstrated that CBCT is more accurate in detecting EIR, particularly in its early stages (Patel *et al.* 2015). Nonetheless, a CBCT examination cannot be recommended for routine monitoring of teeth at risk of root resorption, particularly in children, whose tissues are especially sensitive to the effects of ionizing radiation (Whitworth 2018). A recent study has shown that selected biomarkers such as IL-1 α in the gingival sulcus fluid may be suitable biological markers of the EIR in future (Gregorczyk-Maga *et al.* 2019). However, more evidence is needed to evaluate whether this approach could be beneficial for detecting EIR at its early stage and for reducing radiological exposure in children.

After being asymptomatic for the first weeks, teeth with EIR may at later stages present with increased mobility, dull percussion sound, sensitivity to percussion or a sinus tract at later stages.

In teeth with closed apices at risk of root resorption due to severe luxation injuries, EIR can be reliably prevented by timely initiation of root canal treatment within the first 2 weeks after trauma. Unfortunately, due to inadequate endodontic management, EIR is a frequently encountered sequel in clinical practice

(Andreasen *et al.* 1995d). Moreover, in teeth with open apices, a treatment approach intended to induce natural revascularization and promote further root formation is usually adopted. If revascularization fails in these cases, EIR can cause complete root destruction within a few months (Tronstad 1988, Trope 2002). Therefore, early detection of EIR is crucial because tooth preservation is unpredictable if large parts of the root are already affected.

In teeth at high risk of EIR, the first follow-up radiographs should be performed 4 and 6 weeks after trauma to identify the first radiologic signs (small radiolucencies along the external root surface of the dentine and adjacent bone), which may be already visible at these time-points (Patel *et al.* 2016). Standardization of these radiographs facilitates the early identification of EIR. To arrest EIR, the elimination of the microorganisms from the root canal system is crucial and involves thorough canal debridement and irrigation with sodium hypochlorite. The activation of the irrigant promotes the removal of pulp tissue remnants and hard tissue debris (Caputa *et al.* 2019, Swimberghe *et al.* 2019) and is therefore highly recommended. Smear layer removal with chelators such as EDTA is beneficial to facilitate the diffusion of intracanal medicaments through dentine to the external root surface (Tronstad *et al.* 1981, Heithersay 2007). The standard approach for root canal medication is placement of a calcium hydroxide dressing. It has been demonstrated that calcium hydroxide diffusing through the dentinal tubules significantly increased the pH in resorption areas, where cementum was not present (Tronstad *et al.* 1981). Thus, besides the antibacterial and endotoxin-neutralizing effect in the root canal, calcium hydroxide has the potential to favourably influence the local environment at the resorption sites through inactivation of acids and collagenases, which are released from the clastic cells. Furthermore, root surface repair might be promoted through stimulation of alkaline phosphatases by the alkaline pH at the resorption sites (Tronstad 1988). However, evidence supporting this widespread assumption is missing. An animal study demonstrated that long-term intracanal medication with calcium hydroxide for 3 months was more effective than short-term application for 1 week for the treatment of established EIR (Trope *et al.* 1995). Clinically, high success rates in terms of healing or arrest of the resorption have been demonstrated following medication with calcium hydroxide from 3 to 54 months (mean value for immature teeth was

24 months and for the mature ones 11 months; Cvek 1992). However, there is no consensus on whether long-term calcium hydroxide dressing up to the point when there is radiographic evidence of resorption control is needed in cases of established EIR (Patel *et al.* 2016, Whitworth 2018). The recommendations for the duration of calcium hydroxide medication vary between 4 weeks (Darcey & Qualtrough 2013) and several months (Trope 2002). An alternative approach for treating established EIR involves the use of antibiotic–corticosteroid combinations such as Ledermix (Riemser, Greifswald, Germany) or Odontopaste (Australian Dental Manufacturing, Brisbane, Australia) for eliminating the inflammatory reaction in the periodontal membrane (Pierce & Lindskog 1987, Heithersay 2007). Likewise, an animal study suggested the intracanal use of calcitonin as an adjunct in the treatment of EIR (Pierce *et al.* 1988a). However, there is no evidence of whether the use of antiresorptive corticosteroid or hormone dressings in the root canal (possibly followed by calcium hydroxide) increase success rates compared with the use of calcium hydroxide alone.

Several case reports have used regenerative endodontic procedures for treating teeth with EIR (Chaniotis 2015, Santiago *et al.* 2015, Saoud *et al.* 2016, Tzanetakis 2018, Yoshpe *et al.* 2020); however, there is insufficient evidence to support this approach for routine clinical practice in such cases.

After successful arrest of EIR, depending on the degree of trauma induced PDL damage, periodontal healing may occur, or the process may develop into ankylosis.

Endodontic management of teeth with pulp canal obliteration

Pulp canal obliteration (PCO) is described as a gradual narrowing of the pulp space due to accelerated deposition of hard tissue along the root canal walls and is encountered in 15% of teeth following luxation injuries (Andreasen *et al.* 1987). The exact mechanism of the calcification process is not fully known, but usually starts with the impairment of the neurovascular supply when the pulp is submitted to mechanical stress (Caviedes-Bucheli *et al.* 2017). The occurrence of PCO is dependent upon the type of luxation injury and upon the stage of root formation (Clark & Levin 2018, 2019). PCO is detected particularly in immature teeth with moderate injuries such as lateral luxations (71%) or extrusions (61%;

Andreasen *et al.* 1987). PCO is likely to be detected radiographically after 1 year of observation (Andreasen *et al.* 1987). The process usually starts in the coronal portion of the root canal and is followed by gradual narrowing of the pulp space. Nonetheless, as long as there are no clinical symptoms indicating an irreversible pulpitis and there is no radiological evidence for apical periodontitis, PCO should be considered as a sign of a vital pulp and therefore root canal treatment is not indicated (Patterson & Mitchell 1965, Holcomb & Gregory 1967, Smith 1982, McCabe & Dummer 2012).

Within the first years after PCO, apical pathosis is very unlikely. However, the development of pulp necrosis and periapical changes may occur as a late complication after several uneventful years (Jacobsen & Kerekes 1977). This complication was reported in 7–27% of the cases and seems to increase with longer observation periods (Holcomb & Gregory 1967, Jacobsen & Kerekes 1977, Andreasen *et al.* 1987, Robertson *et al.* 1996, Oginni *et al.* 2009). In these cases, root canal treatment is indicated (ESE 2006). The preparation of the access cavity and identification of the remaining root canal orifice can be challenging. Literature dealing with this clinically important topic is rather scarce. In their study, Cvek *et al.* (1982b) performed root canal treatment in 54 teeth with partial PCO and reported technical failures such as perforations or unsuccessful canal negotiations in more than 15% of the treated maxillary incisors and 70% of the mandibular incisors. These technical failures also had a substantial impact on the success rate. Whilst teeth without technical failures had healing in 88% after 4 years, the rate decreased to only 50% in teeth with technical failures (Cvek *et al.* 1982b).

Another study from the 1980s reported that the success rate of root canal treated teeth with PCO depends on the preoperative periapical status. Whilst teeth with a healthy periapical status had a success rate of 97.9%, teeth with a preoperative lesion healed only in 62.5% of cases (Akerblom & Hasselgren 1988).

Currently, with advanced education in endodontics and enhanced operative protocols, PCO does not create an obstacle that modern endodontics cannot overcome if indicated. Kiefner *et al.* (2017) treated 41 teeth with 114 obliterated root canals of elderly people. In contrast to the two studies from the 1980s, treatment was performed by a specialist endodontist with the best available technologies such as an operating microscope, ultrasonic tips and flexible

machine-driven nickel–titanium files. Although chair time until successful root canal negotiation took up to 60 min per tooth, all root canals were accessible. Full working length, indicated by an electronic apex locator, was established in 90% of the cases and the success rate after 3 years was 80% (Kiefner *et al.* 2017).

An alternative treatment approach using computer-guided access cavities ('Guided Endodontics') has been introduced (Buchgreitz *et al.* 2016, Krastl *et al.* 2016, Zehnder *et al.* 2016). Analogous to guided implantology procedures, data from cone-beam computed tomography and intraoral surface scans are aligned followed by the virtual planning of an ideal access cavity. A printed or milled template, usually with an incorporated metal sleeve, guides the bur to the orifice of the calcified root canal. *Ex vivo* studies have reported that this technique is accurate, rapid and operator-independent (Buchgreitz *et al.* 2016, Zehnder *et al.* 2016, Connert *et al.* 2017) and leads to less tooth substance loss compared with conventional unguided access cavity preparation, at least in 3D printed teeth (Connert *et al.* 2019). Several case reports document successful root canal localization in calcified maxillary and mandibular anterior teeth, which was confirmed by a clinical study with 50 patients (Buchgreitz *et al.* 2019). In summary, root canal treatment of teeth with PCO and apical periodontitis is feasible and has favourable success rates, when performed by a specialist and/or with the help of Guided Endodontics.

Endodontic treatment of immature teeth with nonvital pulps

Treatment of young permanent teeth with pulpal involvement represents both an endodontic and a restorative challenge. If pulp vitality is lost, the formation of dentine stops, resulting in a tooth with thin dentine walls that are prone to fracture. Mechanical removal of root dentine from the thin root canal walls during instrumentation should be limited to a minimum. Instead, the focus lies on copious irrigation using sodium hypochlorite to remove necrotic pulp tissue and disinfect the root canal (Trope 2006). Despite existing concerns that the irrigants may be extruded beyond the terminus into the apical tissue, the use of sodium hypochlorite appears safe up to a concentration of 5% as long as an adequate technique (type of cannula, penetration depth, pressure) is applied (Boutsioukis *et al.* 2007, 2010). Activation of sodium hypochlorite, for example by ultrasound to

improve the cleansing effect, is an important part of the disinfecting protocol in these cases even though evidence is limited to teeth with closed apices (Caputa *et al.* 2019). Root canal length is best determined by means of modern electronic apex locators, which provide sufficiently accurate measurements (ElAyouti *et al.* 2005).

Traditionally, apexification procedures were performed with calcium hydroxide, with the purpose of inducing an apical hard tissue barrier to produce more favourable conditions for the application of a conventional root canal filling (Frank 1966). Successful outcomes of calcium hydroxide apexification have been reported (Cvek 1972, 1992, El-Meligy & Avery 2006, Pradhan *et al.* 2006). Despite a long history of use in apical closure procedures, there are several drawbacks relating to the use of calcium hydroxide for apexification. These include the extended time required for open root apices to close, the need for multiple appointments and the risk of reinfection and cervical root fracture (Cvek 1992, Rafter 2005). In addition, several laboratory studies reported a reduction in the mechanical properties of radicular dentine after exposure to calcium hydroxide for 5 weeks or longer (Yassen & Platt 2013).

Hydraulic calcium silicate cements (HCSCs) such as MTA have been widely used as an apical barrier material in immature teeth with nonvital pulps. As an alternative to calcium hydroxide apexification (Parirokh & Torabinejad 2009, Bonte *et al.* 2015), this has been reported to be a successful and predictable procedure (Simon *et al.* 2007, Witherspoon *et al.* 2008, Mente *et al.* 2009, Moore *et al.* 2011, Pace *et al.* 2014, Bonte *et al.* 2015, Bucher *et al.* 2016), in either one (Simon *et al.* 2007, Witherspoon *et al.* 2008) or two treatment sessions (Witherspoon *et al.* 2008, Moore *et al.* 2011). Several case series and prospective studies with MTA plugs reported high success rates at 1- and 2-year follow-ups (Simon *et al.* 2007, Witherspoon *et al.* 2008, Moore *et al.* 2011, Bonte *et al.* 2015). A 10-year case series of 17 patients with immature teeth with nonvital pulps reported that the apical plug technique was successful and effective for the long-term management of this group of teeth (Pace *et al.* 2014).

In the majority of outcome studies of the apical MTA barrier technique, there is no information on the restorative follow-up treatment of these immature teeth. There is substantial evidence that the post-endodontic restorative treatment can enhance the fracture resistance of thin-walled and weak teeth.

Adhesively bonded composite resin restorations extended into the root canal space have been reported to enhance the strength of immature teeth (Desai & Chandler 2009, Seghi *et al.* 2013). However, there is limited evidence on the additional benefit of a bonded root canal post in immature teeth with only minor loss of coronal tooth structure. Some laboratory studies reported that the use of fibre posts improved the fracture resistance of immature teeth significantly more than composite resin alone (Schmoldt *et al.* 2011, Brito-Junior *et al.* 2014, Nikhil *et al.* 2015), whilst others could not demonstrate an additional effect (Carvalho *et al.* 2005, Seto *et al.* 2013). Backfilling the remaining part of the root canal with gutta-percha and sealer resulted in the weakest roots (Schmoldt *et al.* 2011, Brito-Junior *et al.* 2014, Nikhil *et al.* 2015). Clinical studies demonstrated that highly favourable long-term results can be obtained if the adhesive restoration of immature teeth treated with apical plugs is extended into the root canal to reinforce the thin roots, particularly in the cervical region (Pace *et al.* 2014, Ree & Schwartz 2017). In a case series on the long-term success of immature teeth with nonvital pulps treated with an apical MTA plug and an adhesive restoration, the endodontic and restorative treatment was carried out by a specialist endodontist (Ree & Schwartz 2017). In the majority of cases, one or more fibre posts were placed in the root canal. Out of 83 teeth, 69 were available for follow-up after 5–15 years (recall rate 83%). A success rate of 96% was reported, and no teeth were lost due to a root fracture.

Revitalization of traumatized immature teeth

An alternative treatment to the apical barrier technique with MTA plug is revitalization. Based on the observation that tissue ingrowth and 'revascularization' may occur in teeth with open apices after avulsion and replantation (Skoglund *et al.* 1978, Andreasen *et al.* 1995c), a novel treatment modality was explored in immature teeth with pulp necrosis almost two decades ago, which was initially also termed 'revascularization' (Iwaya *et al.* 2001, Banchs & Trope 2004). In the cases that were described, initiation of bleeding into the disinfected root canal led to a continuation and eventually the completion of root formation. As more case reports and case series were published, expectations were raised that true pulpal regeneration can be achieved with this protocol, and the term 'regenerative

endodontic procedures' was coined (Bose *et al.* 2009). Continued research in this new field has shown that the blood clot inside the root canal can serve as a starting point for healing and repair, but that a formation of fibrous connective or mineralized tissue inside the canal is much more likely than regeneration of pulpal tissue with functional odontoblasts producing tubular dentine (Wang *et al.* 2010, Andreasen & Bakland 2011, Lin *et al.* 2014, Meschi *et al.* 2016). However, revitalization offers benefits for the patient: the procedure is less invasive and more biology-based, as healing can occur, and the root canal may be filled with a biological and immunocompetent tissue rather than a synthetic material. In addition to the biological benefits, apposition of hard tissue and promotion of root growth may elicit considerable mechanical advantages for revitalized teeth (Zhou *et al.* 2017, Bucchi *et al.* 2019).

Research and clinical experience have led to the publication of treatment protocols from regional Endodontic Societies such as the European Society of Endodontology (ESE 2016) and the American Association of Endodontists (American Association of Endodontists 2018).

The indication for revitalization includes teeth with incomplete root formation after pulp necrosis, with or without existing periapical lesions. The clinical procedure involves the following:

1. thorough disinfection of the root canal by irrigation with sodium hypochlorite without instrumentation of the dentine walls,
2. subsequent use of EDTA to reduce the toxicity of sodium hypochlorite and to release growth factors from the dentine surface,
3. the use of calcium hydroxide as an intracanal medicament instead of previously advocated antibiotic pastes,
4. induction of bleeding into the root canal with an endodontic file,
5. coverage of the blood clot with a hydraulic calcium silicate cement followed by
6. a tight composite seal (for further information see ESE 2016).

Follow-up at regular intervals that include clinical and radiographic assessment is important. Failure after a revitalization procedure is most likely due to insufficient disinfection or recolonization of the root canal by oral microorganisms (Almutairi *et al.* 2019). Treatment options in that case include a further attempt at revitalization (Chaniotis 2017) or MTA apexification. It remains controversial whether the MTA barrier technique or revitalization provides more favourable

results. In terms of treatment outcome, it appears that both protocols generate similar success rates (Kahler *et al.* 2017). Currently, adverse events such as discoloration or the necessity to change the treatment option may be more likely after revitalization, but further root maturation may occur, even though the results regarding root lengthening and thickening are variable and not predictable (Kahler *et al.* 2017). Another concern is that a potential increase in root thickness is usually limited to apical and mid-root areas, but not the cervical area, which is the region most susceptible to root fracture. The treatment modality appears to be beneficial, especially in teeth at earlier stages of root development (Kim *et al.* 2018). Revitalization has become a part of the endodontic treatment spectrum that should be considered as an alternative to MTA apexification on an individual basis.

Of all incidents preceding revitalization treatment, dental trauma has been reported to be the most frequent aetiology with 62% of all cases (Torabinejad *et al.* 2017). Greater mechanical stress during traumatic impact or inaccurate repositioning of teeth can damage important apical tissues such as Hertwig's epithelial root sheath (HERS) and the apical papilla. Irreversible damage to HERS may affect root lengthening and apex formation and may compromise the success of revitalization procedures (Tong *et al.* 2017). A systematic analysis of all revitalization failures in the literature revealed that failed treatment is associated with dental trauma in 59% of all cases followed by tooth anomalies in only 30%, and dental caries played a negligible role (Almutairi *et al.* 2019). Furthermore, a prospective randomized clinical trial reported on a direct comparison, where revitalization procedures in teeth with necrotic pulps were less successful after traumatic injuries compared to tooth anomalies with success rates of 71.4% versus 97.9%, respectively (Lin *et al.* 2017). Whereas the type of injury causing pulp necrosis was not specified in some of the published revitalization cases, it can be assumed that the risk of irreversible damage to HERS correlates with the type and severity of the trauma. Analogous to root resorptions, intrusive luxation might pose the greatest risk of failure followed by lateral luxation and extrusive luxation.

Conclusion

The pulp plays a central role in the management of traumatized teeth and significantly influences their longevity, particularly in severe cases.

Funding statement

Open Access funding enabled and organized by Projekt DEAL.

Conflict of interest

The authors have stated explicitly that there are no conflicts of interest in connection with this article.

References

- Abuelniel GM, Duggal MS, Kabel N (2020) A comparison of MTA and Biodentine as medicaments for pulpotomy in traumatized anterior immature permanent teeth: a randomized clinical trial. *Dental Traumatology* **36**, 400–10.
- Akerblom A, Hasselgren G (1988) The prognosis for endodontic treatment of obliterated root canals. *Journal of Endodontics* **14**, 565–7.
- Alghaithy RA, Qualtrough AJ (2017) Pulp sensibility and vitality tests for diagnosing pulpal health in permanent teeth: a critical review. *International Endodontic Journal* **50**, 135–42.
- Almutairi W, Yassen GH, Aminoshariae A, Williams KA, Mickel A (2019) Regenerative endodontics: a systematic analysis of the failed cases. *Journal of Endodontics* **45**, 567–77.
- de Amaratunga NA (1987) The effect of teeth in the line of mandibular fractures on healing. *Journal of Oral and Maxillofacial Surgery* **45**, 312–4.
- American Association of Endodontists (2018) *Clinical considerations for a Regenerative Procedure*. Available at: www.aae.org/regenerativeendo/. Accessed May 1st, 2019.
- Andersson L, Andreasen JO, Day P et al. (2012) International Association of Dental Traumatology guidelines for the management of traumatic dental injuries: 2. Avulsion of permanent teeth. *Dental Traumatology* **28**, 88–96.
- Andreasen FM (1986) Transient apical breakdown and its relation to color and sensibility changes after luxation injuries to teeth. *Endodontics and Dental Traumatology* **2**, 9–19.
- Andreasen FM (1989) Pulpal healing after luxation injuries and root fracture in the permanent dentition. *Endodontics and Dental Traumatology* **5**, 111–31.
- Andreasen FM (1995) *Pulpal Healing After Tooth Luxation and Root Fractures in the Permanent Dentition*. Copenhagen: Weiss Bogtrykkeri.
- Andreasen FM, Andreasen JO (1985) Diagnosis of luxation injuries: the importance of standardized clinical, radiographic and photographic techniques in clinical investigations. *Endodontics and Dental Traumatology* **1**, 160–9.
- Andreasen FM, Andreasen JO (1988) Resorption and mineralization processes following root fracture of permanent incisors. *Endodontics and Dental Traumatology* **4**, 202–14.
- Andreasen FM & Andreasen JO (2007) Luxation injuries of permanent teeth general findings. In: Andreasen JO, Andreasen FM, Andersson L, eds. *Textbook & Colour Atlas of Traumatic Injuries to the Teeth*. Oxford: Blackwell Munksgaard, pp. 372–403.
- Andreasen FM, Kahler B (2015) Pulpal response after acute dental injury in the permanent dentition: clinical implications—a review. *Journal of Endodontics* **41**, 299–308.
- Andreasen FM, Vestergaard-Pedersen B (1985) Prognosis of luxated permanent teeth—the development of pulp necrosis. *Endodontics and Dental Traumatology* **1**, 207–20.
- Andreasen FM, Zhijie Y, Thomsen BL (1986) Relationship between pulp dimensions and development of pulp necrosis after luxation injuries in the permanent dentition. *Endodontics and Dental Traumatology* **2**, 90–8.
- Andreasen FM, Zhijie Y, Thomsen BL, Andersen PK (1987) Occurrence of pulp canal obliteration after luxation injuries in the permanent dentition. *Endodontics and Dental Traumatology* **3**, 103–15.
- Andreasen JO (1970) Luxation of permanent teeth due to trauma. A clinical and radiographic follow-up study of 189 injured teeth. *Scandinavian Journal of Dental Research* **78**, 273–86.
- Andreasen JO (1981) Relationship between surface and inflammatory resorption and changes in the pulp after replantation of permanent incisors in monkeys. *Journal of Endodontics* **7**, 294–301.
- Andreasen JO, Ahrensburg SS, Tsilingaridis G (2012) Root fractures: the influence of type of healing and location of fracture on tooth survival rates - an analysis of 492 cases. *Dental Traumatology* **28**, 404–9.
- Andreasen JO, Andreasen FM, Mejare I, Cvek M (2004a) Healing of 400 intra-alveolar root fractures. 1. Effect of pre-injury and injury factors such as sex, age, stage of root development, fracture type, location of fracture and severity of dislocation. *Dental Traumatology* **20**, 192–202.
- Andreasen JO, Andreasen FM, Mejare I, Cvek M (2004b) Healing of 400 intra-alveolar root fractures. 2. Effect of treatment factors such as treatment delay, repositioning, splinting type and period and antibiotics. *Dental Traumatology* **20**, 203–11.
- Andreasen JO, Andreasen FM, Andersson L (2018) *Textbook and Color Atlas of Traumatic Injuries to the Teeth*, 5th edn. Oxford: Wiley Blackwell.
- Andreasen JO, Bakland LK, Andreasen FM (2006) Traumatic intrusion of permanent teeth. Part 2. A clinical study of the effect of preinjury and injury factors, such as sex, age, stage of root development, tooth location, and extent of injury including number of intruded teeth on 140 intruded permanent teeth. *Dental Traumatology* **22**, 90–8.
- Andreasen JO, Bakland LK (2011) Pulp regeneration after non-infected and infected necrosis, what type of tissue do we want? A review. *Dental Traumatology* **28**, 13–8.
- Andreasen JO, Borum MK, Andreasen FM (1995a) Replantation of 400 avulsed permanent incisors. 3. Factors related

- to root growth. *Endodontics and Dental Traumatology* **11**, 69–75.
- Andreasen JO, Borum MK, Jacobsen HL, Andreasen FM (1995b) Replantation of 400 avulsed permanent incisors. 1. Diagnosis of healing complications. *Endodontics and Dental Traumatology* **11**, 51–8.
- Andreasen JO, Borum MK, Jacobsen HL, Andreasen FM (1995c) Replantation of 400 avulsed permanent incisors. 2. Factors related to pulpal healing. *Endodontics and Dental Traumatology* **11**, 59–68.
- Andreasen JO, Borum MK, Jacobsen HL, Andreasen FM (1995d) Replantation of 400 avulsed permanent incisors. 4. Factors related to periodontal ligament healing. *Endodontics and Dental Traumatology* **11**, 76–89.
- Andreasen JO, Hjorting-Hansen E (1967) Intraalveolar root fractures: radiographic and histologic study of 50 cases. *Journal of Oral and Maxillofacial Surgery* **25**, 414–26.
- Anyanechi CE, Chukwunke FN (2013) Prognosis of teeth in the line of mandibular fracture: 5-year clinical and radiological follow-up. *Nigerian Journal of Medicine* **22**, 61–3.
- Aulakh KK, Gumber TK, Sandhu S (2017) Prognosis of teeth in the line of jaw fractures. *Dental Traumatology* **33**, 126–32.
- Bakland LK (2009) Revisiting traumatic pulpal exposure: materials, management principles, and techniques. *Dental Clinics of North America* **53**, 661–73.
- Bakland LK, Andreasen JO (2012) Will mineral trioxide aggregate replace calcium hydroxide in treating pulpal and periodontal healing complications subsequent to dental trauma? A review. *Dental Traumatology* **28**, 25–32.
- Balevi B (2019) Cold pulp testing is the simplest and most accurate of all dental pulp sensibility tests. *Evidence Based Dentistry* **20**, 22–3.
- Banchs F, Trope M (2004) Revascularization of immature permanent teeth with apical periodontitis: new treatment protocol? *Journal of Endodontics* **30**, 196–200.
- Bang KO, Pandilwar PK, Sheno SR *et al.* (2018) Evaluation of teeth in line of mandibular fractures treated with stable internal fixation. *Journal of Maxillofacial Oral Surgery* **17**, 164–8.
- Bastos JV, Cortes MIS (2018) Pulp canal obliteration after traumatic injuries in permanent teeth - scientific fact or fiction? *Brazilian Oral Research* **32**, e75.
- Bastos JV, Goulart EM, de Souza Cortes MI (2014) Pulpal response to sensibility tests after traumatic dental injuries in permanent teeth. *Dental Traumatology* **30**, 188–92.
- Baykul T, Erdem E, Dolanmaz D, Alkan A (2004) Impacted tooth in mandibular fracture line: treatment with closed reduction. *Journal of Oral and Maxillofacial Surgery* **62**, 289–91.
- Bhaskar SN, Rappaport HM (1973) Dental vitality tests and pulp status. *The Journal of the American Dental Association* **86**, 409–11.
- de Blanco LP (1996) Treatment of crown fractures with pulp exposure. *Oral Surgery, Oral Medicine, Oral Pathology, Oral Radiology and Endodontology* **82**, 564–8.
- Bobrowski AN, Sonego CL, Chagas Junior OL (2013) Postoperative infection associated with mandibular angle fracture treatment in the presence of teeth on the fracture line: a systematic review and meta-analysis. *International Journal of Oral and Maxillofacial Surgery* **42**, 1041–8.
- Bonte E, Beslot A, Boukpepsi T, Lasfargues JJ (2015) MTA versus Ca(OH)₂ in apexification of non-vital immature permanent teeth: a randomized clinical trial comparison. *Clinical Oral Investigations* **19**, 1381–8.
- Bose R, Nummikoski P, Hargreaves K (2009) A retrospective evaluation of radiographic outcomes in immature teeth with necrotic root canal systems treated with regenerative endodontic procedures. *Journal of Endodontics* **35**, 1343–9.
- Bourguignon C, Cohenca N, Lauridsen E *et al.* (2020) International Association of Dental Traumatology guidelines for the management of traumatic dental injuries: 1. Fractures and luxations. *Dental Traumatology* **36**, 314–30.
- Boutsioukis C, Lambrianidis T, Kastrinakis E, Bekiaroglou P (2007) Measurement of pressure and flow rates during irrigation of a root canal ex vivo with three endodontic needles. *International Endodontic Journal* **40**, 504–13.
- Boutsioukis C, Verhaagen B, Versluis M, Kastrinakis E, Wesselink PR, van der Sluis LW (2010) Evaluation of irrigant flow in the root canal using different needle types by an unsteady computational fluid dynamics model. *Journal of Endodontics* **36**, 875–9.
- Brajdic D, Virag M, Uglesic V, Aljinovic-Ratkovic N, Zajc I, Macan D (2011) Evaluation of sensitivity of teeth after mandibular fractures. *International Journal of Oral and Maxillofacial Surgery* **40**, 266–70.
- Brito-Junior M, Pereira RD, Verissimo C *et al.* (2014) Fracture resistance and stress distribution of simulated immature teeth after apexification with mineral trioxide aggregate. *International Endodontic Journal* **47**, 958–66.
- Bryson EC, Levin L, Banchs F, Abbott PV, Trope M (2002) Effect of immediate intracanal placement of Ledermix Paste(R) on healing of replanted dog teeth after extended dry times. *Dental Traumatology* **18**, 316–21.
- Bucchi C, Marce-Nogue J, Galler KM, Widbill M (2019) Biomechanical performance of an immature maxillary central incisor after revitalization: a finite element analysis. *International Endodontic Journal* **52**, 1508–18.
- Bucher K, Meier F, Diegritz C, Kaaden C, Hickel R, Kuhnisch J (2016) Long-term outcome of MTA apexification in teeth with open apices. *Quintessence International* **47**, 473–82.
- Buchgreitz J, Buchgreitz M, Mortensen D, Bjørndal L (2016) Guided access cavity preparation using cone-beam computed tomography and optical surface scans - an ex vivo study. *International Endodontic Journal* **49**, 790–5.
- Buchgreitz J, Buchgreitz M, Bjørndal L (2019) Guided root canal preparation using cone beam computed tomography and optical surface scans - an observational study of pulp space obliteration and drill path depth in 50 patients. *International Endodontic Journal* **52**, 559–68.

- Camilleri J, Laurent P, About I (2014) Hydration of Biodentine, Theracal LC, and a prototype tricalcium silicate-based dentin replacement material after pulp capping in entire tooth cultures. *Journal of Endodontics* **40**, 1846–54.
- Caputa PE, Retsas A, Kuijk L, Chavez de Paz LE, Boutsioukis C (2019) Ultrasonic irrigant activation during root canal treatment: a systematic review. *Journal of Endodontics* **45**, 31–44 e13.
- Carvalho CA, Valera MC, Oliveira LD, Camargo CH (2005) Structural resistance in immature teeth using root reinforcements in vitro. *Dental Traumatology* **21**, 155–9.
- Caviedes-Bucheli J, Gomez-Sosa JF, Azuero-Holguin MM, Ormeno-Gomez M, Pinto-Pascual V, Munoz HR (2017) Angiogenic mechanisms of human dental pulp and their relationship with substance P expression in response to occlusal trauma. *International Endodontic Journal* **50**, 339–51.
- Chaniotis A (2015) The use of a single-step regenerative approach for the treatment of a replanted mandibular central incisor with severe resorption. *International Endodontic Journal* **49**, 802–12.
- Chaniotis A (2017) Treatment options for failing regenerative endodontic procedures: report of 3 cases. *Journal of Endodontics* **43**, 1472–8.
- Chen H, Teixeira FB, Ritter AL, Levin L, Trope M (2008) The effect of intracanal anti-inflammatory medicaments on external root resorption of replanted dog teeth after extended extra-oral dry time. *Dental Traumatology* **24**, 74–8.
- Chrcanovic BR (2014) Teeth in the line of mandibular fractures. *Oral and Maxillofacial Surgery* **18**, 7–24.
- Christensen BJ, Mercante DE, Neary JP, King BJ (2017) Risk factors for severe complications of operative mandibular fractures. *Journal of Oral and Maxillofacial Surgery* **75**, 787.e1–787.e8.
- Clark D, Levin L (2018) Prognosis and complications of immature teeth following lateral luxation: a systematic review. *Dental Traumatology* **34**, 215–20.
- Clark D, Levin L (2019) Prognosis and complications of mature teeth after lateral luxation: a systematic review. *The Journal of the American Dental Association* **150**, 649–55.
- Cohenca N, Silberman A (2017) Contemporary imaging for the diagnosis and treatment of traumatic dental injuries: a review. *Dental Traumatology* **33**, 321–8.
- Connert T, Krug R, Eggmann F et al. (2019) Guided endodontics versus conventional access cavity preparation: a comparative study on substance loss using 3-dimensional-printed teeth. *Journal of Endodontics* **45**, 327–31.
- Connert T, Zehnder MS, Weiger R, Kuhl S, Krstl G (2017) Microguided endodontics: accuracy of a miniaturized technique for apically extended access cavity preparation in anterior teeth. *Journal of Endodontics* **43**, 787–90.
- Costa CA, Hebling J, Hanks CT (2000) Current status of pulp capping with dentin adhesive systems: a review. *Dental Materials* **16**, 188–97.
- Costa LA, Ribeiro CC, Cantanhede LM, Santiago Junior JF, de Mendonca MR, Pereira AL (2017) Treatments for intrusive luxation in permanent teeth: a systematic review and meta-analysis. *International Journal of Oral and Maxillofacial Surgery* **46**, 214–29.
- Cox CF, Bergholtz G, Fitzgerald M et al. (1982) Capping of the dental pulp mechanically exposed to the oral microflora - a 5 week observation of wound healing in the monkey. *Journal of Oral Pathology* **11**, 327–39.
- Cvek M (1972) Treatment of non-vital permanent incisors with calcium hydroxide. I. Follow-up of periapical repair and apical closure of immature roots. *Odontologisk Revy* **23**, 27–44.
- Cvek M (1978) A clinical report on partial pulpotomy and capping with calcium hydroxide in permanent incisors with complicated crown fracture. *Journal of Endodontics* **4**, 232–7.
- Cvek M (1992) Prognosis of luxated non-vital maxillary incisors treated with calcium hydroxide and filled with gutta-percha. A retrospective clinical study. *Endodontics and Dental Traumatology* **8**, 45–55.
- Cvek M (1993) Partial pulpotomy in crown-fractured incisors - results 3–15 years after trauma. *Acta Stomatologica Croatica* **27**, 167–73.
- Cvek M, Cleaton-Jones PE, Austin JC, Andreasen JO (1982a) Pulp reactions to exposure after experimental crown fractures or grinding in adult monkeys. *Journal of Endodontics* **8**, 391–7.
- Cvek M, Cleaton-Jones P, Austin J, Lownie J, Kling M, Fatti P (1990a) Effect of topical application of doxycycline on pulp revascularization and periodontal healing in replanted monkey incisors. *Endodontics and Dental Traumatology* **6**, 170–6.
- Cvek M, Cleaton-Jones P, Austin J, Lownie J, Kling M, Fatti P (1990b) Pulp revascularization in replanted immature monkey incisors—predictability and the effect of antibiotic systemic prophylaxis. *Endodontics and Dental Traumatology* **6**, 157–69.
- Cvek M, Granath L, Lundberg M (1982b) Failures and healing in endodontically treated non-vital anterior teeth with posttraumatically reduced pulpal lumen. *Acta Odontologica Scandinavica* **40**, 223–8.
- Cvek M, Mejare I, Andreasen JO (2004) Conservative endodontic treatment of teeth fractured in the middle or apical part of the root. *Dental Traumatology* **20**, 261–9.
- Cvek M, Tsilingaridis G, Andreasen JO (2008) Survival of 534 incisors after intra-alveolar root fracture in patients aged 7–17 years. *Dental Traumatology* **24**, 379–87.
- Dammaschke T, Galler KM, Krstl G (2019a) Current recommendations for vital pulp treatment. *Deutsche Zahnärztliche Zeitschrift International* **1**, 43–52.
- Dammaschke T, Nowicka A, Lipski M, Ricucci D (2019b) Histological evaluation of hard tissue formation after direct pulp capping with a fast-setting mineral trioxide aggregate

- (RetroMTA) in humans. *Clinical Oral Investigations* **23**, 4289–99.
- Darcey J, Qualtrough A (2013) Resorption: part 2. Diagnosis and management. *British Dental Journal* **214**, 493–509.
- Day P, Flores MT, O'Connell A et al. (2020) International Association of Dental Traumatology guidelines for the management of traumatic dental injuries: 3. Injuries in the primary dentition. *Dental Traumatology* **36**, 343–59.
- Day PF, Gregg TA, Ashley P et al. (2012) Periodontal healing following avulsion and replantation of teeth: a multicentre randomized controlled trial to compare two root canal medicaments. *Dental Traumatology* **28**, 55–64.
- de Almeida Geraldino R, Rezende L, da-Silva CQ, Almeida JCF (2017) Remote diagnosis of traumatic dental injuries using digital photographs captured via a mobile phone. *Dental Traumatology* **33**, 350–7.
- Desai S, Chandler N (2009) The restoration of permanent immature anterior teeth, root filled using MTA: a review. *Journal of Dentistry* **37**, 652–7.
- Dettwiler CA, Walter M, Zaugg LK, Lenherr P, Weiger R, Krastl G (2016) In vitro assessment of the tooth staining potential of endodontic materials in a bovine tooth model. *Dental Traumatology* **32**, 480–7.
- Dula K, Bornstein MM, Buser D et al. (2014) SADMFR guidelines for the use of cone-beam computed tomography/ digital volume tomography. *Swiss Dental Journal* **124**, 1169–83.
- Ebeleseder K (1994) A suggestion of a new classification system of traumatic dental injuries. *Endodontics and Dental Traumatology* **10**, 39.
- Ebeleseder KA, Santler G, Glockner K, Hulla H, Pertl C, Quehenberger F (2000) An analysis of 58 traumatically intruded and surgically extruded permanent teeth. *Endodontics and Dental Traumatology* **16**, 34–9.
- ElAyouti A, Kimionis I, Chu AL, Löst C (2005) Determining the apical terminus of root-end resected teeth using three modern apex locators: a comparative ex vivo study. *International Endodontic Journal* **38**, 827–33.
- Ellis E III (2002) Outcomes of patients with teeth in the line of mandibular angle fractures treated with stable internal fixation. *Journal of Oral and Maxillofacial Surgery* **60**, 863–5.
- El-Meligy OA, Avery DR (2006) Comparison of apexification with mineral trioxide aggregate and calcium hydroxide. *Pediatric Dentistry* **28**, 248–53.
- ESE (2006) Quality guidelines for endodontic treatment: consensus report of the European Society of Endodontology. *International Endodontic Journal* **39**, 921–30.
- ESE (2016) European Society of Endodontology position statement: revitalization procedures. *International Endodontic Journal* **49**, 717–23.
- ESE (2019a) European Society of Endodontology position statement: use of cone beam computed tomography in Endodontics. *International Endodontic Journal* **52**, 1675–8.
- ESE (2019b) European Society of Endodontology position statement: management of deep caries and the exposed pulp. *International Endodontic Journal* **52**, 923–34.
- Filippi A, Tschan J, Pohl Y, Berthold H, Ebeleseder K (2000) A retrospective classification of tooth injuries using a new scoring system. *Clinical Oral Investigations* **4**, 173–5.
- Fouad AF, Abbott PV, Tsilingaridis G et al. (2020) International Association of Dental Traumatology guidelines for the management of traumatic dental injuries: 2. Avulsion of permanent teeth. *Dental Traumatology* **36**, 331–42.
- Frank AL (1966) Therapy for the divergent pulpless tooth by continued apical formation. *The Journal of the American Dental Association* **72**, 87–93.
- Fuks AB, Bielak S, Chosak A (1982) Clinical and radiographic assessment of direct pulp capping and pulpotomy in young permanent teeth. *Pediatric Dentistry* **4**, 240–4.
- Fuks AB, Cosack A, Klein H, Eidelman E (1987) Partial pulpotomy as a treatment alternative for exposed pulps in crown-fractured permanent incisors. *Endodontics and Dental Traumatology* **3**, 100–2.
- Fulling HJ, Andreasen JO (1976) Influence of maturation status and tooth type of permanent teeth upon electrometric and thermal pulp testing. *Scandinavian Journal of Dental Research* **84**, 286–90.
- Fuss Z, Rafaeloff R, Tagger M, Szajkis S (1996) Intracanal pH changes of calcium hydroxide pastes exposed to carbon dioxide in vitro. *Journal of Endodontics* **22**, 362–4.
- Fuss Z, Trowbridge H, Bender IB, Rickoff B, Sorin S (1986) Assessment of reliability of electrical and thermal pulp testing agents. *Journal of Endodontics* **12**, 301–5.
- Garberoglio R, Brannstrom M (1976) Scanning electron microscopic investigation of human dentinal tubules. *Archives of Oral Biology* **21**, 355–62.
- Ghouth N, Duggal MS, BaniHani A, Nazzal H (2018) The diagnostic accuracy of laser Doppler flowmetry in assessing pulp blood flow in permanent teeth: a systematic review. *Dental Traumatology* **34**, 311–9.
- Ghouth N, Duggal MS, Kang J, Nazzal H (2019) A diagnostic accuracy study of laser doppler flowmetry for the assessment of pulpal status in children's permanent incisor teeth. *Journal of Endodontics* **45**, 543–8.
- Goodis HE, Kahn A, Simon S (2012) Aging and the Pulp. In: Hargreaves K, Goodis HE, Tay F, eds. *Seltzer and Bender's Dental Pulp*, 2nd edn. Berlin: Quintessenz.
- Gregorczyk-Maga I, Kaszuba M, Olszewska M et al. (2019) Biomarkers of inflammatory external root resorption as a result of traumatic dental injury to permanent teeth in children. *Archives of Oral Biology* **99**, 82–91.
- Haikal L, Ferraz Dos Santos B, Vu DD, Braniste M, Dabbagh B (2020) Biodentine pulpotomies on permanent traumatized teeth with complicated crown fractures. *Journal of Endodontics* **46**, 1204–9.
- Hebling J, Lessa FC, Nogueira I, Carvalho RM, Costa CA (2009) Cytotoxicity of resin-based light-cured liners. *American Journal of Dentistry* **22**, 137–42.

- Hecova H, Tzigkounakis V, Merglova V, Netolicky J (2010) A retrospective study of 889 injured permanent teeth. *Dental Traumatology* **26**, 466–75.
- Heide S, Mjor IA (1983) Pulp reactions to experimental exposures in young permanent monkey teeth. *International Endodontic Journal* **16**, 11–9.
- Heithersay GS (2007) Management of tooth resorption. *Australian Dental Journal* **52**, S105–S121.
- Heithersay GS, Kahler B (2013) Healing responses following transverse root fracture: a historical review and case reports showing healing with (a) calcified tissue and (b) dense fibrous connective tissue. *Dental Traumatology* **29**, 253–65.
- Hinckfuss SE, Messer LB (2009) An evidence-based assessment of the clinical guidelines for replanted avulsed teeth. Part II: prescription of systemic antibiotics. *Dental Traumatology* **25**, 158–64.
- Holcomb JB, Gregory WB Jr (1967) Calcific metamorphosis of the pulp: its incidence and treatment. *Oral Surgery, Oral Medicine, and Oral Pathology* **24**, 825–30.
- Horner K, Rushton V, Tsiklakis K et al. (2004) In: Communities OfOPotE, ed. *European Guidelines on Radiation Protection in Dental Radiology. The Safe Use of Radiographs in Dental Practice*. Luxembourg: Office for Official Publications of the European Communities.
- Iwaya SI, Ikawa M, Kubota M (2001) Revascularization of an immature permanent tooth with apical periodontitis and sinus tract. *Dental Traumatology* **17**, 185–7.
- Jacobsen I (1980) Criteria for diagnosis of pulp necrosis in traumatized permanent incisors. *Scandinavian Journal of Dental Research* **88**, 306–12.
- Jacobsen I, Kerekes K (1977) Long-term prognosis of traumatized permanent anterior teeth showing calcifying processes in the pulp cavity. *Scandinavian Journal of Dental Research* **85**, 588–98.
- Jafarzadeh H, Abbott PV (2010) Review of pulp sensibility tests. Part I: general information and thermal tests. *International Endodontic Journal* **43**, 738–62.
- Kahler B, Rossi-Fedele G, Chugal N, Lin LM (2017) An Evidence-based review of the efficacy of treatment approaches for immature permanent teeth with pulp necrosis. *Journal of Endodontics* **43**, 1052–7.
- Kahnberg KE (1996) Intra-alveolar transplantation. I. A 10-year follow-up of a method for surgical extrusion of root fractured teeth. *Swedish Dental Journal* **20**, 165–72.
- Kahnberg KE, Ridell A (1979) Prognosis of teeth involved in the line of mandibular fractures. *International Journal of Oral Surgery* **8**, 163–72.
- Kamboozia AH, Punmia-Moorthy A (1993) The fate of teeth in mandibular fracture lines. A clinical and radiographic follow-up study. *International Journal of Oral and Maxillofacial Surgery* **22**, 97–101.
- Kenny DJ, Barrett EJ, Casas MJ (2003) Avulsions and intrusions: the controversial displacement injuries. *Journal of the Canadian Dental Association* **69**, 308–14.
- Ketterl W (1961) Studie über das Dentin der permanenten Zähne des Menschen. *Stomatologie* **14**, 79–112.
- Kiefner P, Connert T, ElAyouti A, Weiger R (2017) Treatment of calcified root canals in elderly people: a clinical study about the accessibility, the time needed and the outcome with a three-year follow-up. *Gerodontology* **34**, 164–70.
- Kim SG, Malek M, Sigurdsson A, Lin LM, Kahler B (2018) Regenerative endodontics: a comprehensive review. *International Endodontic Journal* **51**, 1367–88.
- Kling M, Cvek M, Mejare I (1986) Rate and predictability of pulp revascularization in therapeutically reimplanted permanent incisors. *Endodontics and Dental Traumatology* **2**, 83–9.
- Koenig WR, Olsson AB, Pensler JM (1994) The fate of developing teeth in facial trauma: tooth buds in the line of mandibular fractures in children. *Annals of Plastic Surgery* **32**, 503–5.
- Krstl G, Allgayer N, Lenherr P, Filippi A, Taneja P, Weiger R (2013) Tooth discoloration induced by endodontic materials: a literature review. *Dental Traumatology* **29**, 2–7.
- Krstl G, Filippi A, Zitzmann NU, Walter C, Weiger R (2011) Current aspects of restoring traumatically fractured teeth. *European Journal of Esthetic Dentistry* **6**, 124–41.
- Krstl G, Filippi A, Weiger R (2020) Initial management of dental trauma: musts, shoulds, and cans. *Quintessence International* **51**, 763–74.
- Krstl G, Weiger R (2014) Vital pulp therapy after trauma. *ENDO* **8**, 293–300.
- Krstl G, Zehnder MS, Connert T, Weiger R, Kühl S (2016) Guided Endodontics: a novel treatment approach for teeth with pulp canal calcification and apical pathology. *Dental Traumatology* **32**, 240–6.
- Kristerson L, Andreassen JO (1983) The effect of splinting upon periodontal and pulpal healing after autotransplantation of mature and immature permanent incisors in monkeys. *International Journal of Oral Surgery* **12**, 239–49.
- Kumar PP, Sridhar BS, Palle R, Singh N, Singamaneni VK, Rajesh P (2014) Prognosis of teeth in the line of mandibular fractures. *Journal of Pharmacy and Bioallied Sciences* **6**, S97–S100.
- Kvinnslund I, Heyeraas KJ, Byers MR (1992) Effects of dental trauma on pulpal and periodontal nerve morphology. *Proceedings of the Finnish Dental Society* **88**(Suppl. 1), 125–32.
- Larsen OD, Nielsen A (1976) Mandibular fractures. II. A follow-up study of 229 patients. *Scandinavian Journal of Plastic and Reconstructive Surgery* **10**, 219–26.
- Lauridsen E, Andreassen JO, Bouaziz O, Andersson L (2019) Risk of ankylosis of 400 avulsed and replanted human teeth in relation to length of dry storage: a re-evaluation of a long-term clinical study. *Dental Traumatology* **36**, 108–16.
- Lauridsen E, Gerds T, Andreassen JO (2016) Alveolar process fractures in the permanent dentition. Part 2. The risk of

- healing complications in teeth involved in an alveolar process fracture. *Dental Traumatology* **32**, 128–39.
- Lauridsen E, Hermann NV, Gerds TA, Ahrensburg SS, Kreiborg S, Andreasen JO (2012a) Combination injuries 1. The risk of pulp necrosis in permanent teeth with concussion injuries and concomitant crown fractures. *Dental Traumatology* **28**, 364–70.
- Lauridsen E, Hermann NV, Gerds TA, Ahrensburg SS, Kreiborg S, Andreasen JO (2012b) Combination injuries 2. The risk of pulp necrosis in permanent teeth with subluxation injuries and concomitant crown fractures. *Dental Traumatology* **28**, 371–8.
- Lauridsen E, Hermann NV, Gerds TA, Ahrensburg SS, Kreiborg S, Andreasen JO (2012c) Combination injuries 3. The risk of pulp necrosis in permanent teeth with extrusion or lateral luxation and concomitant crown fractures without pulp exposure. *Dental Traumatology* **28**, 379–85.
- Lengheden A (1994) Influence of pH and calcium on growth and attachment of human fibroblasts in vitro. *Scandinavian Journal of Dental Research* **102**, 130–6.
- Lengheden A, Jansson L (1995) pH effects on experimental wound healing of human fibroblasts in vitro. *European Journal of Oral Sciences* **103**, 148–55.
- Lenherr P, Allgayer N, Weiger R, Filippi A, Attin T, Krastl G (2012) Tooth discoloration induced by endodontic materials: a laboratory study. *International Endodontic Journal* **45**, 942–9.
- Levin L, Day P, Hicks L et al. (2020) International Association of Dental Traumatology guidelines for the management of traumatic dental injuries: general introduction. *Dental Traumatology* **36**, 309–13.
- Lima TFR, Dos Santos SL, da Silva Fidalgo TK, Silva E (2019) Vitality tests for pulp diagnosis of traumatized teeth: a systematic review. *Journal of Endodontics* **45**, 490–9.
- Lin J, Zeng Q, Wei X et al. (2017) Regenerative endodontics versus apexification in immature permanent teeth with apical periodontitis: a prospective randomized controlled study. *Journal of Endodontics* **43**, 1821–7.
- Lin LM, Shimizu E, Gibbs JL, Loghin S, Ricucci D (2014) Histologic and histobacteriologic observations of failed revascularization/revitalization therapy: a case report. *Journal of Endodontics* **40**, 291–5.
- Lipski M, Nowicka A, Kot K et al. (2018) Factors affecting the outcomes of direct pulp capping using Biodentine. *Clinical Oral Investigations* **22**, 2021–9.
- Love RM (1996) Bacterial penetration of the root canal of intact incisor teeth after a simulated traumatic injury. *Endodontics and Dental Traumatology* **12**, 289–93.
- Malmgren B, Hubel S (2012) Transient discoloration of the coronal fragment in intra-alveolar root fractures. *Dental Traumatology* **28**, 200–4.
- Mangone G, Longo F, Friscia M, Ferrara S, Califano L (2011) Morbidity of teeth in the line of the fracture. *Minerva stomatologica* **60**, 223–7.
- Marotti M, Ebeleseder KA, Schwantzer G, Jauk S (2017) A retrospective study of isolated fractures of the alveolar process in the permanent dentition. *Dental Traumatology* **33**, 165–74.
- McCabe PS, Dummer PM (2012) Pulp canal obliteration: an endodontic diagnosis and treatment challenge. *International Endodontic Journal* **45**, 177–97.
- McNamara Z, Findlay G, O'Rourke P, Batstone M (2016) Removal versus retention of asymptomatic third molars in mandibular angle fractures: a randomized controlled trial. *International Journal of Oral and Maxillofacial Surgery* **45**, 571–4.
- Medeiros RB, Mucha JN (2009) Immediate vs late orthodontic extrusion of traumatically intruded teeth. *Dental Traumatology* **25**, 380–5.
- Mente J, Hage N, Pfefferle T et al. (2009) Mineral trioxide aggregate apical plugs in teeth with open apical foramina: a retrospective analysis of treatment outcome. *Journal of Endodontics* **35**, 1354–8.
- Meschi N, Hilkens P, Lambrichts I et al. (2016) Regenerative endodontic procedure of an infected immature permanent human tooth: an immunohistological study. *Clinical Oral Investigations* **20**, 807–14.
- Mjor I (2009) Dentin permeability: the basis for understanding pulp reactions and adhesive technology. *Brazilian Dental Journal* **20**, 3–16.
- Moore A, Howley MF, O'Connell AC (2011) Treatment of open apex teeth using two types of white mineral trioxide aggregate after initial dressing with calcium hydroxide in children. *Dental Traumatology* **27**, 166–73.
- Mozynska J, Metlerski M, Lipski M, Nowicka A (2017) Tooth discoloration induced by different calcium silicate-based cements: a systematic review of in vitro studies. *Journal of Endodontics* **43**, 1593–601.
- Munir A, Zehnder M, Rechenberg DK (2020) Wound lavage in studies on vital pulp therapy of permanent teeth with carious exposures: a qualitative systematic review. *Journal of Clinical Medicine* **9**, 984.
- Murray PE, Stanley HR, Matthews JB, Sloan AJ, Smith AJ (2002) Age-related odontometric changes of human teeth. *Oral Surgery, Oral Medicine, Oral Pathology, Oral Radiology, and Endodontology* **93**, 474–82.
- Nair PN, Duncan HF, Pitt Ford TR, Luder HU (2008) Histological, ultrastructural and quantitative investigations on the response of healthy human pulps to experimental capping with mineral trioxide aggregate: a randomized controlled trial. *International Endodontic Journal* **41**, 128–50.
- Neal DC, Wagner WF, Alpert B (1978) Morbidity associated with teeth in the line of mandibular fractures. *Journal of Oral Surgery* **36**, 859–62.
- Nerwich A, Figdor D, Messer HH (1993) pH changes in root dentin over a 4-week period following root canal dressing with calcium hydroxide. *Journal of Endodontics* **19**, 302–6.
- Nikhil V, Jha P, Aggarwal A (2015) Comparative evaluation of fracture resistance of simulated immature teeth restored

- with glass fiber posts, intracanal composite resin, and experimental dentine posts. *Scientific World Journal* **2015**, 1–5.
- Oginni AO, Adekoya-Sofowora CA, Kolawole KA (2009) Evaluation of radiographs, clinical signs and symptoms associated with pulp canal obliteration: an aid to treatment decision. *Dental Traumatology* **25**, 620–5.
- Oikarinen K, Lahti J, Raustia AM (1990) Prognosis of permanent teeth in the line of mandibular fractures. *Endodontics and Dental Traumatology* **6**, 177–82.
- Olsburgh S, Jacoby T, Krejci I (2002) Crown fractures in the permanent dentition: pulpal and restorative considerations. *Dental Traumatology* **18**, 103–15.
- Pace R, Giuliani V, Nieri M, Di Nasso L, Pagavino G (2014) Mineral Trioxide Aggregate as apical plug in teeth with necrotic pulp and immature apices: a 10-year case series. *Journal of Endodontics* **40**, 1250–4.
- Parinyaprom N, Nirunsittirat A, Chuveera P et al. (2018) Outcomes of direct pulp capping by using either ProRoot Mineral Trioxide Aggregate or Biodentine in permanent teeth with carious pulp exposure in 6- to 18-year-old patients: a randomized controlled trial. *Journal of Endodontics* **44**, 341–8.
- Parirokh M, Torabinejad M (2009) Mineral trioxide aggregate: a comprehensive literature review - part III: clinical applications, drawbacks, and mechanism of action. *Journal of Endodontics* **36**, 400–13.
- Patel S, Durack C, Abella F, Shemesh H, Roig M, Lemberg K (2015) Cone beam computed tomography in Endodontics - a review. *International Endodontic Journal* **48**, 3–15.
- Patel S, Durack C, Ricucci D (2016) Root Resorption. In: Hargreaves K, Berman LH, eds. *Cohen's Pathways of the Pulp*. St. Louis: Elsevier.
- Patterson SS, Mitchell DF (1965) Calcific metamorphosis of the dental pulp. *Oral Surgery, Oral Medicine, Oral Pathology, Oral Radiology* **20**, 94–101.
- Pierce A, Berg JO, Lindskog S (1988a) Calcitonin as an alternative therapy in the treatment of root resorption. *Journal of Endodontics* **14**, 459–64.
- Pierce A, Heithersay G, Lindskog S (1988b) Evidence for direct inhibition of dentinoclasts by a corticosteroid/antibiotic endodontic paste. *Endodontics and Dental Traumatology* **4**, 44–5.
- Pierce A, Lindskog S (1987) The effect of an antibiotic/corticosteroid paste on inflammatory root resorption in vivo. *Oral Surgery, Oral Medicine, and Oral Pathology* **64**, 216–20.
- Pitt Ford TR, Roberts GJ (1991) Immediate and delayed direct pulp capping with the use of a new visible light-cured calcium hydroxide preparation. *Oral Surgery, Oral Medicine, and Oral Pathology* **71**, 338–42.
- Pradhan DP, Chawla HS, Gauba K, Goyal A (2006) Comparative evaluation of endodontic management of teeth with unformed apices with mineral trioxide aggregate and calcium hydroxide. *Journal of Dentistry for Children* **73**, 79–85.
- Rafter M (2005) Apexification: a review. *Dental Traumatology* **21**, 1–8.
- Ramakrishnan J, Shingleton A, Reeves D, Key JM, Vural E (2009) The effects of molar tooth involvement in mandibular angle fractures treated with rigid fixation. *Otolaryngology Head and Neck Surgery* **140**, 845–8.
- Rao Q, Kuang J, Mao C et al. (2020) Comparison of iRoot BP Plus and Calcium Hydroxide as pulpotomy materials in permanent incisors with complicated crown fractures: a retrospective study. *Journal of Endodontics* **46**, 352–7.
- Ravn JJ (1981a) Follow-up study of permanent incisors with enamel cracks as result of an acute trauma. *Scandinavian Journal of Dental Research* **89**, 117–23.
- Ravn JJ (1981b) Follow-up study of permanent incisors with enamel-dentin fractures after acute trauma. *Scandinavian Journal of Dental Research* **89**, 355–65.
- Ravn JJ (1982) Follow-up study of permanent incisors with complicated crown fractures after acute trauma. *Scandinavian Journal of Dental Research* **90**, 363–72.
- Ree MH, Schwartz RS (2017) Long-term success of nonvital, immature permanent incisors treated with a Mineral Trioxide Aggregate plug and adhesive restorations: a case series from a private endodontic practice. *Journal of Endodontics* **43**, 1370–7.
- Robertson A, Andreasen FM, Bergenholtz G, Andreasen JO, Noren JG (1996) Incidence of pulp necrosis subsequent to pulp canal obliteration from trauma of permanent incisors. *Journal of Endodontics* **22**, 557–60.
- Robertson A, Andreasen FM, Andreasen JO, Noren JG (2000) Long-term prognosis of crown-fractured permanent incisors. The effect of stage of root development and associated luxation injury. *International Journal of Paediatric Dentistry* **10**, 191–9.
- Rock WP, Grundy MC (1981) The effect of luxation and subluxation upon the prognosis of traumatized incisor teeth. *Journal of Dentistry* **9**, 224–30.
- Santiago CN, Pinto SS, Sassone LM, Hirata R Jr, Fidel SR (2015) Revascularization technique for the treatment of external inflammatory root resorption: a report of 3 cases. *Journal of Endodontics* **41**, 1560–4.
- Saoud TM, Mistry S, Kahler B, Sigurdsson A, Lin LM (2016) Regenerative endodontic procedures for traumatized teeth after horizontal root fracture, avulsion, and perforating root resorption. *Journal of Endodontics* **42**, 1476–82.
- Schendel KU, Schwartz O, Andreasen JO, Hoffmeister B (1990) Reinnervation of autotransplanted teeth. A histological investigation in monkeys. *International Journal of Oral and Maxillofacial Surgery* **19**, 247–9.
- Schmoldt SJ, Kirkpatrick TC, Rutledge RE, Yaccino JM (2011) Reinforcement of simulated immature roots restored with composite resin, mineral trioxide aggregate, gutta-percha, or a fiber post after thermocycling. *Journal of Endodontics* **37**, 1390–3.
- Scott RA, Teo N, Perry M (2014) Displacement of mandibular fractures: is there a correlation with sensory loss and

- recovery? *International Journal of Oral and Maxillofacial Surgery* **43**, 555–8.
- Seghi RR, Nasrin S, Draney J, Katsube N (2013) Root fortification. *Journal of Endodontics* **39**, S57–62.
- Seto B, Chung KH, Johnson J, Paranjpe A (2013) Fracture resistance of simulated immature maxillary anterior teeth restored with fiber posts and composite to varying depths. *Dental Traumatology* **29**, 394–8.
- Simon S, Rilliard F, Berdal A, Machtou P (2007) The use of mineral trioxide aggregate in one-visit apexification treatment: a prospective study. *International Endodontic Journal* **40**, 186–97.
- Sipahi Calis A, Efeoglu C, Koca H (2017) The effect of teeth in mandibular fracture lines. *Dental Traumatology* **33**, 194–8.
- Skieller V (1960) The prognosis for young teeth loosened after mechanical injuries. *Acta Odontologica Scandinavica* **18**, 171.
- Skoglund A, Tronstad L, Wallenius K (1978) A microangiographic study of vascular changes in replanted and auto-transplanted teeth of young dogs. *Oral Surgery, Oral Medicine, Oral Pathology* **45**, 17–28.
- Smith JW (1982) Calcific metamorphosis: a treatment dilemma. *Oral Surgery, Oral Medicine, Oral Pathology* **54**, 441–4.
- Stalhane I, Hedegard B (1975) Traumatized permanent teeth in children aged 7–15 years. *Svensk Tandlakare Tidskrift* **68**, 157–69.
- Stenvik A, Iversen J, Mjor IA (1972) Tissue pressure and histology of normal and inflamed tooth pulps in macaque monkeys. *Archives of Oral Biology* **17**, 1501–11.
- Suei Y, Mallick PC, Nagasaki T, Taguchi A, Fujita M, Tanimoto K (2006) Radiographic evaluation of the fate of developing tooth buds on the fracture line of mandibular fractures. *Journal of Oral and Maxillofacial Surgery* **64**, 94–9.
- Swimberghe RCD, De Clercq A, De Moor RJG, Meire MA (2019) Efficacy of sonically, ultrasonically and laser-activated irrigation in removing a biofilm-mimicking hydrogel from an isthmus model. *International Endodontic Journal* **52**, 515–23.
- Tay AB, Lai JB, Lye KW et al. (2015) Inferior alveolar nerve injury in trauma-induced mandible fractures. *Journal of Oral and Maxillofacial Surgery* **73**, 1328–40.
- Tieu LD, Saltaji H, Normando D, Flores-Mir C (2014) Radiologically determined orthodontically induced external apical root resorption in incisors after non-surgical orthodontic treatment of class II division 1 malocclusion: a systematic review. *Progress in Orthodontics* **15**, 48.
- Tobiska S, Krastl G (2018) 12 years' preservation of maxillary permanent incisors with cervical root fractures adjacent to aggressive periodontitis: report of a case. *Quintessence International* **49**, 543–8.
- Tong HJ, Rajan S, Bhujel N, Kang J, Duggal M, Nazzal H (2017) Regenerative endodontic therapy in the management of nonvital immature permanent teeth: a systematic review-outcome evaluation and meta-analysis. *Journal of Endodontics* **43**, 1453–64.
- Torabinejad M, Nosrat A, Verma P, Udochukwu O (2017) Regenerative endodontic treatment or Mineral Trioxide Aggregate apical plug in teeth with necrotic pulps and open apices: a systematic review and meta-analysis. *Journal of Endodontics* **43**, 1806–20.
- Tronstad L (1988) Root resorption - etiology, terminology and clinical manifestations. *Endodontics and Dental Traumatology* **4**, 241–52.
- Tronstad L, Andreasen JO, Hasselgren G, Kristerson L, Riis I (1981) pH changes in dental tissues after root canal filling with calcium hydroxide. *Journal of Endodontics* **7**, 17–21.
- Trope M (2002) Root resorption due to dental trauma. *Endodontic Topics* **1**, 79–100.
- Trope M (2006) Treatment of the immature teeth with non-vital pulps and apical periodontitis. *Endodontics Topics* **14**, 51–9.
- Trope M (2011) Avulsion of permanent teeth: theory to practice. *Dental Traumatology* **27**, 281–94.
- Trope M, Moshonov J, Nissan R, Buxt P, Yesilsoy C (1995) Short vs. long-term calcium hydroxide treatment of established inflammatory root resorption in replanted dog teeth. *Endodontics Dental Traumatology* **11**, 124–8.
- Tsilingaridis G, Malmgren B, Andreasen JO, Malmgren O (2012) Intrusive luxation of 60 permanent incisors: a retrospective study of treatment and outcome. *Dental Traumatology* **28**, 416–22.
- Tzanetakis GN (2018) Management of intruded immature maxillary central incisor with pulp necrosis and severe external resorption by regenerative approach. *Journal of Endodontics* **44**, 245–9.
- Viduskalne I, Care R (2010) Analysis of the crown fractures and factors affecting pulp survival due to dental trauma. *Stomatologija* **12**, 109–15.
- Vladimirov BS, Petrov B (2005) A retrospective study on the approach to the tooth in the fracture line of the mandible. *Folia Medicine* **47**, 58–64.
- Wang G, Wang C, Qin M (2017) Pulp prognosis following conservative pulp treatment in teeth with complicated crown fractures—a retrospective study. *Dental Traumatology* **33**, 255–60.
- Wang X, Thibodeau B, Trope M, Lin LM, Huang GT (2010) Histologic characterization of regenerated tissues in canal space after the revitalization/revascularization procedure of immature dog teeth with apical periodontitis. *Journal of Endodontics* **36**, 56–63.
- Whitworth J (2018) Endodontic complications after trauma. In: Bjorndal L, Kirkevang LL, Withworth J, eds. *Textbook of Endodontology*. Oxford: Wiley and Sons Ltd.
- Witherspoon DE, Small JC, Regan JD, Nunn M (2008) Retrospective analysis of open apex teeth obturated with mineral trioxide aggregate. *Journal of Endodontics* **34**, 1171–6.

- Wong KS, Sae-Lim V (2002) The effect of intracanal Ledermix on root resorption of delayed-replanted monkey teeth. *Dental Traumatology* **18**, 309–15.
- Yamamoto K, Matsusue Y, Murakami K *et al.* (2010) Fate of developing tooth buds located in relation to mandibular fractures in three infancy cases. *Dental Traumatology* **26**, 353–6.
- Yang Y, Xia B, Xu Z, Dou G, Lei Y, Yong W (2020) The effect of partial pulpotomy with iRoot BP Plus in traumatized immature permanent teeth: a randomized prospective controlled trial. *Dental Traumatology* **36**, 518–25.
- Yassen GH, Platt JA (2013) The effect of nonsetting calcium hydroxide on root fracture and mechanical properties of radicular dentine: a systematic review. *International Endodontic Journal* **46**, 112–8.
- Yoshpe M, Einy S, Ruparel N, Lin S, Kaufman AY (2020) Regenerative endodontics: a potential solution for external root resorption (case series). *Journal of Endodontics* **46**, 192–9.
- Zanakis S, Tasoulas J, Angelidis I, Dendrinis C (2015) Tooth in the line of angle fractures: the impact in the healing process. A retrospective study of 112 patients. *Journal of Cranio-Maxillofacial Surgery* **43**, 113–6.
- Zehnder MS, Connert T, Weiger R, Krastl G, Kühl S (2016) Guided endodontics: accuracy of a novel method for guided access cavity preparation and root canal location. *International Endodontic Journal* **49**, 966–72.
- Zhou R, Wang Y, Chen Y *et al.* (2017) Radiographic, histologic, and biomechanical evaluation of combined application of platelet-rich fibrin with blood clot in regenerative endodontics. *Journal of Endodontics* **43**, 2034–40.