

Stroke Risk Factors Prepare Rat Brainstem Tissues for Modified Local Shwartzman Reaction

J.M. Hallenbeck, MD, A.J. Dutka, MD, P.M. Kochanek, MD,
A. Siren, G.H. Pezeshkpour, and G. Feuerstein, MD

Stroke risk factors such as hypertension, diabetes, advanced age, and genetic predisposition to stroke were demonstrated to prepare rat brainstem tissues for a modified local Shwartzman reaction. A single intracisternal injection of endotoxin provoked the reaction, and affected rats manifested neurologic deficits accompanied by pathologic lesions. Brainstem infarcts developed in only a small proportion of rats without recognized risk factors after intracisternal injection of endotoxin. Thus, stroke risk factors, which are ordinarily regarded as operating through acceleration of atherosclerosis, may predispose to brain ischemia by local effects on brain microcirculation such as those thought to underlie preparation of a tissue for the local Shwartzman reaction. (*Stroke* 1988;19:863-869)

Risk factors for stroke such as hypertension, diabetes, and advanced age are generally thought to express themselves by accelerating atherosclerosis.¹ The atherosclerotic process becomes most pronounced at various sites in the extracranial arteries, and associated strokes are usually attributed to hemodynamic² or thromboembolic³ mechanisms. Each of these pathophysiologic concepts leads to observable predictions. Hemodynamic theories argue for a direct proportion between the degree of carotid stenosis and the frequency of transient ischemic attack (TIA) or stroke. Thromboembolic theories lead to the expectation that the extent of platelet accumulation on carotid plaques

correlates with ipsilateral ischemic events. Neither prediction has been fulfilled in several recent studies.⁴⁻⁹

The possibility that activation of systems mediating coagulation, inflammation, and immunity perturb the local regulation of hemostasis in parenchymal and extraparenchymal brain vessels has been less commonly cited as a potential pathogenetic mechanism for stroke. Recent studies indicate that the function of morphologically intact endothelium can be altered by mediators generated from both soluble¹⁰ and cellular¹¹ systems in blood. Under the influence of these mediators, the luminal surface of the endothelium is transformed from an anticoagulant to a procoagulant membrane, and focal fibrin, platelet, and leukocyte deposition is initiated on the blood vessel wall. Such transformations of the endothelial surface can focus a systemic activation of coagulation to produce circumscribed tissue damage by means of a paradigm termed the "local Shwartzman reaction".¹²

The local Shwartzman reaction is elicitable by various mediators. At a minimum, it involves preparation of a tissue by injection of a mediator to induce focal leukocyte accumulation, followed by a provocative step that involves systemic activation of intravascular coagulation.¹³ The reaction is classically produced in rabbits by two injections of endotoxin.¹² Endotoxin is derived from the cell wall of Gram-negative bacteria and is a natural substance to which animals and humans are repeatedly exposed. It has powerful effects on a whole panoply of host systems mediating inflammation and

From the Neurology Department, Naval Hospital (J.M.H.), the Uniformed Services University of the Health Sciences (J.M.H., A.S., G.F.), the Diving Medicine Department, Naval Medical Research Institute (A.J.D., P.M.K.), Bethesda, Maryland, the Department of Critical Care Medicine, Children's Hospital of Pittsburgh, Pittsburgh, Pennsylvania (P.M.K.), and the Department of Neuropathology, Armed Forces Institute of Pathology, Washington, DC (G.H.P.).

Supported by the Naval Medical Research and Development Command Work Unit No. MR04101.1126.

The opinions and assertions contained herein are the private ones of the authors and are not to be construed as official or reflecting the views of the Navy Department or the United States naval service at large. This manuscript was prepared by United States government employees as part of their official duties and, therefore, cannot be copyrighted and may be copied without restriction.

Address for correspondence: J.M. Hallenbeck, Neurology Department, Naval Hospital, Naval Medical Command, National Capital Region, Bethesda, MD 20814-5055.

Received September 25, 1987; accepted January 6, 1988.

TABLE 1. Types of Rats Studied

Rats	Age	Stroke risk factor
<i>With risk factors for stroke</i>		
Spontaneously hypertensive	14–16 wk	Hypertension
Streptozotocin-treated Sprague-Dawley	14–16 wk	Diabetes
Aged Sprague-Dawley	24 mo	Advanced age
Stroke-prone spontaneously hypertensive	14–16 wk	Genetically prone to stroke
Spontaneously hypertensive retired breeders	11 mo	Protracted hypertension
<i>Control</i>		
Sprague-Dawley	14–16 wk	None
Wistar	14–16 wk	None

hemostasis,¹⁴ and its toxicity to tissue is primarily indirect via the induction of inflammatory cytokines.^{15,16} The Shwartzman reaction in rats is virtually impossible to produce by the classical, two-step injection of endotoxin.¹⁷ Instead, a modified Shwartzman reaction is generally produced by a single injection of endotoxin in a rat made vulnerable by the presence of an altered state such as pregnancy, diabetes, or hyperlipemia. A single intradermal injection in rabbits rendered vulnerable by prior administration of cortisone, thorotrast, or trypan blue can also produce a modified local Shwartzman reaction.¹⁸

This series of experiments was conducted to determine whether several established risk factors for stroke could prepare brain tissue locally so that a single injection of endotoxin would produce a modified local Shwartzman reaction.

Materials and Methods

The following rats with stroke risk factors were studied as outlined in Table 1: 14–16-week-old spontaneously hypertensive rats (SHR) (Charles River Laboratories, Inc., Raleigh, North Carolina), 14–16-week-old Sprague-Dawley (SD) rats (Taconic Farms, Inc., Germantown, New York) rendered diabetic by treatment with streptozotocin, 24-month-old aged SD rats (Harlan S-D, Indianapolis, Indiana), 14–16-week-old stroke-prone spontaneously hypertensive rats (SHR-SP) (Dr. M. Diolulu, NHLBI, NIH), and 11-month-old retired breeder SHR (Charles River). The control rats without stroke risk factors were 14–16-week-old SD (Taconic Farms) and 14–16-week-old Wistar rats (Charles River). The mean arterial blood pressure (MABP) of SHR was 155 ± 7 mm Hg, of SHR-SP 178 ± 10 mm Hg, and of normotensive rats 109 ± 3 mm Hg.

SD rats (290–320 g) to be rendered diabetic were treated with 65 mg/kg i.p. streptozotocin on Days 1 and 8 according to the technique of Campos et al.²⁰ The SD rats' weights, water consumption, and blood glucose levels were monitored until the glucose levels exceeded 400 mg% (usually within 14 days). The SD rats were kept for another 14 days with blood glucose levels of >400 mg% before intracisternal injections as described below.

Rats were anesthetized with halothane, and PE-50 catheters were inserted into the right jugular vein and the right carotid artery through a midcervical incision. The catheters were later tunneled under the skin to exit at the nape, where they were further secured by an adhesive collar and spring wire as previously described.¹⁹ The rats were placed on a stereotactic device, and a midline incision was made from the occiput to cervical vertebrae C1–C2. The muscles of the back of the neck were separated by blunt dissection, and the atlanto-occipital membrane was exposed. A total volume of 10 μ l of either *Escherichia coli* 0111:B4 lipopolysaccharide phenol extract (endotoxin) (Sigma Chemical Co., St. Louis, Missouri) dissolved in distilled water or water alone was injected into the cisterna magna with a Hamilton syringe attached to a needle fitted with a guard to prevent penetration of more than the 500- μ m tip. The needle was inserted through the membrane and stabilized at a depth of 500 μ m by a micromanipulator. After aspiration of clear cerebrospinal fluid (CSF) confirmed proper placement, endotoxin or water was injected over 10 minutes. An additional 2 minutes were allowed for dispersal of the injected fluid before withdrawal of the needle; inspection for bleeding preceded closure of the surgical sites. The rats were then allowed to recover from anesthesia in individual cages with food and water ad libitum.

Prior to the intracisternal injection of endotoxin or water, all rats underwent a baseline neurologic examination derived from the method of Tupper and Wallace.²¹ Based on observed deficits, the functional grade was assessed: Grade 0, normal rat; Grade 1, lethargy, no signs of paresis, spontaneous movements clearly reduced; Grade 2, clear signs of paresis in at least one limb but able to walk; Grade 3, severe paresis/paralysis, unable to walk; Grade 4, dead. The rats were examined again 24 hours after the intracisternal injection of endotoxin or water. Differences between groups were determined by means of χ^2 and Fisher's exact probability tests.

After the intracisternal injection of endotoxin or water, selected rats were given 80 mg/kg pentobarbital i.v. or i.p. before exposing the heart for perfusion fixation. A 16-gauge blunted needle was inserted into the left ventricle, and the right atrium

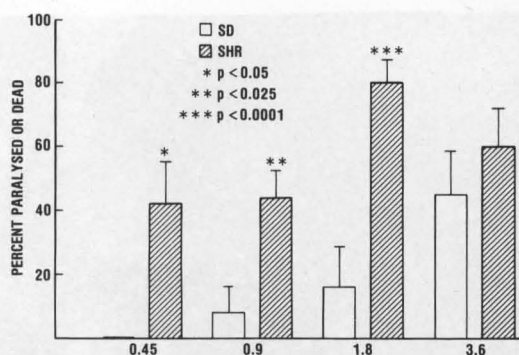


FIGURE 1. Dose-response histograms for intracisternal endotoxin in normal Sprague-Dawley rats (SD) and spontaneously hypertensive rats (SHR) with the stroke risk factor hypertension. Abscissa indicates intracisternal dose in mg/kg. At each dose level, *n* for SD and SHR were 8, 14 (0.45); 12, 27 (0.9); 37, 26 (1.8); and 13, 15 (3.6); respectively. Bars designate standard errors of the mean percentage.

was cut. The rat first received 500–600 ml normal saline perfused through a gravity-fed apparatus at a hydrostatic pressure of 145 mm Hg. Subsequently, 500 ml of 10% buffered formalin were infused to achieve fixation. Rats were stored overnight at 4° C, and the brain and upper spinal cord were removed. The brains were sectioned grossly at the medulla, at the junction of the mesencephalon and the hemispheres, and at the middle of the forebrain. These blocks were processed by standard techniques for light microscopy.

In parallel studies, SD rats and SHR were exposed to the above protocol, except that 1.8 mg/kg endotoxin was infused intravenously instead of intracisternally. Blood pressure was primarily measured in some of these rats, and neurologic functional grade was assessed in others.

The experiments reported herein were conducted according to the principles set forth in the *Guide for the Care and Use of Laboratory Animals, Institute of Laboratory Animal Resources* [National Research Council, Department of Health and Human Services, Pub. No. (NIH)85–23].

Results

As shown in Figure 1, SHR with the stroke risk factor hypertension were more vulnerable to paralysis or death with a single intracisternal dose of endotoxin than SD rats with no known stroke risk factors. This increased vulnerability was maintained through most of the doses ranging from 0.45 to 3.60 mg/kg. All moribund states and observed progressions to death involved a profound and obvious paralysis; therefore, death was attributed to neuraxis damage affecting primarily the brainstem rather than to endotoxin shock and was included with paralysis as a positive response. This interpretation, that death was a direct result of brainstem damage, was supported by several lines

of evidence. In moribund rats, microscopic pathology revealed hemorrhagic and pale infarcts in the medulla and pons with preservation of the cerebellar Purkinje cells, a cell type that would have exhibited selective vulnerability if the global ischemia associated with shock had occurred (Figure 2). In parallel studies, in which 1.8 mg/kg i.v. endotoxin depressed MABP to 90 mm Hg in SD rats (*n*=9) and to 95 mm Hg in SHR (*n*=11), this minimum, which occurred about 1 hour after the injection of endotoxin, exceeded shock levels by a considerable margin and was followed by a steady climb toward baseline values. Also, MABP measured in several moribund rats was in the normal range, thus eliminating shock as the cause for each such rat's death. Finally, the histopathology of shock organs such as lungs, kidneys, and small bowel was found to be normal in moribund rats (Figure 3).

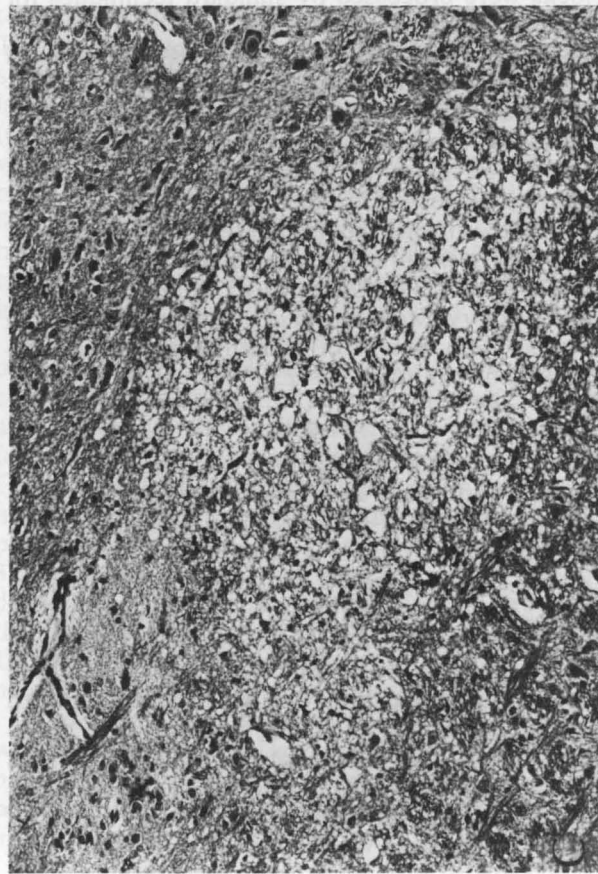
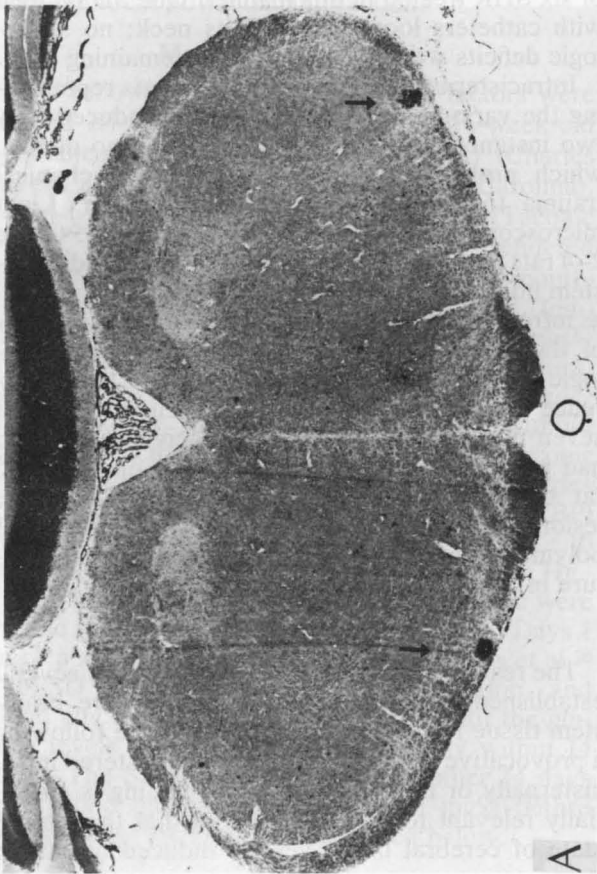
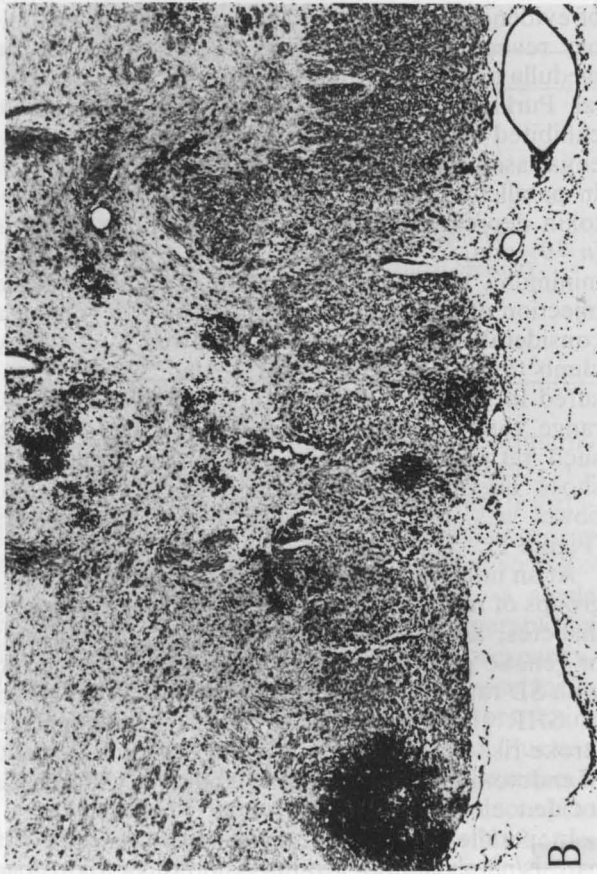
At an intracisternal endotoxin dose of 1.8 mg/kg, groups of rats with other stroke risk factors such as diabetes, advanced age, protracted hypertension, or genetic predisposition to stroke were compared with SD rats and Wistar rats, which are progenitors of SHR (Figure 4). All groups with recognized stroke risk factors reacted to the provocative dose of endotoxin by developing a significantly increased incidence of paralysis.

In parallel studies, 12 rats were assessed for paresis/paralysis after an intravenous endotoxin dose of 1.8 mg/kg. Grade 2–3 deficits were noted in five of six SHR treated in this manner. One SD rat died with catheters looped around its neck; no neurologic deficits were observed in the remaining five.

Intracisternal water injection in 40 rats representing the various groups under study produced only two instances of neurologic deficit and no deaths, which probably reflects the risk for mechanical trauma to the brainstem during injection. Light microscopic analysis of brain sections from 15 Grade 2–4 rats that had received endotoxin revealed brainstem infarcts as mentioned above (Figure 2) as well as infrequent small infarcts in gray and white matter of the forebrain. The correlation between neurologic impairment or moribund state and the occurrence of brainstem lesions was excellent. None of seven unaffected rats that had received endotoxin had parenchymal lesions, and all but one affected rat that had received endotoxin had identifiable lesions in the brainstem. A meningeal infiltrate of polymorphonuclear leukocytes was a constant feature in rats that had received endotoxin.

Discussion

The results of our study demonstrate that several established risk factors for stroke prepare brainstem tissue for ischemia and hemorrhage following a provocative dose of endotoxin administered intracisternally or intravenously. This finding is potentially relevant to human stroke in that the altered state of cerebral blood vessels induced by stroke



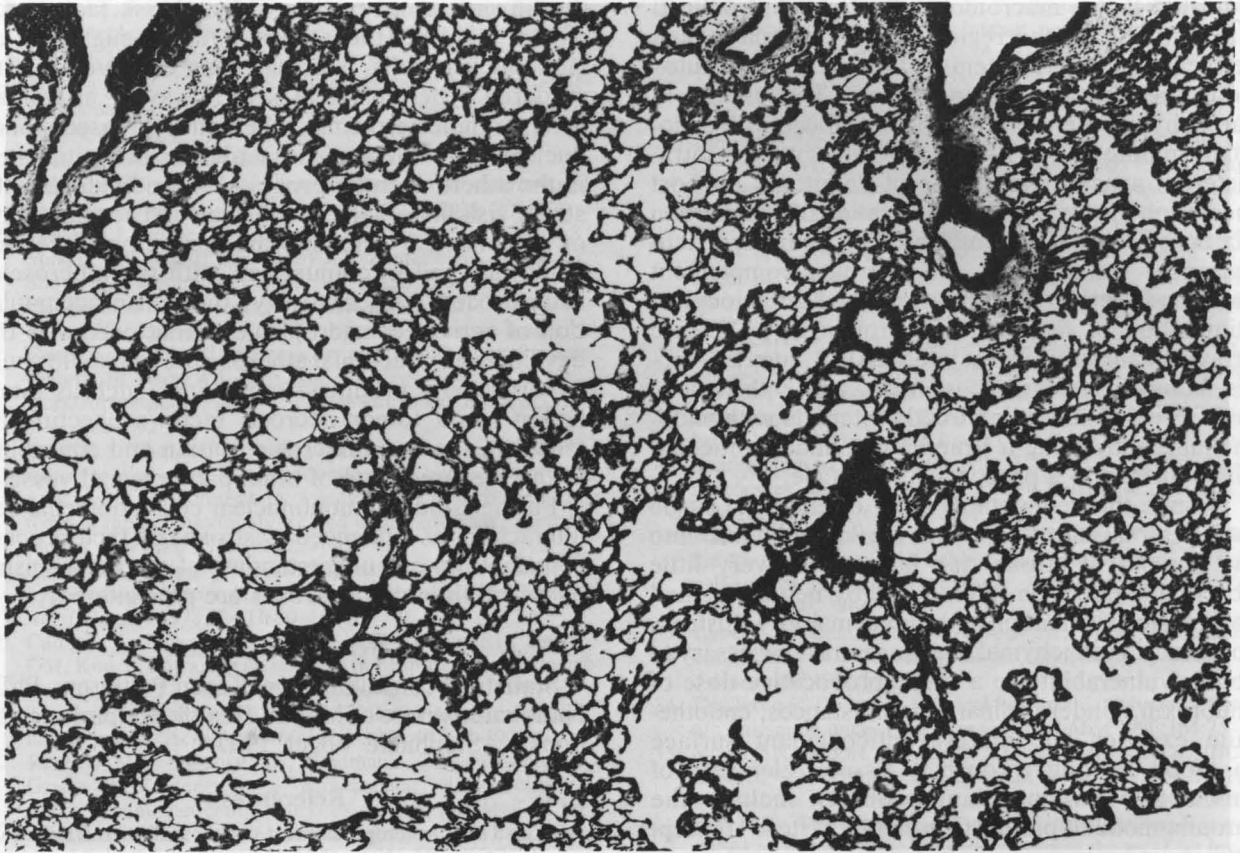


FIGURE 3. Rat lung. Bronchoalveolar system and blood vessels are normal. Note absence of hyaline membrane formation in this moribund rat. Hematoxylin and eosin stain, $\times 60$.

risk factors could render such vessels locally vulnerable to thrombosis or hemorrhage in response to transient activation of intravascular coagulation by any of a wide variety of mechanisms. The site of thrombus formation would be determined by the preexisting vessel disturbance and not by the process activating intravascular coagulation, thereby following the local Shwartzman reaction paradigm. In this view, stroke would develop as the focal consequence of disturbed regulation of systems mediating coagulation, inflammation, and immunity, which are normally required for preservation of the integrity of the organism. Endotoxin injection in our study served to unmask the prepared state of the parenchymal vasculature in rats with stroke risk factors.

FIGURE 2. A: Section through midbrain shows multiple petechial hemorrhages (arrows) in white matter. Hematoxylin and eosin stain, $\times 9.1$. B: Higher magnification reveals gray and white matter hemorrhage and marked basal meningitis. In addition, periventricular pallor and edema are noted. Hematoxylin and eosin stain, $\times 31.5$. C: In midbrain tegmentum, multiple areas of infarction and edema are seen. Hematoxylin and eosin stain, $\times 84$. D: Section from cerebellar cortex shows normal Purkinje cells and indicates lack of systemic anoxic-ischemic changes. Hematoxylin and eosin stain, $\times 57.4$.

Our findings can be interpreted within the context of endotoxin's effects on host mediation systems and the evolving understanding of the endothelium's role as a local regulator of hemostasis. Studies revealing a paravascular circulation of CSF have

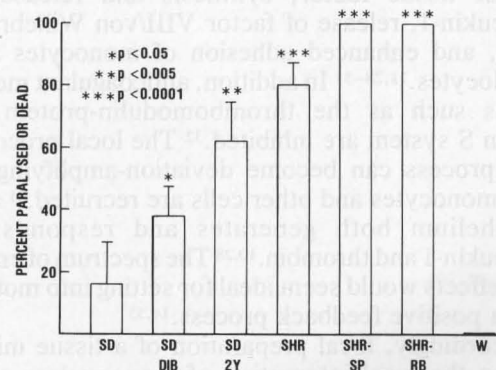


FIGURE 4. Responses to single 1.8 mg/kg intracisternal dose of endotoxin are compared from groups of rats with and without stroke risk factors. For each group, n is Sprague-Dawley rats (SD) 37, SD diabetic (SD DIB) 26, SD 24 months old (SD 2Y) 13, spontaneously hypertensive rats (SHR) 26, stroke-prone spontaneously hypertensive rats (SHR-SP) 4, SHR retired breeder rats (SHR-RB) 4, Wistar rats (W) 7. Bars designate standard errors of the mean percentage.

indicated that a macromolecular tracer introduced into the CSF in the region of the cisterna magna permeates the brainstem within several minutes along the Virchow-Robin space.²² The brainstem parenchyma, therefore, should be imbued with endotoxin minutes after its introduction into the intracisternal space. The effects of endotoxin on host mediation systems include activation of coagulation via both the extrinsic and intrinsic pathways; activation of the classical and alternate complement pathways; activation of platelets and granulocytes; stimulation of monocytes/macrophages to release procoagulant substances, interleukin-1, tumor necrosis factor/cachectin, eicosanoids, and collagenase; and further, endotoxin directly interacts with endothelium, converting it from an essentially anticoagulant surface to a procoagulant surface.¹⁴

Despite this redoubtable array of effects, a single intracisternal injection of 1.8 mg/kg endotoxin into rats devoid of stroke risk factors had very little observable effect on brain tissue by neurologic and pathologic examination in the great majority. Instead, some local parenchymal change seemed necessary to confer vulnerability to a single provocative dose of endotoxin. Under ordinary circumstances, endothelium exposes an actively anticoagulant surface to blood flowing through a tissue. Elements of this active anticoagulant property include the thrombomodulin-protein C-protein S system²³ (except perhaps in brain microcirculation²⁴), heparinlike molecules on the luminal surface that bind antithrombin III,²⁵ synthesis and release of prostacyclin (PGI₂),²⁶ and synthesis and release of tissue plasminogen activator.²⁷ Under the influence of polypeptide and protein mediators such as interleukin-1, tumor necrosis factor/cachectin, and thrombin,^{10,28} this property undergoes a local reversal and the affected endothelium becomes an actively procoagulant surface. Specific changes include synthesis and surface expression of tissue factor, synthesis and release of interleukin-1, release of factor VIII/von Willebrand factor, and enhanced adhesion of monocytes and granulocytes.^{11,28-31} In addition, anticoagulant mechanisms such as the thrombomodulin-protein C-protein S system are inhibited.³² The local procoagulant process can become deviation-amplifying as more monocytes and other cells are recruited,³¹ and endothelium both generates and responds to interleukin-1 and thrombin.^{10,28} The spectrum of endotoxin effects would seem ideal for setting into motion such a positive feedback process.^{14,33}

Accordingly, local preparation of a tissue might involve the local interaction of mononuclear cells and endothelium. The marked susceptibility of athymic nude mice to the Shwartzman reaction has been attributed to the heightened activity of their mononuclear cells³⁴; mononuclear cell activation caused by BCG immunization produced an enhanced sensitivity to endotoxin in normally resistant C3H/HeJ mice.³⁵ These studies indicate that mononuclear cell activation is associated with increased sensitivity to

the Shwartzman reaction. Several risk factors for stroke increase the adhesion and emigration of mononuclear cells. This has been observed in rats rendered hypertensive in several ways,³⁶ as well as in hypercholesterolemia, where the increased mononuclear cell adhesion is regarded as the initial step in the atherosclerotic process.³⁷ In individuals with stroke risk factors, local adhesion and accumulation of mononuclear cells in brain parenchymal vessels could proceed in conjunction with the atherosclerotic process. Alternatively, the dense accumulation of activated macrophages³⁸ that occurs in the developing extracranial atherosclerotic plaque could export locally produced monokines such as interleukin-1 and tumor necrosis factor/cachectin distally into the brain microcirculation and contribute to the prepared state of brain parenchymal vessels.

Further study of mononuclear cell/endothelial cell interactions as influenced by stroke risk factors could contribute to our understanding of the mechanisms by which thrombotic strokes are precipitated.

Acknowledgments

Statistical consultation by Karen Pettigrew, PhD, National Institute of Mental Health. Helpful suggestions by Stephanie Vogel, PhD.

References

1. Yatsu FM: Atherogenesis and stroke, in Barnett HJM, Mohr JP, Stein BM, Yatsu FM (eds): *Stroke Pathophysiology, Diagnosis and Management*. New York, Churchill Livingstone, 1983, vol 1, pp 45-56
2. Barnett HJM: Pathogenesis of transient ischemic attacks, in Scheinberg P (ed): *Cerebrovascular Disease; Tenth Princeton Conference*. New York, Raven Press, 1976, pp 1-21
3. Castaigne P, Lhermitte F, Gautier JC, Escourolle R, Derouesne C: Internal carotid artery occlusion. A study of 61 instances in 50 patients with post mortem data. *Brain* 1970;93:231-258
4. Skinhoj E, Hoedt-Rasmussen K, Paulson OB, Lassen NA: Regional cerebral blood flow and its autoregulation in patients with transient focal cerebral ischemic attacks. *Neurology* 1970;20:485-493
5. Busuttill RW, Baker JD, Davidson RK, Machleder HI: Carotid artery stenosis—Hemodynamic significance and clinical course. *JAMA* 1981;245:1438-1441
6. Chambers BR, Norris JW: The case against surgery for asymptomatic carotid stenosis. *Stroke* 1984;15:964-967
7. Grotta JC, Bigelow RH, Hu H, Hankins L, Fields WS: The significance of carotid stenosis or ulceration. *Neurology* 1984;34:437-442
8. Harrison MJG, Marshall J: Prognostic significance of severity of carotid atheroma in early manifestations of cerebrovascular disease. *Stroke* 1982;13:567-569
9. Powers WJ, Siegel BA, Davis HH, Mathias CJ, Clarke HB, Welch MJ: Indium-111 platelet scintigraphy in cerebrovascular disease. *Neurology* (NY) 1982;32:938-943
10. Brox JH, Osterud B, Bjorklid E, Fenton JW II: Production and availability of thromboplastin in endothelial cells: The effects of thrombin, endotoxin and platelets. *Br J Haematol* 1984;57:239-246
11. Bevilacqua MP, Pober JS, Majeau GR, Cotran RS, Gimbrone MA Jr: Interleukin 1 (IL-1) induces biosynthesis and cell surface expression of procoagulant activity in human vascular endothelial cells. *J Exp Med* 1984;160:618-623
12. Shwartzman G: Studies on *Bacillus typhosus* toxic substances—I. Phenomenon of local skin reactivity to *B. typhosus* culture filtrate. *J Exp Med* 1928;48:247-268

13. Hjort PF, Rapaport SI: The Shwartzman reaction: Pathogenic mechanisms and clinical manifestations. *Ann Rev Med* 1965;16:135-168
14. Morrison DC, Ulevitch RJ: The effects of bacterial endotoxins on host mediation systems—A review. *Am J Pathol* 1978;93:527-617
15. Beck G, Habicht GS, Benach JL, Miller F: Interleukin 1: A common endogenous mediator of inflammation and the local Shwartzman reaction. *J Immunol* 1986;136:3025-3031
16. Tracey KJ, Beutler B, Lowry SF, Merryweather J, Wolpe S, Milsark IW, Hariri RJ, Fahey TJ, Zentella A, Albert JD, Shires GT, Cerami A: Shock and tissue injury induced by recombinant human cachectin. *Science* 1986;234:470-474
17. Movat HZ, Burrows CE: The local Shwartzman reaction: Endotoxin-mediated inflammatory and thrombo-hemorrhagic lesions, in Berry LJ (ed): *Handbook of Endotoxin*. New York/Amsterdam, Elsevier Science Publishers BV, 1985, vol 3, pp 260-302
18. Good RA, Thomas L: Studies on the generalized Shwartzman reaction—II. The production of bilateral cortical necrosis of the kidneys by a single injection of bacterial toxin in rabbits previously treated with thorotrast or trypan blue. *J Exp Med* 1952;96:625-641
19. Chiueh CC, Kopin IJ: Hyperresponsivity of spontaneously hypertensive rat to indirect measurement of blood pressure. *Am J Physiol* 1978;234:H690-H695
20. Campos A, Mauer MS, Michael AF, Vernier RL, Brown DM, Kim Y: Shwartzman reaction in streptozotocin-induced diabetic rats. *Lab Invest* 1984;50:565-570
21. Tupper DE, Wallace RB: Utility of the neurological examination in rats. *Acta Neurobiol Exp* 1980;40:999-1003
22. Rennels ML, Gregory TF, Blaumanis OR, Fujimoto K, Grady PA: Evidence for a "paravascular" fluid circulation in the mammalian central nervous system, provided by the rapid distribution of tracer protein throughout the brain from the subarachnoid space. *Brain Res* 1985;326:47-63
23. Clous LH, Comp PC: The regulation of hemostasis: The protein C system. *N Engl J Med* 1986;314:1298-1304
24. Ishii H, Salem HH, Bell CE, Laposata EA, Majerus PW: Thrombomodulin, an endothelial anticoagulant protein, is absent from the human brain. *Blood* 1986;67:362-365
25. Stern DM, Nawroth P, Marcum J, Handley D, Kiesel W, Rosenberg R, Stern K: Interaction of antithrombin III with bovine aortic segments—Role of heparin in binding and enhanced anticoagulant activity. *J Clin Invest* 1985;75:272-279
26. Weksler B, Marcus A, Jaffe E: Synthesis of prostaglandin I₂ (prostacyclin) by cultured human and bovine endothelial cells. *Proc Natl Acad Sci USA* 1977;74:3922-3926
27. Loskutoff D, Edgington T: Synthesis of a fibrinolytic activator and inhibitor by endothelial cells. *Proc Natl Acad Sci USA* 1977;74:3903-3907
28. Libby P, Ordovas JM, Auger KR, Robbins AH, Birinyi LK, Dinarello CA: Endotoxin and tumor necrosis factor induce interleukin-1 gene expression in adult human vascular endothelial cells. *Am J Pathol* 1986;124:179-185
29. Loesberg C, Gonsalves MD, Zandbergen J, Willems C, van Aken WG, Stel HV, van Mourik JA, De Groot PG: The effect of calcium on the secretion of Factor VIII-related antigen by cultured human endothelial cells. *Biochem Biophys Acta* 1983;763:160-168
30. Levine JD, Harlan JM, Harker LA, Joseph ML, Counts RB: Thrombin-mediated release of Factor VIII antigen from human umbilical vein endothelial cells in culture. *Blood* 1982;60:531-534
31. Bevilacqua MP, Pober JS, Wheeler ME, Cotran RS, Gimbrone MA Jr: Interleukin 1 acts on cultured human vascular endothelium to increase the adhesion of polymorphonuclear leukocytes, monocytes, and related leukocyte cell lines. *J Clin Invest* 1985;76:2003-2011
32. Nawroth PP, Handley DA, Esmon CT, Stern DM: Interleukin 1 induces endothelial cell procoagulant while suppressing cell-surface anticoagulant activity. *Proc Natl Acad Sci USA* 1986;83:3460-3464
33. Lyberg T, Galdal KS, Evenson SA, Prydz H: Cellular cooperation in endothelial cell thromboplastin synthesis. *Br J Haematol* 1983;53:85-95
34. DeClercq E, DeSomer P: Local Shwartzman phenomenon in athymic nude mice. *Proc Soc Exp Biol Med* 1980;164:75-81
35. Vogel SN, Moore RN, Sipe JD, Rosenstreich DL: BCG-induced enhancement of endotoxin sensitivity in C3H/HeJ mice—I. *In vivo* studies. *J Immunol* 1980;124:2004-2009
36. Still WJS: The pathogenesis of the intimal thickenings produced by hypertension in large arteries in the rat. *Lab Invest* 1968;19:84-91
37. Joris I, Zand T, Nunnari JJ, Krolkowski FJ, Majno G: Studies on the pathogenesis of atherosclerosis—I. Adhesion and emigration of mononuclear cells in the aorta of hypercholesterolemic rats. *Am J Pathol* 1983;113:341-358
38. Ross R: The pathogenesis of atherosclerosis—an update. *N Engl J Med* 1986;314:488-500

KEY WORDS • Shwartzman phenomenon • cerebrovascular disorders • risk factors • blood coagulation • rats