

This is an Open Access article licensed under the terms of the Creative Commons Attribution-NonCommercial-NoDerivs 3.0 License (www.karger.com/OA-license), applicable to the online version of the article only. Distribution for non-commercial purposes only.

Human Tuberculous Meningitis Caused by *Mycobacterium caprae*

Niels Hansen^a Carola Seiler^a Julian Rumpf^a
Peter Kraft^a Henry Dlaske^a Marianne Abele-Horn^b
Wolfgang Muellges^a

^aDepartment of Neurology and ^bInstitute of Hygiene and Microbiology,
University Hospital of Wuerzburg, Wuerzburg, Germany

Key Words

Tuberculous meningitis · *Mycobacterium tuberculosis* complex · *Mycobacterium caprae* · Cerebrospinal fluid culture · Fosfomycin

Abstract

Introduction: Tuberculous meningitis (TM) causes substantial morbidity and mortality in humans. Human TM has been known to be induced by bacteria from the *Mycobacterium tuberculosis* complex (MTBC), such as *M. tuberculosis* and *M. bovis*.

Case Presentation: We describe a case of meningitis treated with fosfomycin, which showed partial effectiveness in an 80-year-old patient. After a lethal myocardial infarction, *M. caprae* (MC) was identified in cerebrospinal fluid culture. This isolated acid-fast organism was first identified as MTBC by MTBC-specific PCR (16S rDNA-PCR). Furthermore, species-specific identification of the isolate was done by *gyrB* PCR-restriction fragment length polymorphism analysis of a part of *gyrB* DNA. Colony morphology of the isolated MC strain showed dysgonic growth on Lowenstein-Jensen medium. The strain was susceptible to pyrazinamide (PZA).

Conclusion: This isolated strain was convincingly identified as MC according to the phenotypic and genotypic characteristics and PZA sensitivity. This is the first report of MC causing TM.

Introduction

In tuberculous meningitis (TM), *Mycobacterium tuberculosis* and, more rarely, *M. bovis* (MB), formerly known as *M. bovis* ssp. *bovis* [1], have been reported as pathogens. Clinically, TM should be suspected in patients presenting a progressive, subacute illness with headache, meningism, cranial-nerve involvement and hydrocephalus development

potentially leading to stupor and coma. Diagnosis depends on cerebrospinal fluid (CSF) analysis typically revealing predominantly lymphocytic pleocytosis, high protein content, low glucose and high lactate. The definitive diagnosis of TM relies on CSF cultures that take at least 6 weeks [2] to develop, which is why tuberculostatic therapy is almost always started before the definitive diagnosis has been made.

Here, we present a patient with TM which, in postmortem analysis, turned out to have been caused by *M. caprae* (MC), a member of the *M. tuberculosis* complex (MTBC) including *M. tuberculosis*, *M. africanum*, *MB*, *M. canetti*, *M. microti*, *M. pinnipedia* and *M. pinnipedia* sp. nov.

Case Report

An 80-year-old man, without an agricultural background and with a history of fully remitted prostate cancer, hypernephroma 15 years before and a coronary artery bypass graft 6 years previously, was admitted to a tertiary care hospital for a subacute gait disorder suspicious for non-pressure hydrocephalus, and slight disorientation. Two non-contrast MRI brain scans were incomplete because of psychomotor unsteadiness. However, they revealed brain atrophy, an internal hydrocephalus and relevant cerebral microangiopathy (fig. 1). CSF revealed a lymphomonocytic pleocytosis [high leukocyte count of 1,089/mm³ (reference value 0–3), and elevated protein of 1,040 mg/dl (reference value <50)]. Serology, microscopy and CSF culture did not reveal bacteria, thus excluding more rare pathogens like *Listeria*, *Brucella*, *Leptospira*, *Rickettsia* and *Tropheryma*, fungi such as cryptococci, and neurotropic viruses including HIV. Having diagnosed meningitis of unknown origin, standard first-line antibiotic treatment with ceftriaxone and ampicillin was introduced. As the patient failed to improve within 22 days, he was transferred to our hospital because of a progressive loss of consciousness together with meningeal signs.

Brain CT did not reveal new information. CSF again showed a high cell count of 1,080/mm³, with 31% neutrophils and 56% lymphocytes (fig. 2a), low glucose (48 mg/dl, with serum glucose 180 mg/dl), high protein content (339 mg/dl), and high lactate [6.1 mmol/l (reference value 1.2–2.1)]. CSF pressure was elevated to 25 cm H₂O. Again, no bacteria were detected, and Ziehl-Neelsen's stain was negative for *Mycobacterium*. Antibiotics were switched to meropenem plus ampicillin and, with TM included in the differential diagnosis, to a combination of rifampicin (450 mg i.v./day), isoniazid (300 mg p.o./day), pyrazinamide (3 g p.o. 2 times/week) and ciprofloxacin (500 mg p.o./day). PCR detected no DNA of MC. During the days thereafter, triple analysis of bronchial secretions, urine and gastric lavage were all negative for *Mycobacterium*. Chest X-ray and abdominal sonography were also unremarkable.

For the next 3 days, CSF pressure dropped to 19 cm H₂O as a result of daily spinal taps. The patient's condition improved. On the fifth day, he developed Lyell's syndrome with a generalized rash and bullous exanthema leading to allergic shock which had to be treated with catecholamines (time course of C-reactive protein (CRP) and leukocyte cell count data in serum, fig. 2b). As antituberculous may often cause such an event, and TM was not definitive, these drugs were stopped, and fosfomycin was initiated as a broad-spectrum antibiotic therapy for bacterial meningitis (3 × 3 g i.v./day). Additionally, glucocorticoids and antihistamines were given for a total of 10 days. Within 2 weeks of treatment accompanied by several lumbar punctures to reduce CSF pressure, which indeed did not exceed 20 cm H₂O, the patient recovered to cooperativeness. He refused a leptomeningeal biopsy to look for tuberculous granulomas. Within 14 days, the CSF leukocyte cell count dropped to 68/mm³ as revealed by a lymphocytic cell picture, and the protein content fell to 55.9 mg/dl; CRP and serum white cell count decreased to reference values (fig. 2b).

After 29 days, the patient was transferred to a rehabilitation center, where fosfomycin was discontinued. Over the next 2 weeks, his condition deteriorated, presenting progressive immobility, headache and somnolence. Due to his recently completed advance directive, neither a spinal tap nor antibiotic therapy was provided. Unfortunately, the patient died suddenly from an acute myocardial infarction. Autopsy was refused.

Two weeks after death, CSF cultures for mycobacteria demonstrated growth in the broth-based MGIT 960 system (Becton Dickinson Microbiology System, Heidelberg, Germany). The isolated acid-fast organism was identified as MTBC by MTBC-specific PCR (16S rDNA-PCR). Species-specific identification of the isolate was performed by *gyrB* PCR-restriction fragment length polymorphism (RFLP) analysis of a part of *gyrB* DNA [3, 4]. This method consists of *gyrB* DNA amplification of the isolated MTBC, subsequent to the electrophoretic separation of the amplified products and finally of the 16S rDNA sequencing of a specific DNA 1,020-bp fragment. Differences in the *gyrB* sequences allow accurate discrimination of the MTBC and the species-specific identification of *M. tuberculosis*, *M. microti*, *M. africanum* 1, *MB* and last, but not least, *MC*. Colony morphology of the isolated *MC* strain showed dysgonic growth on Lowenstein-Jensen (LJ) medium. The strain was susceptible to pyrazinamide (PZA) (100 µg/ml).

Discussion

Clearly, our patient was suffering from meningitis due to uncommon bacteria not identified by a broad battery of tests, and first-line antibiotics did not influence the course at all. We thus suspected TM on clinical grounds, based on the ineffectiveness of ceftriaxone plus ampicillin, hydrocephalus, a subchronic course, and compatible laboratory and CSF findings [5]. Antituberculotics unfortunately had to be stopped after 3 days because of life-threatening Lyell's syndrome. Because TM had not yet been settled, fosfomycin was introduced as a broad-spectrum alternative for bacterial meningitis, and the patient gradually improved clinically within a 3-week period, as did CSF and inflammation parameters. After the cessation of fosfomycin, the patient deteriorated again, supporting at least a partial effectiveness of fosfomycin. Unfortunately, the patient died from an unrelated cause.

Surprisingly, postmortem *MC*, a member of the MTBC, was detected in CSF cultures, which highlights that time-consuming culture is more sensitive than Ziehl-Neelsen staining and PCR for MTBC. However, *MC* has never been reported to cause human TM. *MC* has been shown to induce pulmonary and extrapulmonary manifestations of human tuberculosis [6], lupus vulgaris [7] and pericarditis [8] (table 1). The close relationship between *MC* and particularly *MB* makes their species-specific identification difficult. In general, routine differentiation of MTBC is based on a number of phenotype characteristics and biochemical tests. *MC* and *MB* show 'dysgonic growth' on LJ medium, which means they have difficulty growing and are negative for nitrate reduction and niacin accumulation. The only criterion for their discrimination is *MB*'s intrinsic resistance to PZA and *MC*'s susceptibility to PZA. However, as PZA-susceptible subspecies of *MB* have very recently been reported [9], both species can be reliably identified using molecular biology techniques only. Of these techniques, the PCR-RFLP method used here proved useful for accurately differentiating *MB* from *MC*. This method is based on the amplification of a 1,020-bp fragment of the *gyrB* DNA from clinical isolates and on the detection of single nucleotide polymorphisms in the amplified *gyrB* sequences. Due to single nucleotide changes in their *gyrB* sequences, members of MTBC may be identified species specifically. In contrast to *M. tuberculosis*, *MC* and *MB* contain a specific adenine residue instead of a guanine residue in position 756 of the 1,020-bp DNA fragment. With respect to *MB*, *MC* contains a guanine residue instead of a thymidine residue in position 1311, and a cytosine residue rather than a thymidine residue in position 1410 on the *gyrB* gene. The phenotypic and genotypic characteristics together with PZA sensitivity suggest that the isolated strain was reliably identified as *MC*.

MC has been isolated mainly in Europe (e.g. Spain, Austria, the Czech Republic, and in the Balkans) from cattle, goat, horse, cat, dog, pig, ferret, red deer and wild boar [10–12]. Identification of isolates from human patients has revealed *MC* to be a human pathogen [6, 10, 11] that is probably transmitted to humans via contact with livestock [13]. A recent study from Spain detected *MC* in 0.3% of human tuberculosis [6], and *MC* caused a third of the human *MB*-associated tuberculosis cases reported between 1999 and 2001 in Germany [10]. In particular, a high regional difference in *MC*'s prevalence became apparent: more than 80% of the cases were detected in southern Germany, whereas less than 10% occurred in the northern parts of Germany [10]. Interestingly, our patient came from southern Germany.

Consumption of unpasteurized dairy products is often the source of infection, and that may also have been the case in our patient who had no close contact to animals. We can exclude accidental contamination, as *MC* has never been detected at the Institute of Microbiology before or since, and there have been no known cases of *MC* amongst our ICU personal. Altogether, though never reported before, there are plausible arguments supporting TM caused by *MC*.

The effectiveness of fosfomycin in *MC* TM may be assumed. Our patient's rapid initial clinical improvement was probably more likely due to lowering his elevated CSF pressure than to anti-inflammatory drug effects on meningitis; however, his further recovery, especially the improvement in CSF findings (fig. 2a, b), may be attributed to fosfomycin. A spontaneous improvement seems implausible, as TM is generally a progressive, fatal disease if treated inadequately. It also does not seem credible that a 3-day course of standard antituberculotics including PZA was responsible. After stopping fosfomycin, the patient's neurologic condition deteriorated again. This seems consistent, as standard antituberculous therapy in TM must be administered for several months. Thus, our patient's course suggests that fosfomycin may be at least somewhat therapeutically effective.

Conclusions

Clinical and laboratory data suggested TM in our patient. Based on its phenotypic and genotypic characteristics, we reliably identified the isolated strain of the CSF culture as *MC*. *MC* can therefore cause TM in humans. Furthermore, the clinical course was positively influenced by fosfomycin.

Disclosure Statement

None of the authors reports any conflict of interest. No financial support was received for this report.

Table 1. Clinical manifestations of human infections due to *MC*

Disease	Clinical manifestations	Geographical range	Age, years (n)	Source of infection	Reference
Lupus vulgaris	Right forehead, temple, cheek and earlobe Pulmonary tuberculosis	Bavaria, Germany	68 (1)	Infected milk products	7
Lupus vulgaris	Left side of the neck (20×30 mm), peripheral satellites	Turkey	33 (1)	Direct contact with dairy cattle	14
Tuberculosis	Pulmonary	Austria	39, 54, 66, 72 (4)	Farming area, stock animals	13
Tuberculosis	Pulmonary, cervical lymph node enlargement	Croatia	7, 13 (2)	Cattle dairy farm	15
Tuberculosis	Pulmonary, extrapulmonary (abdominal, cutaneous, urinary, bone, lymph node), unknown	Germany	0–90 (46)	Unknown	10
Tuberculosis	Pulmonary and extrapulmonary	Spain, Morocco, Algeria, Israel, Nigeria, Kenya, Peru	15–>65 (21)	Unknown	6
Tuberculosis	Pericarditis	Germany	76 (1)	Unknown	8

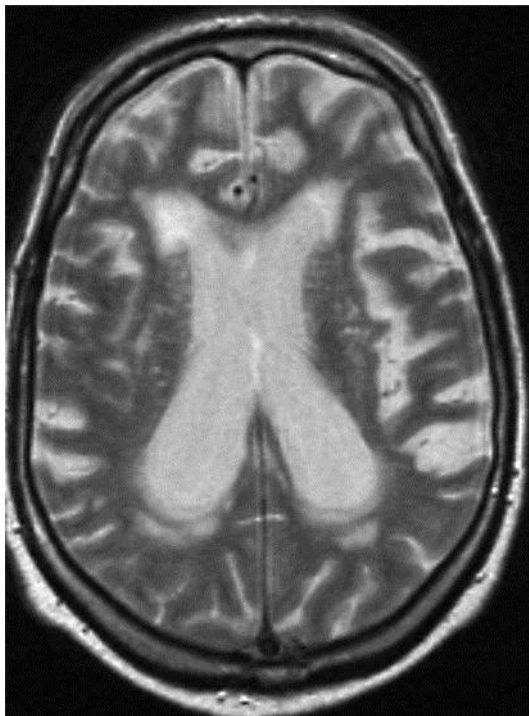

Fig. 1. Non-contrast MRI of the patient's brain shows slight atrophy, ventricular enlargement and cerebral microangiopathy.

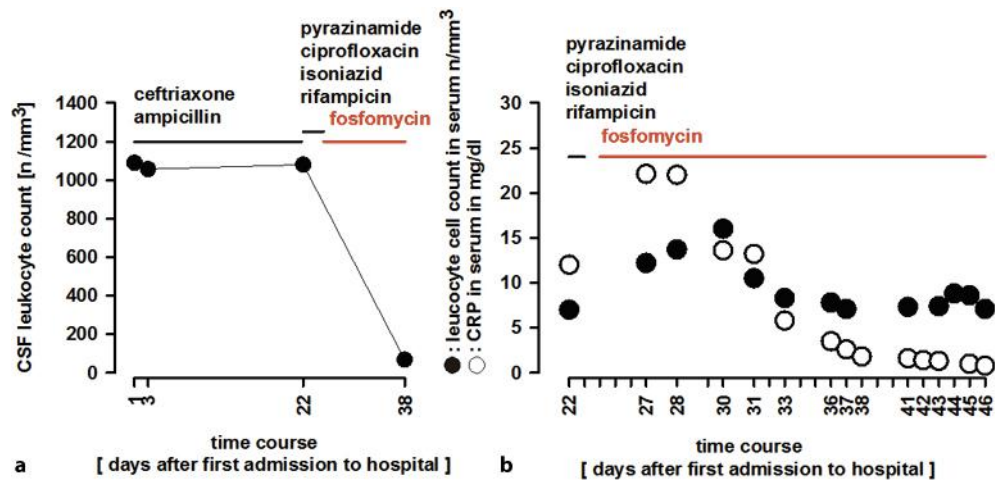


Fig. 2. Time course of leukocyte cell counts in CSF (a) and serum (b). The arbors illustrate the time interval of antibiotic therapy. Note the intermittent effect after fosfomycin therapy.

References

- Katti MK: Pathogenesis, diagnosis, treatment, and outcome aspects of cerebral tuberculosis. *Med Sci Monit* 2004;10:RA215–RA229.
- Thwaites GE, Caws M, Chau TT, Dung NT, Campbell JI, Phu NH, Hien TT, White NJ, Farrar JJ: Comparison of conventional bacteriology with nucleic acid amplification (amplified mycobacterium direct test) for diagnosis of tuberculous meningitis before and after inception of antituberculosis chemotherapy. *J Clin Microbiol* 2004;42:996–1002.
- Kasai H, Ezaki T, Harayama S: Differentiation of phylogenetically related slowly growing mycobacteria by their *gyrB* sequences. *J Clin Microbiol* 2000;38:301–308.
- Niemann S, Harmsen D, Rüsche-Gerdes S, Richter E: Differentiation of clinical *Mycobacterium tuberculosis* complex isolates by *gyrB* DNA sequence polymorphism analysis. *J Clin Microbiol* 2000;38:3231–3234.
- Thwaites GE, Chau TTH, Stepniewska K, Phu NH, Chuong LV, Sinh DX, White NJ, Parry CM, Farrar JJ: Diagnosis of adult tuberculous meningitis by use of clinical and laboratory features. *Lancet* 2002;360:1287–1292.
- Rodríguez E, Sánchez LP, Pérez S, Herrera L, Jiménez MS, Samper S, Iglesias MJ: Human tuberculosis due to *Mycobacterium bovis* and *M. caprae* in Spain, 2004–2007. *Int J Tuberc Lung Dis* 2009;13:1536–1541.
- Meyer S, Naumann I, Landthaler M, Vogt T: Lupus vulgaris caused by *Mycobacterium bovis* subspecies *caprae*. *Br J Dermatol* 2005;153:220–222.
- Blaas SH, Böhm S, Martin G, Erler W, Glück T, Lehn N, Naumann L: Pericarditis as primary manifestation of *Mycobacterium bovis* ssp. *caprae*. *Diagn Microbiol Infect Dis* 2003;47:431–433.
- Niemann S, Richter E, Rüsche-Gerdes S: Differentiation among members of the *Mycobacterium tuberculosis* complex by molecular and biochemical features: evidence of two pyrazinamide-susceptible subtypes of *M. bovis*. *J Clin Microbiol* 2000;38:152–257.
- Kubica T, Rüsche-Gerdes S, Niemann S: *Mycobacterium bovis* subsp. *caprae* caused one-third of human *M. bovis*-associated tuberculosis cases reported in Germany between 1999–2001. *J Clin Microbiol* 2003;41:3070–3077.
- Rodríguez E, Bezos J, Romero B, de Juan L, Alvarez J, Castellanos E, Moya N, Lozano F, Javed MT, Saez-Llorente JL, Liebana E, Mateos A, Domínguez L, Aranaz A; and the Spanish Network on Surveillance and Monitoring Animal Tuberculosis: *Mycobacterium caprae* infection in livestock and wildlife, Spain. *Emerg Infect Dis* 2011;17:532–535.
- Pavlik I, Dvorska L, Bartos M, Parmova I, Meliciarek I, Jesenka A, Havelkova M, Slosarek M, Putova I, Martin G, Erler W, Kremer K, Van Sooling D: Molecular epidemiology of bovine tuberculosis in the Czech Republic and Slovakia in the period 1965–2001 studied by spoligotyping. *Vet Med Czech* 2002;47:181–194.

- 13 Prodingner WM, Eigentler A, Allerberger F, Schonbauer M, Glawischnig W: Infection of red deer, cattle and humans with *Mycobacterium bovis* subsp. *caprae* in Western Austria. J Clin Microbiol. 2002;40:2270–2272.
- 14 Tar SY, Bozdemir B, Gurel MS, Bilgin FU, Baran MF, Demirkesen C: *Mycobacterium bovis caprae*: a rare agent of lupus vulgaris. Clin Exper Dermatol 2009;34:532–533.
- 15 Cvetnic Z, Katalinic-Jankovic V, Sostaric B, Spicic S, Obrovac M, Marjanovic S, Benic M, Kirin BK, Vickovic I: *Mycobacterium caprae* in cattle and humans in Croatia. Int J Tuberc Lung Dis 2007;11:652–658.