

Title Page

Title: Novel Structured Reporting Systems for Theranostic Radiotracers

Running Title: Reporting Systems for Theranostics PET

Authors: Rudolf A. Werner^{1,2,3}, Ralph A. Bundschuh⁴, Lena Bundschuh⁴, Stefano Fanti⁵, Mehrbod S. Javadi¹, Takahiro Higuchi^{2,6}, A. Weich^{3,7}, Kenneth J. Pienta⁸, Andreas K. Buck^{2,3}, Martin G. Pomper^{1,8}, Michael A. Gorin^{1,8}, Ken Herrmann^{9,10}, Constantin Lapa^{2,*}, Steven P. Rowe^{1,8,*}

* = Equally contributed

¹The Russell H. Morgan Department of Radiology and Radiological Science, Division of Nuclear Medicine and Molecular Imaging, Johns Hopkins University School of Medicine, Baltimore, MD, USA

²Department of Nuclear Medicine/Comprehensive Heart Failure Center, University Hospital Würzburg, Germany

³European Neuroendocrine Tumor Society (ENETS) Center of Excellence (CoE), NET Zentrum, University Hospital Würzburg, Germany

⁴Department of Nuclear Medicine, University Medical Center Bonn, Germany

⁵Nuclear Medicine Unit, University of Bologna, S. Orsola Hospital Bologna, Bologna, Italy

⁶Department of Bio Medical Imaging, National Cardiovascular and Cerebral Research Center, Suita, Japan

⁷Department of Internal Medicine II, Gastroenterology, University Hospital Würzburg, Germany

⁸The James Buchanan Brady Urological Institute and Department of Urology, Johns Hopkins University School of Medicine, Baltimore, MD, USA

⁹Department of Nuclear Medicine, University Hospital Essen, Germany

¹⁰Department of Molecular and Medical Pharmacology, David Geffen School of Medicine at

UCLA, USA

Correspondence:

Steven P. Rowe, M.D., Ph.D.

Division of Nuclear Medicine and Molecular Imaging

The Russell H. Morgan Department of Radiology and Radiological Science

Johns Hopkins University School of Medicine

601 N. Caroline St.

Baltimore, MD 21287

Phone: (410) 502-1520

E-mail: srowe8@jhmi.edu

First Author:

Rudolf A. Werner, M.D.

University Hospital Würzburg

Department of Nuclear Medicine

Oberdürrbacherstr. 6

97080 Würzburg, Germany

Phone: +49 931 201 35905

E-mail: werner_r1@ukw.de

*This research was originally published in JNM. Authors: Rudolf A. Werner, Ralph A. Bundschuh, Lena Bundschuh, Stefano Fanti, Mehrbod S. Javadi, Takahiro Higuchi, A. Weich, Kenneth J. Pienta, Andreas K. Buck, Martin G. Pomper, Michael A. Gorin, Ken Herrmann, Constantin Lapa, Steven P. Rowe. Novel Structured Reporting Systems for Theranostic Radiotracers. **J Nucl Med May 1, 2019 vol. 60 no. 5 577-584** © SNMMI.*

NOTEWORTHY

- Several framework systems for both PSMA-targeted PET for prostate cancer and SSTR-targeted PET for neuroendocrine neoplasias have been introduced (p. 4/5).
- For PSMA-targeted PET, these are: a consensus paper written on behalf of the *European Association of Nuclear Medicine and Molecular Imaging* (p. 5), *PSMA-RADS* (p. 6) and *PROMISE* (p. 7).
- For SSTR-targeted PET, these are: the *NETPET Grade* and *SSTR-RADS* (p. 10, respectively).
- Future directions should focus on validation of such systems or by defining one single universal framework system per radiotracer (p. 12).

ABSTRACT

Standardized reporting is more and more routinely implemented in clinical practice and such structured reports have a major impact on a large variety of medical fields, e.g. laboratory medicine, pathology, and, recently, radiology. Notably, the field of nuclear medicine is constantly evolving, as novel radiotracers for numerous clinical applications are developed. Thus, framework systems for standardized reporting in this field may a) increase clinical acceptance of new radiotracers, b) allow for inter- and intra-center comparisons for quality assurance, and c) may be used in (global) multi-center studies to ensure comparable results and enable efficient data abstraction. In the last two years, several standardized framework systems for positron emission tomography (PET) radiotracers with potential theranostic applications have been proposed. These include systems for prostate-specific membrane antigen (PSMA)-targeted PET agents for the diagnosis and treatment of prostate cancer (PCa) and somatostatin receptor (SSTR)-targeted PET agents for the diagnosis and treatment of neuroendocrine neoplasias. In the present review, those standardized framework systems for PSMA- and SSTR-targeted PET will be briefly introduced followed by an overview of their advantages and limitations. In addition, potential applications will be defined, approaches to validate such concepts will be proposed, and future perspectives will be discussed.

KEYWORDS: Prostate cancer, Neuroendocrine Neoplasia, 68Ga-DOTATATE, 68Ga-DOTATOC, 68Ga-DOTANOC, somatostatin receptor, SSTR, prostate-specific membrane antigen, PSMA, Standardized reporting, RADS, PSMA-RADS, SSTR-RADS, MI-RADS, PROMISE

INTRODUCTION

In general, standardized reporting has recently been more routinely implemented in clinical practice. Such structured reports, which, in some contexts were introduced as early as the 1970s, have had a major impact on a large variety of medical fields, e.g. laboratory medicine (1), pathology (2), and, recently, radiology (3,4). Notably, the field of nuclear medicine is constantly evolving, as novel radiotracers for numerous clinical applications are developed and administered in the clinical setting (5-8). Thus, framework systems for standardization of reporting in this field would be particularly necessary. Nuclear medicine reporting frameworks may a) increase clinical acceptance of novel radiotracers that are being transitioned into routine clinical practice, b) open avenues for inter- and intra-reader and -center comparisons for quality assurance purposes, and c) may be used in (global) multi-centric studies to more efficiently enable comparison of datasets from different centers.

In the last two decades, somatostatin receptor (SSTR) agonists such as ⁶⁸Ga-DOTATOC, ⁶⁸Ga-DOTATATE or ⁶⁸Ga-DOTANOC and subsequent therapies with either ¹⁷⁷Lu- or ⁹⁰Y-labeled analogs have become a standard of care for patients with SSTR-expressing tumors throughout the world (9-12). In a similar vein to SSTR-targeted PET for neuroendocrine neoplasias (NEN), the use of radiotracers for prostate-specific membrane antigen (PSMA), either labeled with ⁶⁸Ga or ¹⁸F, is rapidly becoming a new standard of care for prostate cancer (PCa) imaging throughout much of the world, in particular as the theranostic concept can potentially be applied in PCa as well (13-16).

Several systems to aid interpretation of imaging findings with 2-deoxy-2-¹⁸F-fluoro-D-glucose (¹⁸F-FDG) PET in order to determine disease response to therapy for oncology patients have been proposed, such as the Deauville/Lugano Criteria or the PET Response Criteria in Solid Tumors (PERCIST 1.0). Those systems are specifically less focused on providing diagnostic information on baseline imaging studies (17,18). However, in light of the evolving field of theranostics for NEN and PCa, where findings on baseline diagnostic imaging portend treatment success with radioligand therapies, the field is in need of baseline criteria for evaluating either PSMA- or SSTR-targeted PET scans.

This clinical need has not gone unnoticed, and a great deal of recent progress has been made by the introduction of novel standardized framework systems for the evaluation of various receptor-based radiotracers. These are for PCa: (1) PSMA-Reporting and Data System (PSMA-RADS) Version 1.0, (2) Prostate Cancer Molecular Imaging Standardization Evaluation (PROMISE) and (3) a proposed standardized framework system for ⁶⁸Ga-PSMA PET/CT for the detection of recurrent lesions, which was written on behalf of the European

Association of Nuclear Medicine and Molecular Imaging (EANM) (19-21). Thus, the latter framework system is herein referred to as the EANM Consensus Paper (21). For NEN, the framework systems include SSTR-RADS Version 1.0, which applies the concept of PSMA-RADS to NEN and considers SSTR-specific details (22). Notably, both RADS framework systems (PSMA- and SSTR-RADS) have been recently summarized under the umbrella term “molecular imaging RADS (MI-RADS)”, as those systems can be applied reciprocally (i.e. imaging interpreters who are familiar with one system should be able to learn the other RADS system) (23). Another NEN specific system is the NETPET grade, which utilizes a dual-radiotracer approach (SSTR-targeted and ¹⁸F-FDG PET). The NETPET scoring system will also be reviewed here; however, this system has been developed as a prognostic biomarker to capture the findings of a dual radiotracer assessment in one single parameter, rather than for evaluating a baseline SSTR-PET scan (24).

In the present review, those concepts will be briefly introduced, followed by an overview of their advantages and limitations. In addition, potential applications will be defined, approaches to validate such concepts will be proposed, and future perspectives will be discussed.

PATIENT POPULATION

Because the herein presented data comprise a retrospective analysis of routinely acquired data, the local ethic committee waived the need for further approval. All patients gave written and informed consent to the procedures, and all patients provided written informed consent for scientific analysis of the obtained data.

STANDARDIZED REPORTING SYSTEMS FOR PROSTATE CANCER

EANM Consensus Paper

On behalf of the EANM, *Fanti et al.* proposed a standardized imaging interpretation system for ⁶⁸Ga-PSMA, which uses the following criteria: first, anomalous findings, defined as suspicious radiotracer uptake above physiological background are recorded. Second, all those sites are classified as “pathologic” for PCa, unless another explanation is apparent, i.e. false-positive findings, such as PSMA-avid Paget’s disease (25). Third, the anatomical localization is taken into account (up to five lesions). Of note, *Fanti* and co-workers not only proposed the system, but also performed a concordance assessment among multiple readers. Notably, an inter-observer agreement (Krippendorff’s alpha) of 0.64 (i.e., moderate agreement) was achieved when readers had to evaluate whether the investigated target lesions were suggestive of a pathologic, uncertain, or non-pathologic entity. After conducting several Delphi Rounds to reach consensus between the different study sites, the following

amendments were introduced: 1.) a finding observed only on CT will be classified as “abnormal”, but “uncertain”, 2.) in patients with residual prostatic tissue (no radical prostatectomy) and sources of artifact (e.g., brachytherapy seeds), the intensity of focal uptake is of importance whether the lesion should be classified as “pathologic” and 3.) recurrence sites (other than the site of primary treatment) need increased attention and again, in case of intense focal uptake, can be considered “pathologic”.

This framework system has also been further validated: in 49 subjects from seven study sites, a moderate agreement among readers was achieved. Notably, several conducted Delphi Rounds led to further improvement of the system, reduced the number of discordant cases, and achieved consensus among the readers. Thus, the EANM Consensus Paper aimed to identify possible disagreements among multiple experts and provide suggestions for appropriate reporting (21). However, a definition for the level of uptake, like defined in PROMISE, is not given. Further, a translation of the derived findings into an alphanumeric code, as suggested in PSMA-RADS, may facilitate memorizing this system (19-21). Nonetheless, as a major achievement of the EANM Consensus Paper, the authors provide a definition on which finding can be seen as uncertain, which in turn may lay the groundwork for fusing this system with the five-point scale provided in PSMA-RADS and the level of uptake as defined in PROMISE (20,21).

MI-RADS

A recent effort has summarized two RADS framework systems proposed to date for molecular imaging (i.e. PSMA- and SSTR-targeted PET/CT interpretation, namely PSMA- and SSTR-RADS) under one umbrella term: MI-RADS (23). MI-RADS systems are exclusively based on imaging findings (site of disease and intensity of radiotracer uptake) and both refer to a 5 point Likert scale (from 1 = no evidence of disease/definitively benign to 5 = high certainty that PCa or NEN is present). This underlying identical structure allows both MI-RADS systems to be used reciprocally (23). Supplemental Table 1 provides a precise overview of MI-RADS. In the following, we will first introduce PSMA-RADS for PCa.

PSMA-Reporting and Data System (PSMA-RADS) Version 1.0

Rowe et al. suggested a five-point scale for the interpretation of PSMA-targeted PET/CT for PCa and also provided recommendations of appropriate next steps in the work-up of indeterminate findings (19). In brief, PSMA-RADS-1A describes a scan without abnormal radiotracer uptake (i.e. normal biodistribution of a PSMA imaging agent), while PSMA-RADS-1B findings are benign lesions that demonstrate radiotracer uptake and which have been confirmed by histological diagnosis or definitively characterized as benign on imaging (e.g., a

PSMA-avid thyroid nodule that has been previously biopsied and found to be an adenoma). PSMA-RADS-2 describes sites with low level uptake (\leq blood pool level), which are almost certainly benign and would be atypical for PCa. PSMA-RADS-3 includes indeterminate lesions and thus, those lesions may trigger further work-up. In PSMA-RADS-4 lesions, PCa is highly likely, due to intense uptake in a site typical for PCa but without an abnormality on anatomic imaging. PSMA-RADS-5 lesions demonstrate intense PSMA uptake in a site typical for PCa with corresponding evidence on conventional imaging and PCa is almost certainly present (19) (Supplemental Table 1). As proposed in its successor SSTR-RADS (22), an overall PSMA-RADS score assessment may be useful to provide the referring clinician with an overall scan impression in the summary statement/impression of the report. Further, up to five target lesions are selected and given individual PSMA-RADS scores. Based on this target lesion assessment, the overall PSMA-RADS score can be defined as the highest score of any of the individual target lesions. Figure 1 shows an overall PSMA-RADS score assessment.

Notably, the PSMA-RADS scoring system has recently been further validated. PSMA-RADS-3A (soft tissue sites) and -3B (bone lesions) can refer to findings that have low levels of uptake and lack a correlative anatomic finding (19). In patients with indeterminate findings and available follow-up imaging, the majority (75.0%) of PSMA-RADS-3A lesions demonstrated changes on subsequent imaging compatible with the presence of PCa, while only a minority (21.4%) of PSMA-RADS-3B indeterminate bone lesions showed changes on follow-up imaging suggestive of underlying PCa. These findings confirm the necessity for a category in the PSMA-RADS grading system for indeterminate lesions (26). In addition to that, the PSMA-RADS system has also been evaluated in a prospective inter-observer agreement setting using 50 18F-DCFPyL PET/CT scans. Four readers (two experienced and two inexperienced), blinded to the clinical status of the patients, performed an evaluation of all scans independently and evaluated PSMA-RADS on a target lesion-based, on an organ-based, and on an overall PSMA-RADS score-based level. The inter-observer agreement for PSMA-RADS scoring among identical target lesions was good (intra-class correlation coefficient, ≥ 0.60). For lymph nodes and the overall scan impression (Figure 2), an excellent inter-observer agreement was derived (intra-class correlation coefficient, 0.79 and 0.84, respectively). Given the high concordance rate in this study, even among readers with different levels of experience, PSMA-RADS may be able to be implemented in the collection of data for large prospective trials (27).

Prostate Cancer Molecular Imaging Standardization Evaluation (PROMISE)

Eiber and colleagues proposed the molecular imaging TNM (miTNM, version 1.0)

classification as a standardized framework system for PSMA-ligand PET/CT and PET/magnetic resonance imaging (MRI) (20). This scoring system determines the uptake on a 4-point scale in visual assessment (“miPSMA expression score”, with different levels of uptake noted relative to the normal uptake in the bloodpool, liver, and parotid glands). Of note, in PSMA-targeted PET scans with liver-dominant excretion PET agents, such as 18F-PSMA 1007, the liver is replaced by the spleen (20,28). Moreover, categorization of local tumor (T) takes the extent and organ confinement into account (miT0, no local tumor; miT2, organ-confined tumor with u=unifocality or m=multifocality; miT3, non-organ-confined tumor with a (extracapsular extension) or b (tumor invading seminal vesicles) to miT4, tumor invading adjacent structures other than seminal vesicles). A strength of PROMISE is that it directly addresses local tumor staging. To evaluate the intra-prostatic tumor extension, a sextant segmentation of the prostate gland was proposed, which in turn may provide detailed information for biopsies.

Moreover, in PROMISE, the pelvic node metastases (N) are assessed and categorized as no positive LN (miN0), single involved nodal regions (miN1a) or multiple involved nodal regions (miN1b), with further demarcation as to the exact nodal groups involved: miN1a/b: II, Internal iliac; EI, External iliac; CI, Common iliac; OB, Obturator; PS, Presacral; OP, Other Pelvic (should be specified). Finally, the extrapelvic nodes (miM1a: RP, Retroperitoneal; SD, Supradiaphragmatic and OE, Other Extrapelvic) and distant metastases (miM1b, referring to bone and miM1c, other sites of organ involvement) are included. Skeletal involvement is classified as having unifocal (Uni), oligometastatic (Oligo, $n \leq 3$ sites), disseminated (Diss) or diffuse bone marrow (Dmi) involvement. In addition, the authors recommend documenting diagnostic certainty on a 5-point scale (“consistent with” PCa to “no evidence of disease”). In addition, final diagnosis should be reported as positive or negative for PCa, whereas a final diagnosis should be only classified as “equivocal”, if further work-up using other techniques is available. Taken together, PROMISE includes information on location, disease distribution pattern, level of PSMA expression, and level of certainty that PCa is present. Figure 3 gives an example of primary staging using 68Ga-PSMA-11 PET/high-resolution T2-weighted MRI in a 65 year old male with histopathologically proven PCa. PROMISE has been applied to this patient with a result of miT3aN1(OBL)M0 (with L referring to the left side of obturator LN involvement) (20).

Potential Applications

Similar to 18F-FDG, a considerable number of studies have reported on pitfalls while reading PSMA-targeted PET scans. As a physiologic radiotracer uptake site, ganglia can be misinterpreted, in particular in terms of mistaking such structures for abdominal lymph nodes

(e.g. coeliac ganglia) (29-31). Benign pathologies may also mimic PCa, such as fibrous dysplasia, healing bone fractures, or granulomatous diseases (e.g. sarcoidosis) (25,32-34). Apart from that, non-prostatic malignancies that may demonstrate uptake of PSMA-targeted radiotracers include, but are not limited to, pancreatic NEN, squamous cell carcinoma of the oropharynx, hepatocellular carcinoma, and renal cell carcinoma (25,35-38). While the detection rate and recognition of those potentially confusing false-positive or false-negative findings on PSMA-targeted PET scans can almost certainly be increased by appropriate training, PSMA-RADS may live up to its full potential in providing a mechanism for readers to formalize uncertainty regarding such findings and providing clinicians with recommendations regarding any necessary further work-up. Intended to serve as a readily applicable system for any imaging expert, PSMA-RADS is simple, easy to memorize and utilize, and, thus, it may serve as a powerful tool to assist in diagnosis in a busy clinical PCa practice. However, as a drawback, PSMA-RADS uses terms like “typical” or “atypical” for sites of disease, and follow-up versions of this system should clarify such phrases to increase the level of reader’s confidence (19,39). Apart from that, PSMA-RADS does not stipulate the inclusion in-depth anatomic details. This is in contradistinction to the EANM Consensus Paper or PROMISE, which gives a more thorough evaluation of PSMA-targeted PET/CT or PET/MRI findings and includes a large variety of details in imaging interpretation (20,21). This characteristic may pave the way for incorporating the latter systems in large clinical trials, in which distinct, numerous parameters should be obtained to enrich the dataset and allow for fine parsing of patient subsets for outcomes research. PROMISE also includes visual criteria using internal organ reference of PSMA-uptake and this may be also a consideration for principal investigators to consider PROMISE in a research setting, albeit this proposed visual assessment needs further confirmation (20,39). In addition, threshold sensitivity may also have an impact on the miPSMA expression score (39). Apart from that, PROMISE is the only of the herein reviewed systems which has been used in a preclinical setting to investigate the *in-vivo* relationship between ⁶⁸Ga-PSMA-11 PET/CT and PSMA expression in a murine model of PCa (40). As a major advantage of the proposed system on behalf of the EANM, this reporting system has been assessed in a Delphi approach of consensus, which serves as a reliable means for managing tumor entities (21,41), and this may be a significant advantage for training less experienced readers. Currently, all PCa framework systems lack treatment recommendations for endoradiotherapies. However, given the evolving field of ⁶⁸Ga/¹⁸F/¹⁷⁷Lu-PSMA theranostics, future versions should consider instructions at which time point to initiate such treatments.

Table 1 summarizes limitations and advantages of framework systems for evaluating PSMA-targeted PET/CT scans for PCa patients.

STANDARDIZED REPORTING SYSTEMS FOR NEUROENDOCRINE NEOPLASIAS

The NETPET Grade

In contrast to the aforementioned framework systems for PCa, the NETPET Grade does not intend to evaluate an isolated baseline examination, but to provide a dual SSTR/18F-FDG grading scheme. This is mainly due to the assumption that the most 18F-FDG-avid lesion (relative to its uptake on SSTR-PET) may also reflect the most aggressive phenotype of the disease present. On a 5-point scale, the spectrum of results seen on both PET scans are as follows: P0 is negative on both PETs, P1 is SSTR-(+), but 18F-FDG(-), P2 through P4 are positive on both PETs, but their intensities relative to each other differ (i.e., these lesions represent an intermediate group on dual-radiotracer imaging), while P5 is SSTR(-), but 18F-FDG(+) (24,42). Notably, analogous to the EANM Consensus Paper for PSMA-targeted PET, the NETPET Grade has been validated in the same paper (21,24). Kaplan-Meier curves presented for subjects grouped to P1, P2-4 and P5 revealed a significant separation of overall survival for those three groups, indicating that the NETPET grade may serve as a predictor for outcome; however, the study cohort included different sites of primary tumors, and different treatments (only parts of the cohort treated with peptide receptor radionuclide therapy (PRRT)) (24).

Somatostatin Receptor Reporting and Data System (SSTR-RADS) Version 1.0

Analogous to PSMA-RADS, a standardized framework system for interpreting SSTR-targeted PET/CT scans has recently been introduced and has been given the moniker SSTR-RADS (22). As part of MI-RADS (23), SSTR-RADS also uses a 5-point scale (1 = benign to 5 = NEN almost certainly present) and is exclusively based on imaging findings (site of disease and intensity of radiotracer uptake); however, it refers to SSTR-targeted PET and NEN-specific details. SSTR-RADS-1 indicates findings which are known to be benign (confirmed by previous biopsy or with pathognomonic appearance on conventional anatomic imaging) and includes SSTR-RADS-1A (normal biodistribution) and SSTR-RADS-1B (increased focal uptake but definitively benign by histology or imaging). SSTR-RADS-2 lesions are likely benign and describe soft-tissue sites or bone lesions *atypical* of metastatic NEN (e.g., strongly suspected to be degenerative, like a Schmorl node). SSTR-RADS-3 includes indeterminate lesions and will often require further work-up. SSTR-RADS-4 (NEN highly likely) includes intense uptake in a site typical for NEN, but *lacks* definitive findings on CT. SSTR-RADS-5 indicates a lesion in which NEN is almost certainly present and the site of intense radiotracer uptake on SSTR-PET corresponds to an anatomic abnormality (Supplemental Table 1). Those SSTR-RADS classifications do not only have recommendations for further work-up (biopsy and/or imaging), but also propose at which time-point to initiate PRRT with either 177Lu- or 90Y-labeled agents. The most dominant

lesion (largest in size and most intense in uptake) will overrule the other target lesions and this representative lesion defines the overall SSTR-RADS score. With an overall SSTR-RADS-1 to -3, PRRT with “hot” somatostatin analogues should not be considered, while for an overall SSTR-RADS-4 or -5, PRRT is recommended; however, common practical guidelines still apply (22,43). In Supplemental Figures 1 and 2, SSTR-RADS has been applied to SSTR-PET/CTs (Supplemental Figure 1, overall SSTR-RADS score of 5 and Supplemental Figure 2, overall score of 3D).

Potential Applications

As discussed earlier, SSTR-RADS was formulated as a system to assess the baseline SSTR-targeted PET and gives recommendations for both further work-up and treatment. In this regard, it may guide the referring treating physician to consider PRRT with ¹⁷⁷Lu- or ⁹⁰Y-labeled compounds. Moreover, it takes the level of uptake into account, while using an internal organ reference. As part of MI-RADS, SSTR-RADS is based on the initial proposed framework system PSMA-RADS (although SSTR-targeted PET and NEN-specific details have been implemented in SSTR-RADS) and thus, both systems can be used reciprocally (23).

No validation studies with SSTR-RADS have yet been carried out, and this is in contradistinction to the NETPET grade, which has already proven its prognostic potential in a retrospective setting. Combining a dual-radiotracer approach of SSTR-/¹⁸F-FDG-PET/CT in a single parameter, the latter framework system showed its capability as an outcome predictor (24). However, a dual radiotracer-approach is not performed routinely during follow-up and thus, SSTR-RADS may serve as a reliable tool to investigate both baseline and follow-up scans. Its relevance for clinical practice is also evidenced by the recognition of pitfalls on SSTR-targeted PET/CT and by the associated recommendations for both work-up and treatment (e.g. indication for PRRT) (44).

Table 2 summarizes limitations and advantages of both systems for evaluating SSTR-targeted PET/CTs.

RECOMMENDATIONS FOR FUTURE VALIDATION AND A GLIMPSE AT FUTURE DIRECTIONS

Recommendations for Future Validation

Before testing in “real-world” scenarios, the reproducibility and robustness of the herein reviewed standardized framework systems should be proven (45). Thus, several steps for validation should be pursued:

- I. Inter- and intra-observer agreement studies, ideally with multiple centers, and multiple readers with different levels of experience should be performed (27).
- II. While it is not possible to biopsy every single investigated target lesion, indeterminate lesions should be identified and compared with follow-up imaging findings when pathology is not available (26).
- III. Validation with different radiotracers may be indispensable, as the biodistribution of PSMA radioligands even with similar radioisotopes may differ (e.g. the biodistribution among normal organs using either 18F-PSMA-1007 or 18F-DCFPyL) (28,46).
- IV. Validation of the detection rate of primary and metastatic disease with correlations to biopsy-driven histopathological assessments are of importance to receive ultimate evidence (39).
- V. The motivation to learn such standardized reporting systems should be evaluated. In addition, the change in reader’s confidence to read PET/CT with theranostic implications should be measured when such systems have been applied. Moreover, the implementation rate in clinical practice should be investigated.
- VI. The herein reviewed framework systems aim to provide structured reporting systems for both PCa and NEN. However, molecular imaging *per se* may still remain rather asemantic, i.e. the language used in a report needs to be conventionally associated to meanings (47).

Future Directions

For a more global standardization along with a rapid implementation in clinical routine, a great deal of progress can be made by potentially creatively fusing the different existing systems, e.g. by defining one single universal framework system per radiotracer under the umbrella of the different nuclear medicine societies. Such an approach may expedite the transfer from leading institutions to smaller PET centers, may open avenues for more tailored treatment decisions, allow for intra-/inter-center comparisons, and may pave the way for an adoption in multi-center studies.

Apart from that, such framework systems should also be developed for other theranostic pairs, e.g. 68Ga-Pentixafor/177Lu-Pentixather, which target the C-X-C chemokine receptor CXCR4 (6). Other potential theranostic twins may include the Fibroblast Activation Protein (FAP) targeting 68Ga-/90Y-FAPI04 or 177Lu-labeled and bombesin peptides for the gastrin releasing peptide receptor (GRPR) (5,7).

DISCUSSION AND CONCLUSION

Given the indispensable need for harmonization of the interpretation of PET radiotracers with potential theranostic applications, several framework systems for both PSMA-targeted PET for PCa and SSTR-targeted PET for NEN have been introduced in the last two years (19-24). Existing framework systems for interpretation of imaging findings with 18F-FDG (Lugano, PERCIST) mainly allow for an overall assessment of treatment response, but theranostic radiotracers need baseline criteria to identify potential candidates for subsequent endoradiotherapies (48,49). In addition, such criteria would be helpful to standardize collected data for large, multi-center trials (50). For PCa, three framework systems have been proposed: PROMISE provides an in-depth evaluation of imaging-based findings, in particular for anatomic details (e.g. primary tumor location on sextant basis) (20). In contradistinction, the 5-point scale of PSMA-RADS is easy to memorize and utilize and, thus, it may serve as a powerful tool to assist in diagnosis in a busy, clinical PCa practice (19). Moreover, PSMA-RADS has also been validated in a prospective inter-observer agreement setting with overall high concordance rates, even among inexperienced readers (27). In a similar vein, the EANM Consensus Paper has also been further validated in a multi-center assessment and consensus has been defined in a sophisticated approach conducting several Delphi rounds with expert readers (21).

For NEN, SSTR-RADS has been recently introduced, which is based on the PSMA-RADS system, but takes SSTR-targeted PET- and NEN-specific details into account (22). Both PSMA- and SSTR-RADS have been recently summarized under one umbrella term, which describes the application of RADS for molecular oncology imaging (MI-RADS). MI-RADS systems can be applied reciprocally, i.e. imaging interpreters who are familiar with PSMA-RADS should be able to learn SSTR-RADS as well (19,22,23). The NETPET system consolidates the findings of an SSTR-targeted and 18F-FDG PET in one single parameter and also provides treatment recommendations based on imaging findings (24).

Future studies are warranted to more completely validate such framework systems, e.g. in inter-observer agreement studies on a larger scale or by correlation of imaging findings with histopathological results (27,39). Apart from that, consensus conferences are needed to further standardize those framework systems, ideally in one single universal framework system per radiotracer.

Standardized Framework System	Advantages	Limitations
EANM Consensus Paper (21)	<ul style="list-style-type: none"> ✓ Consensus Strategy for validation: after initial introduction, the system has been validated by different sites and further improved in a Delphi consensus setting ✓ Provides detailed evaluation and criteria for uncertain findings ✓ Without having a scale, it demonstrated moderate consensus among experts and thus, it emphasizes the importance of incorporating scalability in structured reporting systems 	<ul style="list-style-type: none"> ✓ Visual criteria scale is lacking, e.g. based on internal organ uptake as a reference ✓ Does not include treatment recommendations for PSMA-based endoradiotherapies
PSMA-RADS Version 1.0 (19)	<ul style="list-style-type: none"> ✓ Considers site of disease and intensity of radiotracer uptake on a 5-point scale, which may be easy to memorize ✓ Part of MI-RADS, i.e. imaging interpreters who are familiar with PSMA-RADS should be able to learn SSTR-RADS (22,23) ✓ May be useful to guide the reader in interpreting confusing false-positive or false-negative discoveries, e.g. potential non-prostatic malignancies or benign findings mimicking PCa (25) ✓ Provides clinical recommendations based on PSMA-RADS scoring (e.g., PSMA-RADS 3 triggers further work-up) (39) ✓ Has been further validated in a long-term follow-up study investigating indeterminate PSMA-RADS 3A and 3B lesions (26) ✓ Demonstrated high interobserver agreement, even among inexperienced readers (27) 	<ul style="list-style-type: none"> ✓ Terms like “typical” or “atypical” for PCa need further definition in follow-up version of PSMA-RADS (39) ✓ Needs an Overall PSMA-RADS Score definition, similar to SSTR-RADS (22) ✓ Visual criteria scale is lacking, e.g. based on internal organ uptake as a reference ✓ Does not include treatment recommendations for PSMA-based endoradiotherapies ✓ Initial definitions are arbitrary, and further validation is needed (e.g. by comparison of PSMA-RADS classification with histological specimen or outcome assessments)
PROMISE (20)	<ul style="list-style-type: none"> ✓ Considers anatomical details, e.g. tumor location on sextant basis ✓ Provides visual criteria scale (miPSMA Expression Score) based on reference organs ✓ Initially invented with the intention to be applicable to both hybrid imaging modalities, PET/CT and PET/MRI ✓ Variety of included details may pave the way for incorporating PROMISE in large clinical trials, in which numerous parameters are needed to enrich the dataset ✓ Tested <i>in-vivo</i> in a PCa murine model and thus, could potentially be applied in other preclinical settings (40) 	<ul style="list-style-type: none"> ✓ Further validation is needed (interobserver agreement studies, histopathological comparisons) ✓ Threshold sensitivity may have an impact on miPSMA Expression score (39) ✓ Does not include treatment recommendations for PSMA-based endoradiotherapies

Table 1. Head-to-Head comparison of Standardized Framework Systems for Prostate-Specific Membrane (PSMA)-positron emission tomography (PET)/ computed tomography (CT) for evaluating Prostate Carcinoma (PCa). EANM = European Association of Nuclear Medicine, PSMA-RADS = PSMA-Reporting and Data System Version 1.0, MI-RADS = molecular imaging RADS, SSTR-RADS = somatostatin receptor RADS, PROMISE = Prostate Cancer Molecular Imaging Standardization Evaluation, MRI = magnetic resonance imaging.

Standardized Framework System	Advantages	Limitations
NETPET Grade (24)	<ul style="list-style-type: none"> ✓ Has demonstrated its prognostic value in a retrospective study ✓ Aims to combine a dual-tracer approach in a single parameter ✓ May also guide treatment, e.g. P1, P2: somatostatin analogues vs. P5: chemotherapy ✓ Discriminate subjects which have positive uptake on both imaging modalities (intermediate group, P2 – P4) (42) ✓ May be of value for risk stratification and could play a potential role in clinical trials 	<ul style="list-style-type: none"> ✓ A dual tracer-approach is not performed routinely during follow-up (44) ✓ Not a baseline criterion ✓ Does not consider pitfalls on SSTR-PET/CTs ✓ Gives rather less work-up recommendations for specific situations (e.g. when to perform biopsy or follow-up treatment)
SSTR-RADS Version 1.0 (22)	<ul style="list-style-type: none"> ✓ Investigates baseline SSTR-PET/CTs and gives recommendations for both further work-up and treatment ✓ May guide the referring treating physician to consider PRRT ✓ Part of MI-RADS: SSTR-RADS and PSMA-RADS can be applied reciprocally (19,23) ✓ Takes the level of SSTR expression into account (three-point qualitative assessment to rate the level of uptake) ✓ Increases the reader's level of confidence by emphasizing pitfalls on SSTR-PET/CT ✓ Easy to memorize and utilize and thus, may be readily applicable in a clinical setting 	<ul style="list-style-type: none"> ✓ Takes the level of uptake into account, while using an internal organ reference, but normal organ distribution may vary among novel SSTR radiotracers (42) ✓ Initial definitions are arbitrary, and further validation is needed (interobserver agreement studies, histopathological comparisons)

Table 2. Head-to-Head comparison of Standardized Framework Systems for Somatostatin-Receptor (SSTR)-positron emission tomography (PET)/ computed tomography (CT) for evaluating Neuroendocrine Neoplasias. SSTR-RADS = Somatostatin-Receptor Reporting and Data System

Version 1.0, PRRT = Peptide Receptor Radionuclide Therapy, MI-RADS = molecular imaging RADS.

FIGURES and FIGURE LEGENDS

Figure 1. Example for an Overall Assessment using prostate-specific membrane antigen PSMA-Reporting and Data System (PSMA-RADS) Version 1.0 (19).

76 year old male with history of proven PCa who underwent 18F-DCFPyL PET/CT for staging. (A) Whole body maximum intensity projection image demonstrates suspicious radiotracer uptake (arrowhead). On (B) axial CT, (C) axial PET, and (D) axial PET/CT, radiotracer uptake in a left external iliac lymph node (red arrow) is visualized. This has been classified as PSMA-RADS-4 by an experienced reader, as on the CT there is no corresponding pathologic finding. As an equivocal uptake in a bone lesion that would not be atypical in appearance on anatomic imaging for PCa, the finding in the ala of the left sacrum (double thin arrows) was classified as PSMA-RADS-3B (E-G). The overall RADS Score was 4 (Supplemental Table 1).

Figure 2. Overview of Overall-PSMA RADS Scoring for four blinded readers (ER, experienced reader, IR, inexperienced reader), all of whom evaluated 50 18F-DCFPyL PET/CT scans.

Often, characterizing a lesion as PSMA-RADS-1B involves previous conventional imaging or histologic diagnosis; as such, PSMA-RADS-1A and -1B were subsumed under PSMA-RADS-1 in this blinded interobserver agreement study. For the overall scan impression, a high interreader agreement rate, even among IRs, was noted. Modified from *Werner et al.* (27), © by the Society of Nuclear Medicine and Molecular Imaging, Inc.

Figure 3. Example for Prostate Cancer Molecular Imaging Standardization Evaluation (PROMISE) (20).

Primary staging using 68Ga-PSMA-11 PET/high-resolution T2-weighted MRI in a 65 year old male with histopathologically proven prostate cancer. Maximum intensity projection (A) shows intermediate PSMA expression (equivalent to score 2) in prostate gland (red arrow) and high PSMA expression (score 3) in a regional pelvic lymph node (dotted arrow). Axial PET/MRI (B) and coronal PET/MRI (C) with PET at top, hybrid images in middle and MRI at bottom demonstrate bilateral T2-hypointense lesions corresponding to uptake on PSMA-ligand PET, which exceeds prostate margin, indicating extracapsular extension (T3a, solid arrows). Axial imaging (D) shows single lymph node metastasis in left obturator region

(dotted arrows). The final diagnosis according to PROMISE was miT3aN1(OBL)M0. Sextant segment boundaries are shown on coronal images in white. Modified from *Eiber et al. (20)*, © by the Society of Nuclear Medicine and Molecular Imaging, Inc.

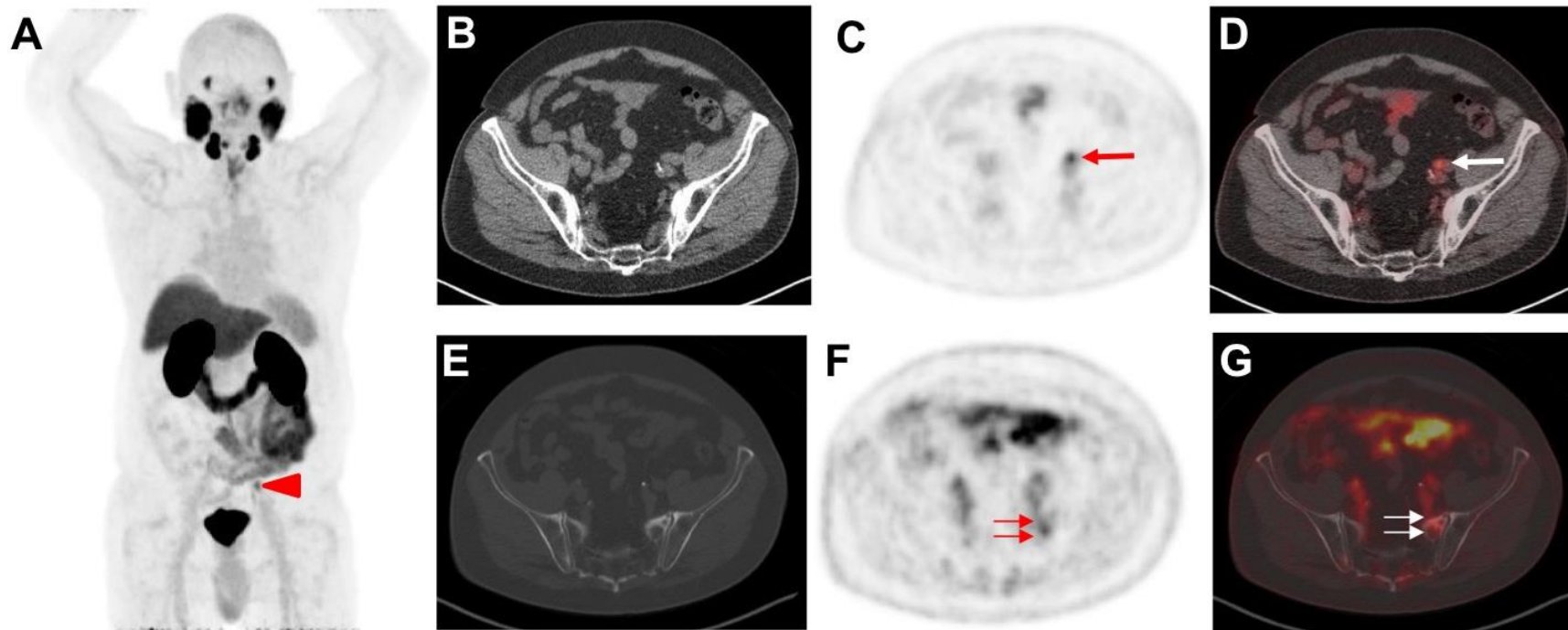


Figure 1.

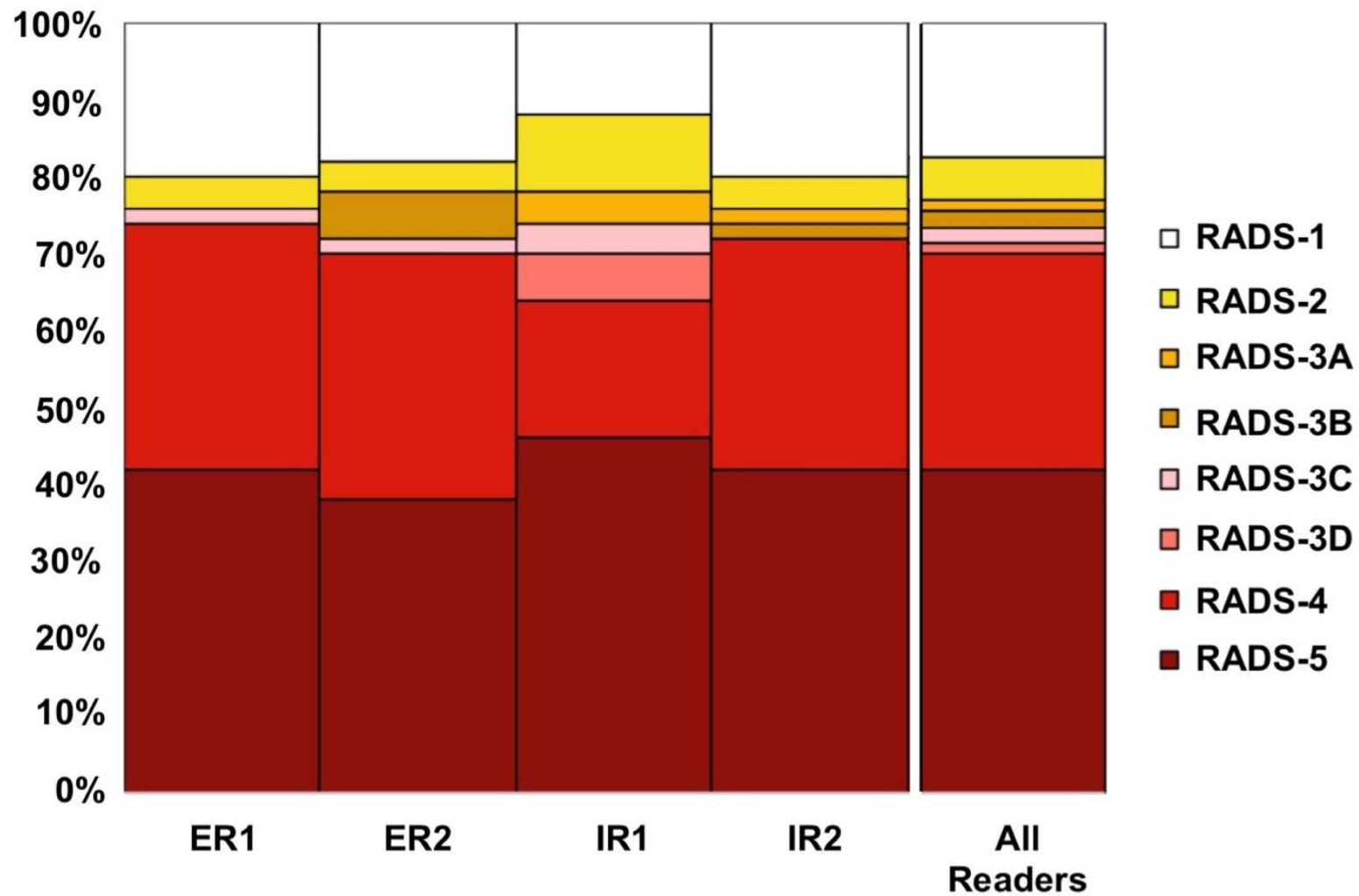


Figure 2.

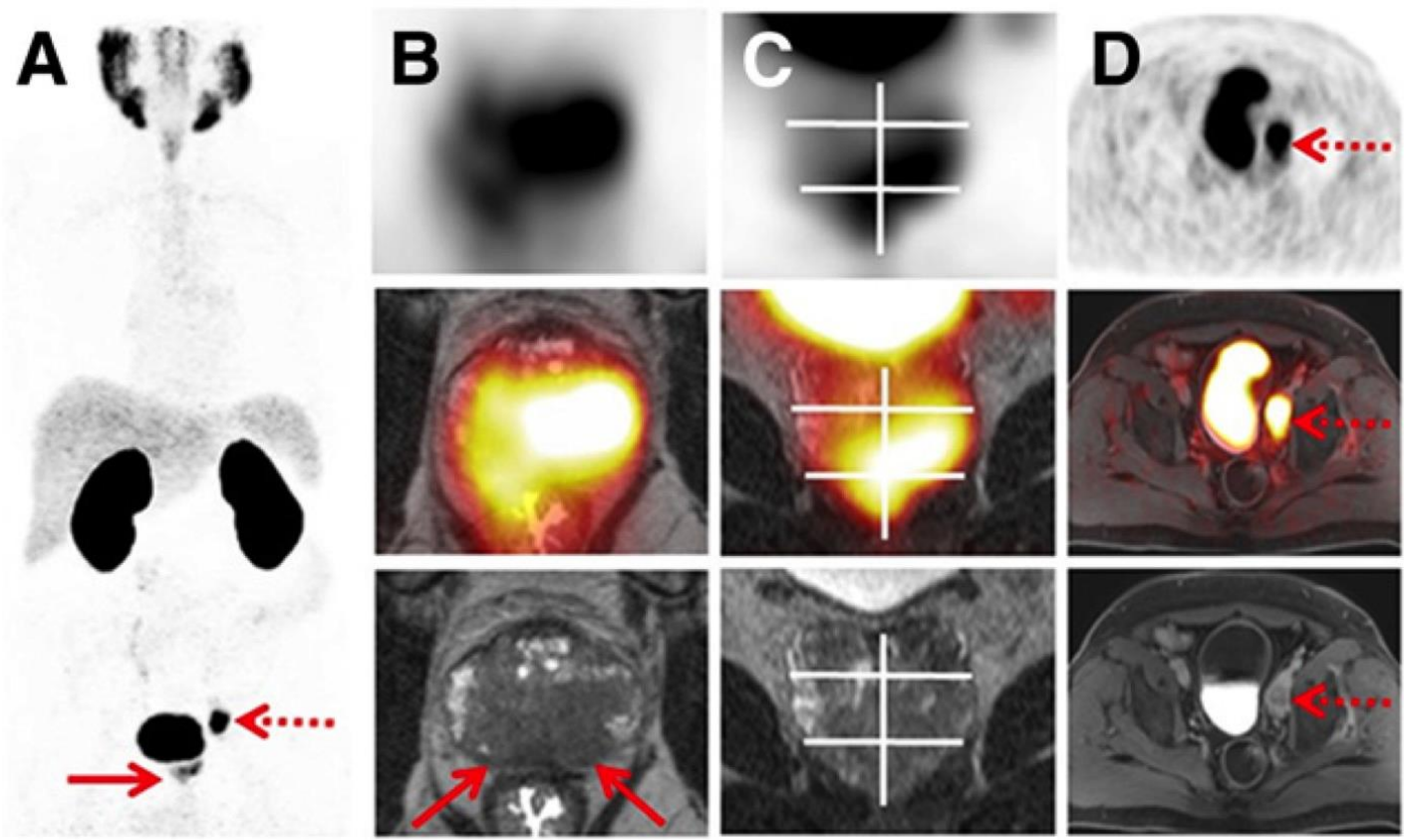


Figure 3.

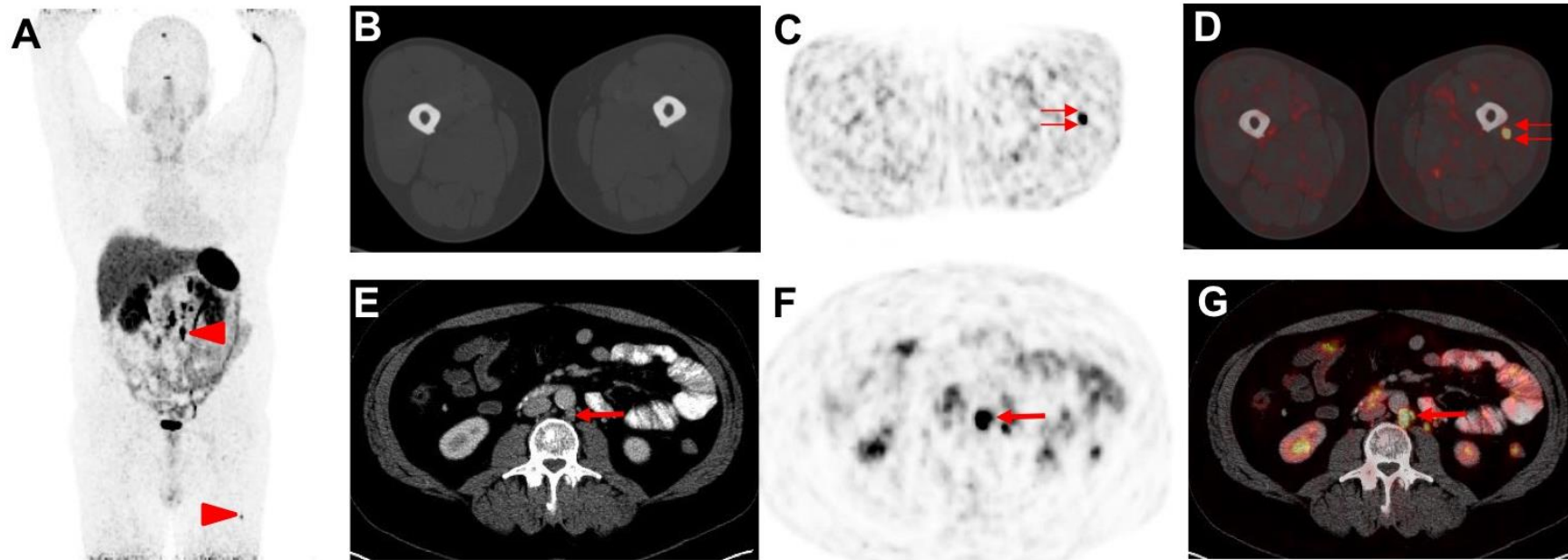
SUPPLEMENTAL FIGURES and TABLE

Supplemental Figure 1. Example for an Overall Assessment using somatostatin receptor (SSTR)-Reporting and Data System (SSTR-RADS) Version 1.0 (22), with an Overall SSTR-RADS Score of 5 (Supplemental Table 1).

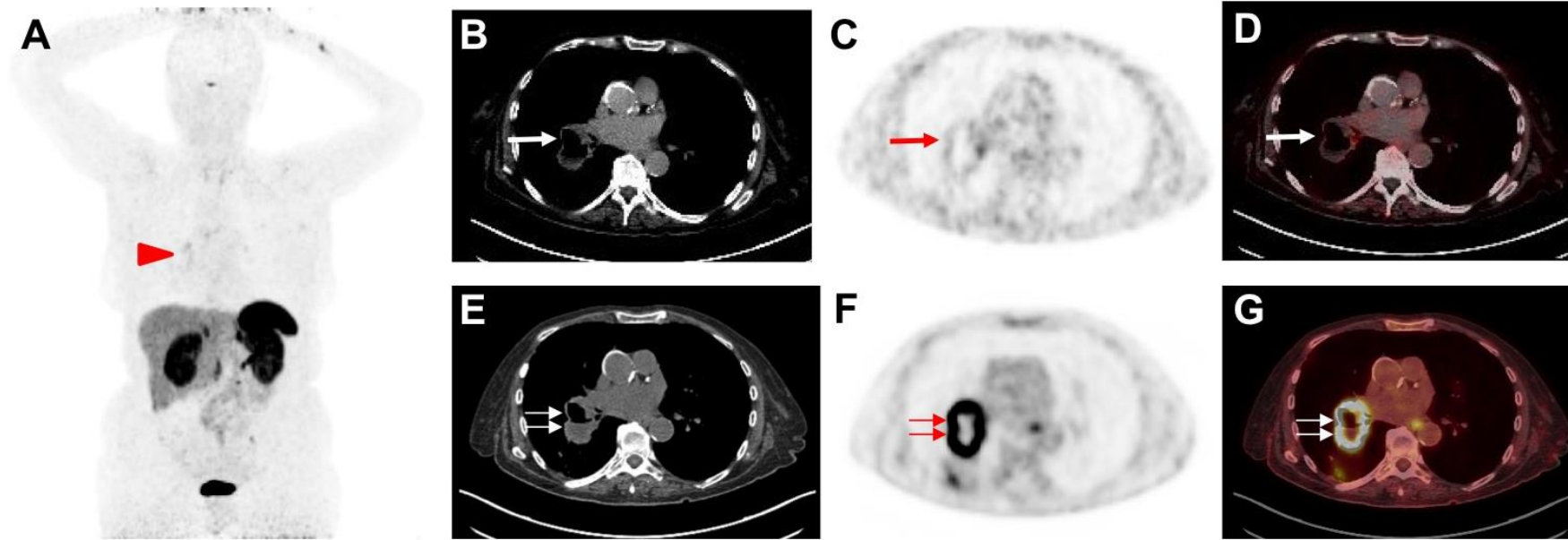
53 year old male with history of proven gastroenteropancreatic NET who underwent 68Ga-DOTATOC PET/CT for restaging. (A) Whole body maximum intensity projection image demonstrates suspicious radiotracer uptake (arrowheads). On (B) axial CT, (C) axial PET, and (D) axial PET/CT, intense radiotracer uptake in the left *musculus vastus lateralis* is seen (double thin arrows). This has been classified as SSTR-RADS-3C by an experienced reader and further workup was recommended. On (E) axial CT, (F) axial PET, and (G) axial PET/CT, intense radiotracer uptake is visualized in a retroperitoneal lymph node (arrow). As this site of radiotracer uptake shows corresponding findings on (E) axial CT, this finding was classified as SSTR-RADS-5 and therefore, the overall SSTR-RADS score was 5 (Supplemental Table 1).

Supplemental Figure 2. Example for an Overall Assessment using somatostatin receptor (SSTR)-Reporting and Data System (SSTR-RADS) Version 1.0 (22), with target lesion evaluated as SSTR-RADS-3D (Supplemental Table 1).

68 year old female with history of proven lung neuroendocrine tumor who underwent 68Ga-DOTATOC PET/CT for restaging (A-D). (A) Whole body maximum intensity projection image demonstrates only moderate radiotracer uptake (arrowhead). On (B) axial CT, (C) axial PET, and (D) axial PET/CT, only modest radiotracer uptake is seen on the medial wall portion of the primary in the lung (red arrow). This has been classified as SSTR-RADS-3D by an experienced reader and further workup was recommended (Supplemental Table 1). Panels (E-G) display the succeeding 18F-FDG scan two weeks later. On (E) axial CT, (F) axial PET, and (G) axial PET/CT, intense radiotracer uptake is visualized in the lesion (double thin red arrows), which had shown almost no uptake on 68Ga-DOTATOC PET (flip-flop phenomenon).



Supplemental Figure 1.



Supplemental Figure 2.

MI-RADS classification (23)		PSMA- and SSTR-RADS (19,22)	Certainty of Malignancy	Workup	Uptake Level [#]	PRRT/RLT?
1	1A	✓ Benign lesion, characterized by biopsy or anatomic imaging <i>without</i> abnormal uptake	Definitively benign	n/a	1	N
	1B	✓ Benign lesion, characterized by biopsy or anatomic imaging <i>with</i> abnormal uptake		n/a	2-3	N
2		✓ Focal (low-level) uptake in a <i>soft tissue</i> site or <i>bone</i> lesion <i>atypical</i> for metastatic PCa or NEN	Likely benign	n/a	1	N
3	3A	✓ Equivocal uptake in <i>soft tissue lesion typical</i> of PCa or NEN	Equivocal	B, F/U	1-2	N
	3B	✓ Equivocal uptake in <i>bone lesion not atypical</i> of PCa or NEN		B, F/U	1-2	N
	3C	✓ Intense uptake in site <i>highly atypical</i> of all but advanced stages of PCa or NEN (i.e., high likelihood of nonprostatic/non-NET malignancy or other benign tumor)		B	3	N
	3D	✓ Lesion <i>suggestive of malignancy</i> on anatomic imaging but <i>lacking uptake</i> . For SSTR-RADS, an 18F-FDG PET/CT is recommended to rule out potential dedifferentiation of a single lesion.		B, F/U	not available	N [§]
4		✓ Intense uptake in site typical of PCa or NEN but <i>lacking</i> definitive findings on conventional imaging	Highly likely for PCa/NEN	n/a	3	Y
5		✓ Intense uptake in site typical of PCa or NEN and <i>with</i> definitive findings on conventional imaging	Definitively PCa/NEN	n/a	3	Y

Supplemental Table 1. Head-to-head comparison of both reporting and data systems (RADS) in molecular imaging (MI-RADS), which are Prostate-membrane specific antigen (PSMA)-RADS for evaluation of prostate cancer (PCa) and Somatostatin receptor (SSTR)-RADS for neuroendocrine neoplasias (NEN). PRRT = peptide receptor radionuclide therapy. RLT = radioligand therapy. N = No (endoradiotherapy not recommended). NEN = neuroendocrine neoplasias. B = Biopsy, F/U = follow-up imaging (3-6 months, e.g. depending on Ki67 in NEN). Y = Yes (endoradiotherapy recommended). # = applies only to SSTR-RADS. § = combined treatment may be applicable (e.g. in a G2 NEN patient with entirely all lesions demonstrating SSTR expression, but a single dedifferentiated lesion, a combined treatment of PRRT together with a locoregional procedure can be considered). Modified from *Werner et al., (23)*.

ACKNOWLEDGMENTS

Funding: Progenics Pharmaceuticals, The Prostate Cancer Foundation Young Investigator Award and National Institutes of Health grants CA134675, CA183031, CA184228, and EB024495. This project has received funding from the European Union's Horizon 2020 research and innovation program under the Marie Skłodowska-Curie grant agreement No 701983. Martin G. Pomper is a coinventor on a patent covering 18F-DCFPyL and is entitled to a portion of any licensing fees and royalties generated by this technology. This arrangement has been reviewed and approved by the Johns Hopkins University in accordance with its conflict-of-interest policies. He has also received research funding from Progenics Pharmaceuticals, the licensee of 18F-DCFPyL. Michael A. Gorin has served as a consultant to, and has received research funding from, Progenics Pharmaceuticals. Kenneth J. Pienta has received research funding from Progenics Pharmaceuticals. Steven P. Rowe has received research funding from Progenics Pharmaceuticals. No other potential conflicts of interest relevant to this article exist.

REFERENCES

1. Young DS. Standardized reporting of laboratory data: the desirability of using SI units. *N Engl J Med.* 1974;290:368-373.
2. Leslie KO, Rosai J. Standardization of the surgical pathology report: formats, templates, and synoptic reports. *Semin Diagn Pathol.* 1994;11:253-257.
3. Barentsz JO, Weinreb JC, Verma S, et al. Synopsis of the PI-RADS v2 guidelines for multiparametric prostate magnetic resonance imaging and recommendations for use. *Eur Urol.* 2016;69:41-49.
4. Padhani AR, Lecouvet FE, Tunariu N, et al. METastasis reporting and data system for prostate cancer: practical guidelines for acquisition, interpretation, and reporting of whole-body magnetic resonance imaging-based evaluations of multiorgan involvement in advanced prostate cancer. *Eur Urol.* 2017;71:81-92.
5. Lindner T, Loktev A, Altmann A, et al. Development of quinoline based theranostic ligands for the targeting of fibroblast activation protein. *J Nucl Med.* 2018.
6. Buck AK, Stolzenburg A, Hanscheid H, et al. Chemokine receptor - directed imaging and therapy. *Methods.* 2017;130:63-71.
7. Reynolds TS, Bandari RP, Jiang Z, Smith CJ. Lutetium-177 labeled bombesin peptides for radionuclide therapy. *Curr Radiopharm.* 2016;9:33-43.

8. Penet MF, Chen Z, Kakkad S, Pomper MG, Bhujwala ZM. Theranostic imaging of cancer. *Eur J Radiol.* 2012;81 Suppl 1:S124-126.
9. Baum RP, Kluge AW, Kulkarni H, et al. [(177)Lu-DOTA](0)-D-Phe(1)-Tyr(3)-Octreotide ((177)Lu-DOTATOC) for peptide receptor radiotherapy in patients with advanced neuroendocrine tumours: a phase-II study. *Theranostics.* 2016;6:501-510.
10. Kwekkeboom DJ, de Herder WW, Kam BL, et al. Treatment with the radiolabeled somatostatin analog [177 Lu-DOTA 0,Tyr3]octreotate: toxicity, efficacy, and survival. *J Clin Oncol.* 2008;26:2124-2130.
11. Strosberg JR, Halfdanarson TR, Bellizzi AM, et al. The north american neuroendocrine tumor society consensus guidelines for surveillance and medical management of midgut neuroendocrine tumors. *Pancreas.* 2017;46:707-714.
12. Strosberg J, El-Haddad G, Wolin E, et al. Phase 3 Trial of (177)Lu-Dotatate for Midgut Neuroendocrine Tumors. *N Engl J Med.* 2017;376:125-135.
13. Rowe SP, Pomper MG, Gorin MA. Molecular imaging of prostate cancer: choosing the right agent. *J Nucl Med.* 2018;59:787-788.
14. Hope TA, Afshar-Oromieh A, Eiber M, et al. Imaging prostate cancer with prostate-specific membrane antigen PET/CT and PET/MRI: current and future applications. *AJR Am J Roentgenol.* 2018;211:286-294.
15. Afshar-Oromieh A, Holland-Letz T, Giesel FL, et al. Diagnostic performance of (68)Ga-PSMA-11 (HBED-CC) PET/CT in patients with recurrent prostate cancer: evaluation in 1007 patients. *Eur J Nucl Med Mol Imaging.* 2017;44:1258-1268.
16. Derlin T, Schmuck S, Juhl C, et al. Imaging characteristics and first experience of [(68)Ga]THP-PSMA, a novel probe for rapid kit-based Ga-68 labeling and PET imaging: comparative analysis with [(68)Ga]PSMA I&T. *Mol Imaging Biol.* 2018;20:650-658.
17. Meignan M, Gallamini A, Meignan M, Gallamini A, Haioun C. Report on the first international workshop on interim-PET-Scan in lymphoma. *Leuk Lymphoma.* 2009;50:1257-1260.
18. Wahl RL, Jacene H, Kasamon Y, Lodge MA. From RECIST to PERCIST: evolving considerations for PET response criteria in solid tumors. *J Nucl Med.* 2009;50 Suppl 1:122S-150S.
19. Rowe SP, Pienta KJ, Pomper MG, Gorin MA. Proposal for a Structured Reporting System for Prostate-Specific Membrane Antigen-Targeted PET Imaging: PSMA-RADS Version 1.0. *J Nucl Med.* 2018;59:479-485.

20. Eiber M, Herrmann K, Calais J, et al. Prostate cancer molecular imaging standardized Evaluation (PROMISE): proposed miTNM classification for the interpretation of PSMA-ligand PET/CT. *J Nucl Med*. 2018;59:469-478.
21. Fanti S, Minozzi S, Morigi JJ, et al. Development of standardized image interpretation for ⁶⁸Ga-PSMA PET/CT to detect prostate cancer recurrent lesions. *Eur J Nucl Med Mol Imaging*. 2017;44:1622-1635.
22. Werner RA, Solnes LB, Javadi MS, et al. SSTR-RADS version 1.0 as a reporting system for SSTR PET imaging and selection of potential PRRT candidates: A proposed standardization framework. *J Nucl Med*. 2018;59:1085-1091.
23. Werner RA, Bundschuh RA, Bundschuh L, et al. MI-RADS: molecular imaging reporting and data systems - Introduction of PSMA- and SSTR-RADS for radiotracers with potential theranostic implications. *Ann Nucl Med*. 2018;32:512-522.
24. Chan DL, Pavlakis N, Schembri GP, et al. Dual somatostatin receptor/FDG PET/CT imaging in metastatic neuroendocrine tumours: proposal for a novel grading scheme with prognostic significance. *Theranostics*. 2017;7:1149-1158.
25. Sheikhabaei S, Afshar-Oromieh A, Eiber M, et al. Pearls and pitfalls in clinical interpretation of prostate-specific membrane antigen (PSMA)-targeted PET imaging. *Eur J Nucl Med Mol Imaging*. 2017;44:2117-2136.
26. Yin Y, Werner RA, Higuchi T, et al. Follow-up of lesions with equivocal radiotracer uptake on PSMA-targeted PET in patients with prostate cancer: Predictive values of the PSMA-RADS-3A and PSMA-RADS-3B categories. *J Nucl Med*. 2018.
27. Werner RA, Bundschuh RA, Bundschuh L, et al. Interobserver agreement for the standardized reporting system PSMA-RADS 1.0 on (18)F-DCFPyL PET/CT imaging. *J Nucl Med*. 2018.
28. Giesel FL, Hadaschik B, Cardinale J, et al. F-18 labelled PSMA-1007: biodistribution, radiation dosimetry and histopathological validation of tumor lesions in prostate cancer patients. *Eur J Nucl Med Mol Imaging*. 2017;44:678-688.
29. Werner RA, Sheikhabaei S, Jones KM, et al. Patterns of uptake of prostate-specific membrane antigen (PSMA)-targeted (18)F-DCFPyL in peripheral ganglia. *Ann Nucl Med*. 2017;31:696-702.
30. Rischpler C, Beck TI, Okamoto S, et al. (68)Ga-PSMA-HBED-CC uptake in cervical, coeliac and sacral ganglia as an important pitfall in prostate cancer PET imaging. *J Nucl Med*. 2018.
31. Fendler WP, Eiber M, Beheshti M, et al. (68)Ga-PSMA PET/CT: Joint EANM and SNMMI procedure guideline for prostate cancer imaging: version 1.0. *Eur J Nucl Med Mol Imaging*. 2017;44:1014-1024.

32. De Coster L, Sciot R, Everaerts W, et al. Fibrous dysplasia mimicking bone metastasis on (68)Ga-PSMA PET/MRI. *Eur J Nucl Med Mol Imaging*. 2017;44:1607-1608.
33. Gykiere P, Goethals L, Everaert H. Healing sacral fracture masquerading as metastatic bone disease on a 68Ga-PSMA PET/CT. *Clin Nucl Med*. 2016;41:e346-347.
34. Ardies PJ, Gykiere P, Goethals L, De Mey J, De Geeter F, Everaert H. PSMA uptake in mediastinal sarcoidosis. *Clin Nucl Med*. 2017;42:303-305.
35. Vamadevan S, Shetty D, Le K, Bui C, Mansberg R, Loh H. Prostate-specific membrane antigen (PSMA) avid pancreatic neuroendocrine tumor. *Clin Nucl Med*. 2016;41:804-806.
36. Lawhn-Heath C, Flavell RR, Glastonbury C, Hope TA, Behr SC. Incidental detection of head and neck squamous cell carcinoma on 68Ga-PSMA-11 PET/CT. *Clin Nucl Med*. 2017;42:e218-e220.
37. Rowe SP, Gorin MA, Hammers HJ, et al. Imaging of metastatic clear cell renal cell carcinoma with PSMA-targeted (1)(8)F-DCFPyL PET/CT. *Ann Nucl Med*. 2015;29:877-882.
38. Gorin MA, Rowe SP, Hooper JE, et al. PSMA-Targeted (18)F-DCFPyL PET/CT Imaging of Clear Cell Renal Cell Carcinoma: Results from a Rapid Autopsy. *Eur Urol*. 2017;71:145-146.
39. Cho SY. Proposed criteria positions PSMA PET for the future. *J Nucl Med*. 2018;59:466-468.
40. Luckerath K, Stuparu AD, Wei L, et al. Detection threshold and reproducibility of (68)Ga-PSMA11 PET/CT in a mouse model of prostate cancer. *J Nucl Med*. 2018.
41. Bennett C, Vakil N, Bergman J, et al. Consensus statements for management of Barrett's dysplasia and early-stage esophageal adenocarcinoma, based on a Delphi process. *Gastroenterology*. 2012;143:336-346.
42. Hindie E. The NETPET Score: Combining FDG and Somatostatin Receptor Imaging for Optimal Management of Patients with Metastatic Well-Differentiated Neuroendocrine Tumors. *Theranostics*. 2017;7:1159-1163.
43. Bodei L, Mueller-Brand J, Baum RP, et al. The joint IAEA, EANM, and SNMMI practical guidance on peptide receptor radionuclide therapy (PRRNT) in neuroendocrine tumours. *Eur J Nucl Med Mol Imaging*. 2013;40:800-816.
44. Arnold R, Chen YJ, Costa F, et al. ENETS consensus guidelines for the standards of care in neuroendocrine tumors: Follow-up and documentation. *Neuroendocrinology*. 2009;90:227-233.
45. Gennaro G. The "perfect" reader study. *Eur J Radiol*. 2018;103:139-146.

46. Szabo Z, Mena E, Rowe SP, et al. Initial Evaluation of $[(18)\text{F}]\text{DCFPyL}$ for Prostate-Specific Membrane Antigen (PSMA)-Targeted PET Imaging of Prostate Cancer. *Mol Imaging Biol.* 2015;17:565-574.
47. Willis BH, Beebee H, Lasserson DS. Philosophy of science and the diagnostic process. *Fam Pract.* 2013;30:501-505.
48. Johnson SA, Kumar A, Matasar MJ, Schoder H, Rademaker J. Imaging for staging and response assessment in lymphoma. *Radiology.* 2015;276:323-338.
49. Joo Hyun O, Lodge MA, Wahl RL. Practical PERCIST: A simplified guide to PET response criteria in solid tumors 1.0. *Radiology.* 2016;280:576-584.
50. Ceci F, Fanti S. Standardisation of PSMA images interpretation: why do we need it? *Clin Transl Imaging.* 2018;6.