

The Microvascular Peroneal Artery Perforator Flap as a "Lifeboat" for Pedicled Flaps

Rafael G. Jakubietz, MD*
 Danni F. Jakubietz, MD†
 Raymund E. Horch, MD‡
 Joerg G. Gruenert, MD§
 Rainer H. Meffert, MD*
 Michael G. Jakubietz, MD*

Background: Pedicled perforator flaps have expanded reconstructive options in extremity reconstruction. Despite preoperative mapping, intraoperative findings may require microvascular tissue transfer when no adequate perforators can be found. The free peroneal artery perforator flap may serve as a reliable back-up plan in small defects.

Methods: In 16 patients with small soft tissue defects on the upper and lower extremities, perforator-based propeller flaps were planned. The handheld Doppler device was used to localize potential perforators for a propeller flap in close proximity to the defect. Perforators of the proximal peroneal artery were also marked to allow conversion to microvascular tissue transfer.

Results: In 6 cases, no adequate perforators were found intraoperatively. In 4 patients, the peroneal artery perforator flap was harvested and transferred. The pedicle length did not exceed 4 cm. No flap loss occurred.

Conclusions: When no adequate perforator capable of nourishing a propeller flap can be found intraoperatively, the free peroneal artery flap is a good option to reconstruct small soft tissue defects in the distal extremities. The short vascular pedicle is less ideal in cases with a large zone of injury requiring a more distant site of anastomosis or when recipient vessels are located in deeper tissue planes. (*Plast Reconstr Surg Glob Open* 2019;7:e2396; doi: [10.1097/GOX.0000000000002396](https://doi.org/10.1097/GOX.0000000000002396); Published online 30 September 2019

INTRODUCTION

Although microvascular tissue transfer has become the gold standard to reconstruct complex defects in the lower extremity, recent developments based on anatomical studies and clinical experience have extended the reconstructive possibilities utilizing perforator-based local flaps.¹⁻⁴ Innovative methods such as tissue engineering are promising but are clinically not available yet.⁵⁻⁷ Microsurgically dissected pedicled perforator flaps have been shown to be a reliable and locally available method for soft tissue reconstruction of the distal extremities.^{1,3} However, despite preoperative mapping of the main perforators, intraoperative findings

may differ and render harvest of a pedicled flap impossible.^{8,9} Other local alternatives such as muscle flaps are limited in reach and often not available. Therefore, when planning a pedicled perforator flap, it is mandatory to have a reliable back-up plan if no adequate perforator is found intraoperatively.¹⁰ The free peroneal artery perforator flap is a useful and versatile flap because of its constant vascular anatomy.^{11,12} It can be harvested from the same extremity without sacrificing a main vessel of the leg. As primary closure of the donor site is possible up to 6 cm in width, it represents an alternative for defects amenable to propeller flap reconstruction. In this study, we describe the use of the free peroneal artery flap as an option when intraoperative findings do not allow harvesting a propeller flap.

MATERIAL AND METHODS

A retrospective chart analysis was carried out to identify patients who presented with isolated soft tissue defects of the distal lower and upper extremities over a 2-year period. Only patients considered candidates for propeller flap reconstruction were included. Patients with multilevel injuries of the same extremity, vascular injuries, and radiation defects were excluded. Before surgery, mapping of perforators adja-

From the *Department of Trauma-, Hand-, Plastic- and Reconstructive Surgery, University Hospital Wuerzburg, Germany; †Private Practice, Erlangen, Germany; ‡Department of Plastic- and Hand Surgery, University Hospital Erlangen, Germany; and § Department of Hand and Plastic Surgery, Kantonsspital St. Gallen, St. Gallen, Switzerland.

Received for publication April 5, 2019; accepted June 25, 2019.

Copyright © 2019 The Authors. Published by Wolters Kluwer Health, Inc. on behalf of The American Society of Plastic Surgeons. This is an open-access article distributed under the terms of the [Creative Commons Attribution-Non Commercial-No Derivatives License 4.0 \(CCBY-NC-ND\)](https://creativecommons.org/licenses/by-nc-nd/4.0/), where it is permissible to download and share the work provided it is properly cited. The work cannot be changed in any way or used commercially without permission from the journal.

DOI: [10.1097/GOX.0000000000002396](https://doi.org/10.1097/GOX.0000000000002396)

Disclosure: This publication was funded by the German Research Foundation (DFG) and the University of Wuerzburg in the funding programme Open Access Publishing.

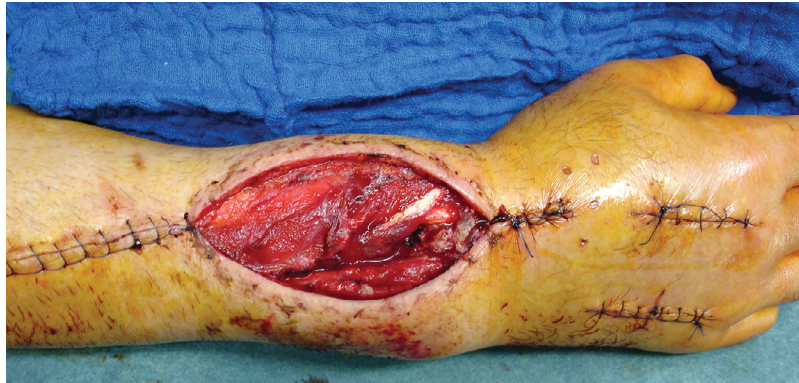

Fig. 1. Soft tissue defect after releasing a compartment syndrome and double plating of a comminuted distal radius fracture. Exposed extensor tendons second and third extensor compartments. Propeller flap planned from palmar forearm.

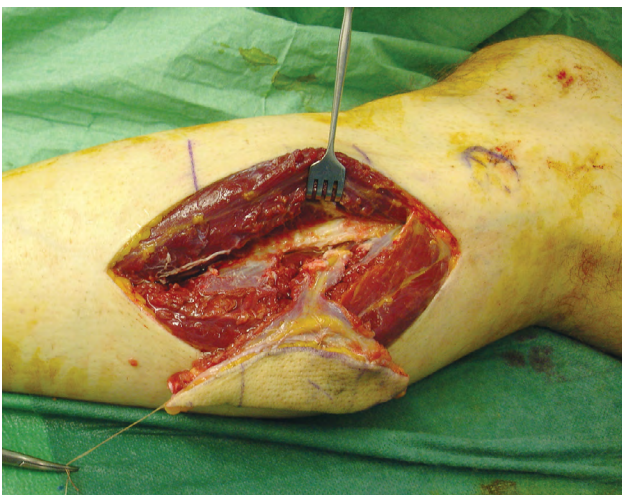


Fig. 2. Harvesting the peroneal artery perforator flap after encountering inadequate palmar perforators.

cent to the defect was carried out with a handheld Doppler probe. Cutaneous perforators of the peroneal artery were also marked as a rescue option. Surgery was performed without a tourniquet. Through an exploratory incision, the size

and location of preoperatively marked perforators were assessed. Only when an adequate perforator was found, a propeller flap was harvested. If no sizeable perforators could be located, other local options such as an advancement flap were evaluated. When no simple method was available, the free peroneal artery perforator flap was elevated and transferred. Data were analyzed in regard to mechanism of trauma, size and location of the defect, location of the perforator, reliability of the preoperative localization through Doppler sonography, and postoperative complications.

RESULTS

From June 2006 to July 2008, 16 patients (12 male, 4 female) with isolated soft tissue defects of the distal upper and lower extremities presented for reconstruction with propeller flaps. The average age was 52.3 years, with the postoperative follow-up of 11 months. Nine patients had posttraumatic defects, 4 patients experienced dehiscence and infection after orthopedic surgery, 1 patient presented with postburn contracture, 1 after tumor resection, and 1 with pressure ulceration (Figs. 1–3). On average, 2.6 surgical debridements were performed before soft tissue reconstruction. The defect size averaged 30.5 cm² ranging from 3 to 165 cm². In 6 patients, no ad-

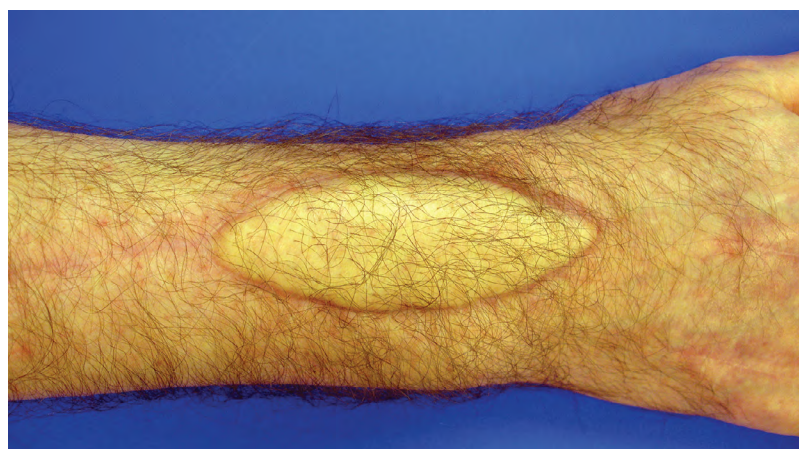


Fig. 3. Final result 9 months postoperatively displaying color mismatch.

Table 1. Demographic Data: Peroneal Artery Perforator Flap

Sex, Age	Comorbidities	Mode of Injury	Location, Size	Exposed Structure	Additional Surgery	Flap Size	Recipient Vessel	Color Mismatch	Complications
M, 31	Smoker	Fall from height, open radius fracture	Distal dorsal forearm, 28cm ²	Extensor tendons, hardware	Hardware exchange	35cm ²	Radial artery	Yes	None
F, 37	None	Motor vehicle accident, open tibia fracture	Distal ventral tibia, 9cm ²	Tibial bone, anterior tibial tendon	None	12cm ²	Anterior tibial artery	No	Hematoma at recipient site
M, 14	None	Lawn mower injury	Medial calcaneus, 16cm ²	Achilles tendon defect, calcaneus	Tendon reconstruction	24cm ²	Posterior tibial artery	No	None
M, 62	None	Dehiscence after tendon suture	Insertion achilles tendon, 36cm ²	Achilles tendon defect	Tendon reconstruction	50cm ²	Posterior tibial artery	No	Skin graft to donor site

equate perforators could be located intraoperatively. In 2 patients with small defects, a local advancement flap was available. In four cases, the free peroneal artery flap was used for immediate soft tissue reconstruction (Table 1). All flaps were harvested from the ipsilateral side. The flap size ranged from 12 to 50 cm². The pedicle length did not exceed 4 cm. The recipient vessels were the anterior tibial artery, the radial artery, and, in 2 cases, the posterior tibial artery. Only one vein was anastomosed in all flaps. The donor site was closed primarily in 3 patients, and in 1 case, a skin graft was required. No arterial or venous occlusion occurred during the postoperative course (Figs. 4–7). One patient developed a hematoma under the flap postoperatively, which was drained by suture release. This resulted in prolonged wound healing over 4 weeks. No flap loss occurred. One secondary thinning procedure was required. The color match was excellent in lower-extremity reconstruction, whereas a visible color mismatch resulted when transferred to the upper extremity (Fig. 3).

DISCUSSION

Perforator-based local flaps represent an increasingly popular option for soft tissue reconstruction of complex defects of the extremities.^{13–17} As these flaps are harvested adjacent to the defect, they offer the advantage of similar texture, thickness, and pliability to match the recipient site. Most flaps can be harvested in a suprafascial plane, thus minimizing donor site morbidity. Propeller flaps allow for a closure through a rotational transposition contrary to advancement flaps where the defect is closed by the approximation of potentially compromised wound edges.^{3,17–20} This may prove advantageous in complex wounds.

Preoperative planning of local perforator flaps is comparably simple. Most often, the handheld Doppler probe is used for the localization of potential perforators.^{3,8–10} Although the constant anatomy of perforators from the posterior tibial artery may preclude the use of a Doppler probe, we prefer to preoperatively verify the location of perforators as a lack of sizeable vessels leads to significantly more complex procedures. Besides the use of the Power Doppler, imaging tools such as near-infrared indocyanine green angiography (ICGA) may visualize the arterial perfusion pattern in the future.²¹ Other methods such as thermography and spectrometry are clinically not yet reliable enough for mapping perforators.^{22–24} In this series, only 1/3 of the patients with no sizable perforators were amenable to local advancement flap reconstruction. In 2/3 of cases, free tissue transfer was required for soft tissue reconstruction.

The free peroneal artery flap represents a good option when a thin and pliable flap is required.^{25,26} Its short vascular pedicle is adequate when recipient vessels are located superficially.^{27,28} To further increase reach, the pedicle may be planned eccentrically without compromising flap perfusion. Donor site morbidity is minimal both functionally and aesthetically. The flap is a popular choice for intraoral soft tissue reconstruction due to its pliability, minimal bulk, and relative hairlessness.²⁵ In the distal ex-

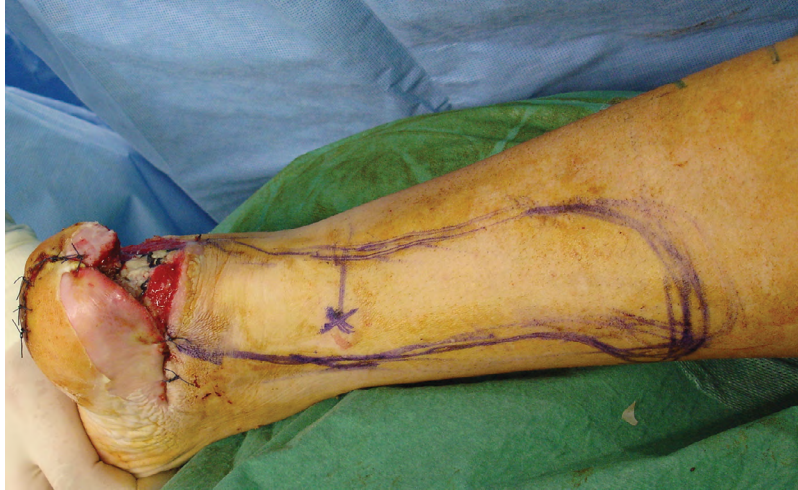

Fig. 4. A 14-year-old patient after lawn mower injury, Posterior-medial view. Propeller flap planned based on posterior tibial artery perforator.

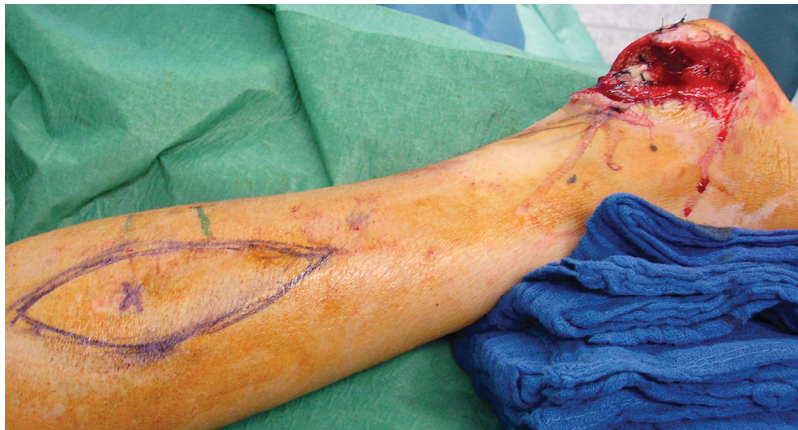

Fig. 5. Lateral view preoperatively, peroneal artery perforator marked.

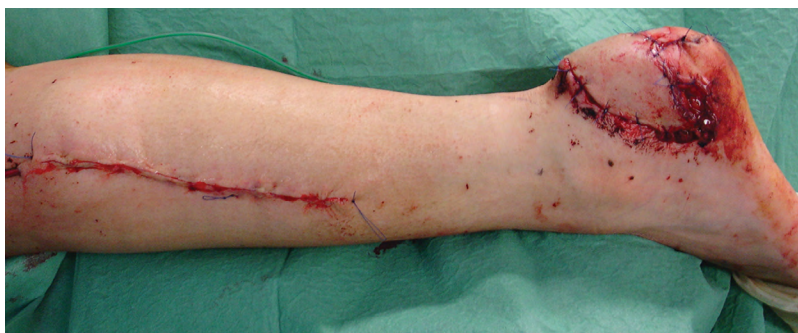

Fig. 6. Immediate postoperative view.

tremities, these qualities prove advantageous to allow the use of regular footwear. In upper-extremity defects, thin flaps improve cosmesis.²⁷ As the distal upper extremity is rarely covered by clothing, good color match is mandatory for an aesthetically acceptable outcome.^{29,30} We found that the peroneal artery flap showed a noticeable color mismatch when transferred to the upper extremity. This can be avoided with flaps harvested from the upper extremity,

which were not available in that patient. Despite this, all patients were pleased with the aesthetic result. In 1 case, a secondary procedure was required to improve cosmesis at the recipient site. One patient complained about a discoloration at the donor site.

The peroneal artery perforator flap is technically very demanding due to the small caliber of the perforator and its short pedicle. Contrary to other studies, we only achieved

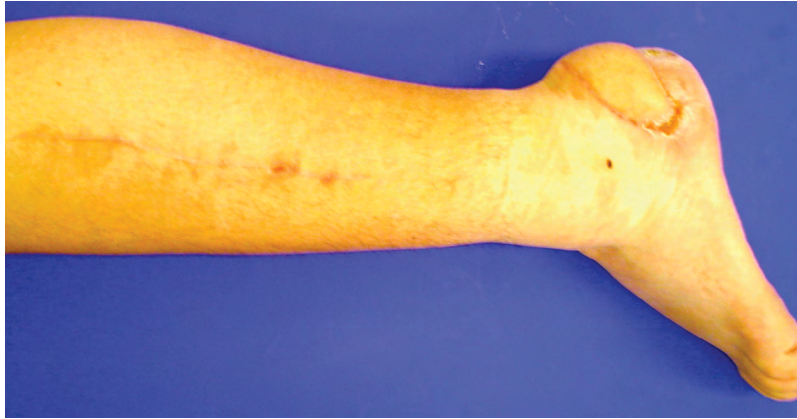

Fig. 7. Seven months postoperative result. Regular shoes can be worn.

a pedicle length of up to 4 cm.^{25–28} This might be too short when used in the lower extremity. Eccentric placement of the skin island may partially overcome this challenge. Despite the short and small pedicle, the ease of harvest outweighs the microsurgical challenge of the transfer.^{25–28} In distal extremity defects, it can be considered an alternative to the ALT flap in small defects in close proximity to the recipient vessels.²⁷ If the zone of injury requires a longer pedicle, we consider the peroneal artery perforator flap less ideal. In these cases, the ALT flap supplies a much longer vascular pedicle with a significantly larger vessel size. This improves reach and tailors to a more proximal site of the anastomosis. The thicker fat layer generally found in the ALT flap can be thinned to match the contour of distal defects, either primarily or at a second stage.

This study has limitations due to its retrospective nature and small sample size. Further studies are needed to evaluate specific indications favoring the peroneal artery flap over other perforator flaps in soft tissue reconstruction of the extremities.

CONCLUSIONS

We consider the peroneal artery perforator flap as an option for soft tissue defects amenable to reconstruction with pedicled perforator flaps. However, if extensive soft tissue damage adjacent to the defect rules out the use of local perforator flaps, the short vascular pedicle inherent to the peroneal artery perforator flap makes this flap a suboptimal choice. Based on our own and other authors' experiences from the literature, we prefer perforator flaps with a long vascular pedicle such as the ALT flap in these circumstances over the peroneal artery perforator flap.

Rafael G. Jakubietz, MD

Department of Trauma-, Hand-, Plastic-
and Reconstructive Surgery
University Hospital Wuerzburg
Oberduerrbacherstr. 6
DE-97080 Wuerzburg, Germany
Tel: 0049 931 201 37001
Fax: 004993120137035
E-mail: Jakubietz_R@ukw.de

REFERENCES

1. Bekara F, Herlin C, Somda S, et al. Free versus perforator-pedicled propeller flaps in lower extremity reconstruction: what is the safest coverage? A meta-analysis. *Microsurgery*. 2018;38:109–119.
2. Hallock GG. A paradigm shift in flap selection protocols for zones of the lower extremity using perforator flaps. *J Reconstr Microsurg*. 2013;29:233–240.
3. Teo TC. The propeller flap concept. *Clin Plast Surg*. 2010;37:615, vi–626, vi.
4. Jakubietz RG, Jakubietz MG, Gruenert JG, et al. The 180-degree perforator-based propeller flap for soft tissue coverage of the distal, lower extremity: a new method to achieve reliable coverage of the distal lower extremity with a local, fasciocutaneous perforator flap. *Ann Plast Surg*. 2007;59:667–671.
5. Robering JW, Weigand A, Pfuhlmann R, et al. Mesenchymal stem cells promote lymphangiogenic properties of lymphatic endothelial cells. *J Cell Mol Med*. 2018 May 11.
6. Yuan Q, Arkudas A, Horch RE, et al. Vascularization of the arteriovenous loop in a rat isolation chamber model-quantification of hypoxia and evaluation of its effects. *Tissue Eng Part A*. 2018;24:719–728.
7. Weigand A, Beier JP, Schmid R, et al. Bone tissue engineering under xenogeneic-free conditions in a large animal model as a basis for early clinical applicability. *Tissue Eng Part A*. 2017;23:208–222.
8. Khan UD, Miller JG. Reliability of handheld doppler in planning local perforator-based flaps for extremities. *Aesthetic Plast Surg*. 2007;31:521–525.
9. Jakubietz RG, Jakubietz MG, Grünert JG, et al. Propeller flaps: the reliability of preoperative, unidirectional doppler sonography. *Handchir Mikrochir Plast Chir*. 2011;43:76–80.
10. Jakubietz RG, Jakubietz DF, Gruenert JG, et al. Reconstruction of soft tissue defects of the achilles tendon with rotation flaps, pedicled propeller flaps and free perforator flaps. *Microsurgery*. 2010;30:608–613.
11. Heitmann C, Khan FN, Levin LS. Vasculature of the peroneal artery: an anatomic study focused on the perforator vessels. *J Reconstr Microsurg*. 2003;19:157–162.
12. Deng C, Wu B, Wei Z, et al. Interperforator flow pattern and clinical application of distal extended peroneal artery perforator flaps. *Ann Plast Surg*. 2018;80:546–552.
13. Wong JK, Deek N, Hsu CC, et al. Versatility and “flap efficiency” of pedicled perforator flaps in lower extremity reconstruction. *J Plast Reconstr Aesthet Surg*. 2017;70:67–77.
14. Cheng L, Yang X, Chen T, et al. Peroneal artery perforator flap for the treatment of chronic lower extremity wounds. *J Orthop Surg Res*. 2017;12:170.

15. Gir P, Cheng A, Oni G, et al. Pedicled-perforator (propeller) flaps in lower extremity defects: a systematic review. *J Reconstr Microsurg.* 2012;28:595–601.
16. Nelson JA, Fischer JP, Brazio PS, et al. A review of propeller flaps for distal lower extremity soft tissue reconstruction: is flap loss too high? *Microsurgery.* 2013;33:578–586.
17. Jakubietz RG, Schmidt K, Zahn RK, et al. Subfascial directionality of perforators of the distal lower extremity: an anatomic study regarding selection of perforators for 180-degree propeller flaps. *Ann Plast Surg.* 2012;69:307–311.
18. Dong KX, Xu YQ, Fan XY, et al. Perforator pedicled propeller flaps for soft tissue coverage of lower leg and foot defects. *Orthop Surg.* 2014;6:42–46.
19. Jakubietz RG, Jakubietz MG, Jakubietz DF, et al. Ischial pressure sores: reconstruction using the perforator-based reverse flow musculocutaneous 180 degrees propeller flap. *Microsurgery.* 2009;29:672–675.
20. Innocenti M, Menichini G, Baldrighi C, et al. Are there risk factors for complications of perforator-based propeller flaps for lower-extremity reconstruction? *Clin Orthop Relat Res.* 2014;472:2276–2286.
21. Ludolph I, Arkudas A, Schmitz M, et al. Cracking the perfusion code?: laser-assisted indocyanine green angiography and combined laser doppler spectrophotometry for intraoperative evaluation of tissue perfusion in autologous breast reconstruction with DIEP or ms-TRAM flaps. *J Plast Reconstr Aesthet Surg.* 2016;69:1382–1388.
22. Rother U, Lang W, Horch RE, et al. Pilot assessment of the angiosome concept by intra-operative fluorescence angiography after tibial bypass surgery. *Eur J Vasc Endovasc Surg.* 2018;55:215–221.
23. Buehrer G, Taeger CD, Ludolph I, et al. Intraoperative flap design using ICG monitoring of a conjoined fabricated anterolateral thigh/tensor fasciae latae perforator flap in a case of extensive soft tissue reconstruction at the lower extremity. *Microsurgery.* 2016;36:684–688.
24. Kneser U, Beier JP, Schmitz M, et al. Zonal perfusion patterns in pedicled free-style perforator flaps. *J Plast Reconstr Aesthet Surg.* 2014;67:e9–e17.
25. Wolff KD, Rau A, Kolk A. Perforator flaps from the lower leg for intraoral reconstruction: experience of 131 flaps. *J Craniomaxillofac Surg.* 2018;46:338–345.
26. Wolff KD, Bauer F, Wylie J, et al. Peroneal perforator flap for intraoral reconstruction. *Br J Oral Maxillofac Surg.* 2012;50:25–29.
27. Scaglioni MF, Kuo YR, Chen YC. Reconstruction of distal hand and foot defects with the free proximal peroneal artery perforator flap. *Microsurgery.* 2016;36:183–190.
28. Ozkan O, Ozkan O, Cinpolat A, et al. Reconstruction of distal lower extremities defect using the free peroneal artery perforator vessel based flap. *Microsurgery.* 2014;34:629–632.
29. Jakubietz RG, Jakubietz MG, Kloss D, et al. Defining the basic aesthetics of the hand. *Aesthetic Plast Surg.* 2005;29:546–551.
30. Rehim SA, Kowalski E, Chung KC. Enhancing aesthetic outcomes of soft-tissue coverage of the hand. *Plast Reconstr Surg.* 2015;135:413e–428e.