

Muscle Cuff in Distal Pedicled Adipofascial Sural Artery Flaps: A Retrospective Case Control Study

Karsten Schmidt, MD*
 Michael Georg Jakubietz, MD
 Fabian Gilbert, MD
 Annabel Fenwick, MD
 Reiner Heribert Meffert, MD
 Rafael Gregor Jakubietz, MD

Background: Amputation after open tibial fracture occurs in 3% of cases. The rate increases when flap reconstruction is required. The standard care involves microsurgical tissue transfer although the pedicled reverse sural artery adipofascial flap (PRSAF) is a local alternative in patients endangered by a prolonged operative time. Incorporation of a gastrocnemius muscle cuff in this flap can be used to fill dead space and increase healing potential. Literature shows superior survival rates for both PRSAF and inclusion of a muscle cuff in comparison with the cutaneous version. The aim of the study was to compare the outcome of the PRSAF and the musculoadipofascial version (PRSMAF). We hypothesize that the PRSMAF provides similar flap viability and flap-related complication rates as does the adipofascial version. The muscle component may reduce the long-term osteomyelitis rate.

Methods: Patients were evaluated retrospectively after reconstruction with either PRSAF or PRSMAF. Preoperative osteomyelitis, flap survival, complications and osteomyelitis clearance were analyzed.

Results: The study shows preliminary results supporting the potential use of the PRSMAF. We compare either 23 PRSMAF or 20 PRSAF flaps. We found no statistically significant differences in flap survival or in complication rate.

Conclusions: Although the anatomical situation may sometimes dictate the use of a free flap, a technically less-complicated option may in some cases offer a viable alternative. This study shows that the PRSMAF can serve as an alternative for complex bone defects in the limb, though it does not provide statistical improvement to the PRSAF. (*Plast Reconstr Surg Glob Open* 2021;9:e3464; doi: 10.1097/GOX.0000000000003464; Published online 26 March 2021.)

INTRODUCTION

High energy trauma is the leading cause of open fractures of the lower extremity, which often require both bone and soft tissue reconstruction. Due to the soft tissue in this region, these injuries result in deep, contaminated defects, which cannot be addressed by orthopedic surgery alone. The rate of amputation after an open tibial fracture is 3.6%.¹ This rate increases if the soft tissue defect requires flap reconstruction.¹ The treatment options for filling and closing these defects are numerous, and a frequent source of discussion and debate among plastic surgeons. The current standard of care involves microsurgical tissue transfer.²⁻⁴

The pedicled reverse sural artery fasciocutaneous flap, a well described procedure for reconstruction of the distal lower leg,^{5,6} is an easy and quick-to-perform local flap with small donor-site impact. This may be an advantage in elderly and weak patients. However, although the pedicled reverse fasciocutaneous sural artery flap's thin and pliable structure is ideal for surface recontouring in the ankle region, it is not as suitable to fill bone defects with potential dead space. The literature supports the concept of dead-space elimination with muscle flaps,³ of which there are free and pedicled variants. Free muscle flaps cause functional deficit⁷ and are more technically challenging than pedicled flaps.⁸ In contrast, a pedicled flap containing only a small section of the muscle avoids both of these issues. This study explores the addition of such a muscle cuff to the the pedicled reverse sural artery

From the Department of Trauma, Hand, Plastic and Reconstructive Surgery, Julius Maximilians Universität Wuerzburg, Wuerzburg, Germany.

Received for publication March 31, 2020; accepted January 7, 2021.

Copyright © 2021 The Authors. Published by Wolters Kluwer Health, Inc. on behalf of The American Society of Plastic Surgeons. This is an open-access article distributed under the terms of the Creative Commons Attribution-Non Commercial-No Derivatives License 4.0 (CCBY-NC-ND), where it is permissible to download and share the work provided it is properly cited. The work cannot be changed in any way or used commercially without permission from the journal.

DOI: 10.1097/GOX.0000000000003464

Disclosure: *The authors have no financial interest to declare in relation to the content of this article. This study was supported by the German Research Foundation (DFG) and the University of Wuerzburg in the funding program for Open Access Publishing.*

Related Digital Media are available in the full-text version of the article on www.PRSGlobalOpen.com.

adipofascial flap (PRSAF) to create the musculo-adipofascial modification of the sural flap (PRSMAF).

The survival of a transplanted flap is paramount in reconstructive surgery. One method described for increasing flap survival rates involves combination with a muscle cuff to improve venous drainage.⁹ For the pedicled reverse fasciocutaneous sural artery flap, another option is the reduction of the length/width ratio and sparing of the skin island.¹⁰⁻¹² A recent systematic analysis of suralis flap modifications has shown better survival rates with the adipofascial modification as well as with the musculocutaneous variant when compared with the fasciocutaneous version.¹³ The PRSMAF takes advantage of both approaches through the use of a muscle cuff and the elimination of the skin island. To improve reliability and therapeutic potential of the fasciocutaneous sural flap, the authors combined the adipofascial variant with a muscle cuff from the gastrocnemius muscle. A review of available literature resulted in only a single case report of this flap modification.¹⁴

The reliability of the new flap design was investigated in a retrospective clinical case control study comparing the long-term results and the complications in 2 groups of adipofascial flaps, 1 with and 1 without muscular sealing. The objective of the study was to evaluate the results of this modified technique, and explore whether it ensures sufficient viability of the flap. Because improved perfusion may help prevent osteomyelitis in patients with infected bone defects, the study included a review of late osteogenic complication.

The foregoing considerations led to the hypothesis that the PRSMAF provides the same flap viability and flap-related complication rate (revision surgery, secondary closure, secondary mesh graft, and infection) as the PRSAF. In addition, the authors postulated a long-term improvement in bone recovery, represented by the absence of clinical and radiological signs of osteitis or osteomyelitis after 6 months.

METHODS

All medical records of patients between 2012 and 2019 who received a soft tissue reconstruction after open fracture of the distal leg with either a PRSAF or a PRSMAF were included. These patients were then analyzed in a retrospective, single center, IRB-approved case control study. Further patient selection was then performed according to the following inclusion criteria:

- a. Defect of the distal lower extremity with exposed bone, tendon, osteosynthetic implants or neurovascular structures requiring filling of dead space
- b. Age of the patient >18
- c. Transfer of either a PRSAF or PRSMAF as surgical technique
- d. Complete medical records

The exclusion criteria were:

- a. Incomplete records
- b. Non-compliance
- c. Any acute or chronic conditions that would limit the ability of the patient to participate in the study
- d. Refusal to give informed consent.

Forty-three patients were included in this study. Common comorbidities were distributed equally among both groups (Table 1).

Preoperative wound swabs for microbiological assessment were collected from all patients. Patients with positive bacterial wound cultures received surgical debridement and culture-specific antibiotic therapy before flap closure was attempted.

All patients were treated perioperatively with a second-generation cephalosporine. In cases with positive bacterial wound cultures, the antimicrobial therapy was adjusted accordingly.

The surgical technique for harvesting the PRSAF has been described in great detail by the authors in a previous publication.¹⁵ For the PRSMAF, the procedure was modified to include muscle tissue from the gastrocnemius muscle around the main perforating vessel. The dissection was begun distally and extended proximally. The size of the muscle cuff used was dependent on the size of the defect. Viability of the muscle cuff was confirmed intraoperatively by signs of macroscopic bleeding and direct visualization of the vascular pedicle. The elevated flap was then rotated 180 degrees, and the muscle tissue was used to seal the cavity. To avoid compression of the pedicle, it was externalized and never tunneled. A meshed split skin graft was placed over the flap and pedicle in all cases. Primary wound closure at the donor site was always performed. Easy-flow drainages were placed at the flap site, and one redon drainage was used at the donor site. Duration of every operation was recorded (Figs. 1–4). (See Video [online], which displays the recorded operation.)

The operated leg was elevated postoperatively for 5 days to encourage reverse venous flow. After this period, the patients were fitted with compression stockings to prevent flap edema and aid contouring. Time of hospitalization was recorded. Patients were asked to return regularly for follow-up examinations after discharge. The last of these follow-up visits took place 6 months postoperatively, at which point a clinical examination was performed, and photographic and x-ray documentations were recorded. Walking ability was assessed by clinical examination and questioning of the patient.

Flap survival was defined as complete wound closure by discharge. Complications or partial flap survival were recorded in cases that required secondary suturing or mesh grafting, or any kind of surgical revision within 6 weeks postoperatively. Early postoperative results were recorded within 5 days after surgery. These were quantified through clinical examination and x-ray imaging. The postoperative vitality of the muscle cuff was defined by the absence of necrosis, infection, and abnormal

Table 1. Comorbidities

| | Total Patients | Diabetes (<i>P</i> = 0.99, ns) | Hypertension (<i>P</i> = 0.07, ns) | CAD (<i>P</i> = 0.89, ns) | Obesity (<i>P</i> = 0.83 ns) |
|--------|----------------|------------------------------------|--|-------------------------------|----------------------------------|
| PRSMAF | 23 | 8 (35%) | 8 (35%) | 4 (17%) | 6 (26%) |
| PRSAF | 20 | 7 (35%) | 8 (40%) | 3 (15%) | 6 (30%) |

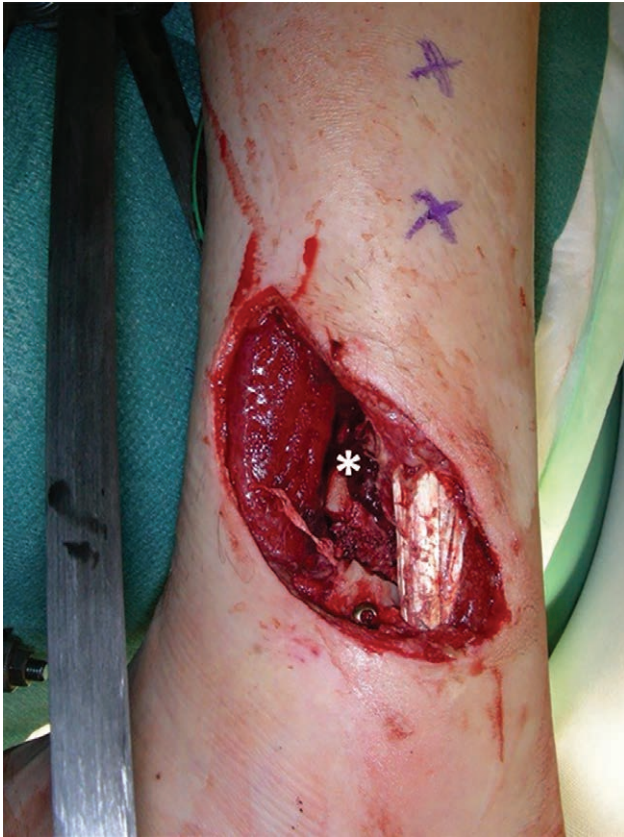

Fig. 1. Preoperative situs. *Tibial fracture with exposed bone and implanted screw.

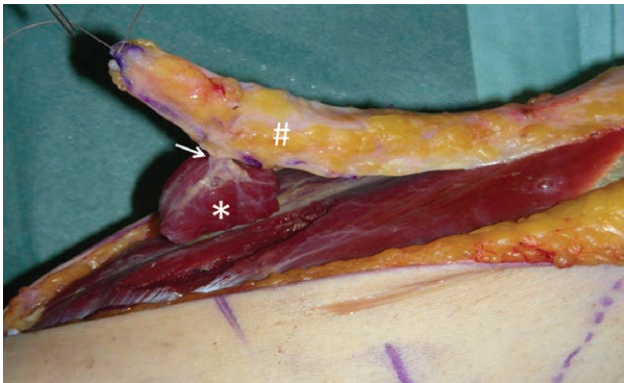


Fig. 2. Intraoperative situs with elevated PRSMAF. #Adipofascial flap; →perforating artery to the muscle; *incorporated muscle cuff.

liquid formation. Infection was detected through clinical evaluation and wound swabs in case of revision. Postoperative bone complications were assessed by clinical and x-ray evaluation for all patients. In individual cases, follow-up CT and MRI scans were available to review as well.

The osteomyelitis clearance effect was defined as normal bone healing with no signs of infection 6 months after a proven preoperative wound and bone infection. Perfusion and venous congestion were not directly quantified via technical devices like ICG scan or Doppler flow

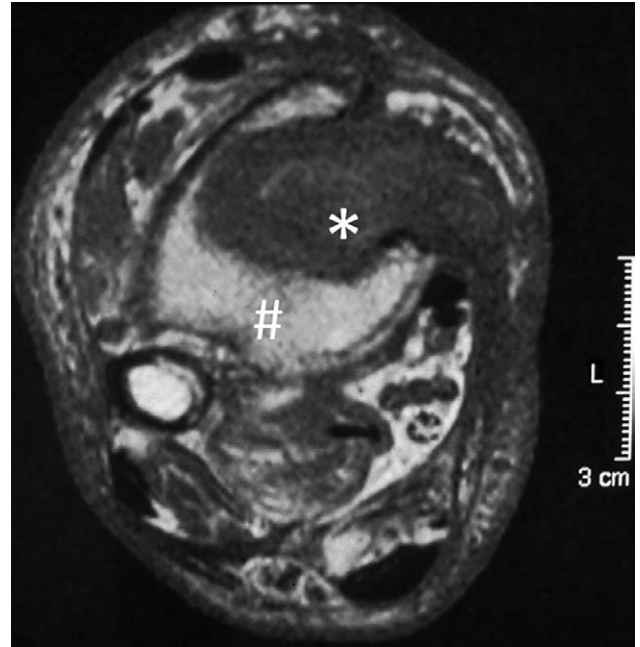


Fig. 3. MRI 6 months postoperative. # Large bone defect of the distal tibia; *sealed with vital muscle cuff.

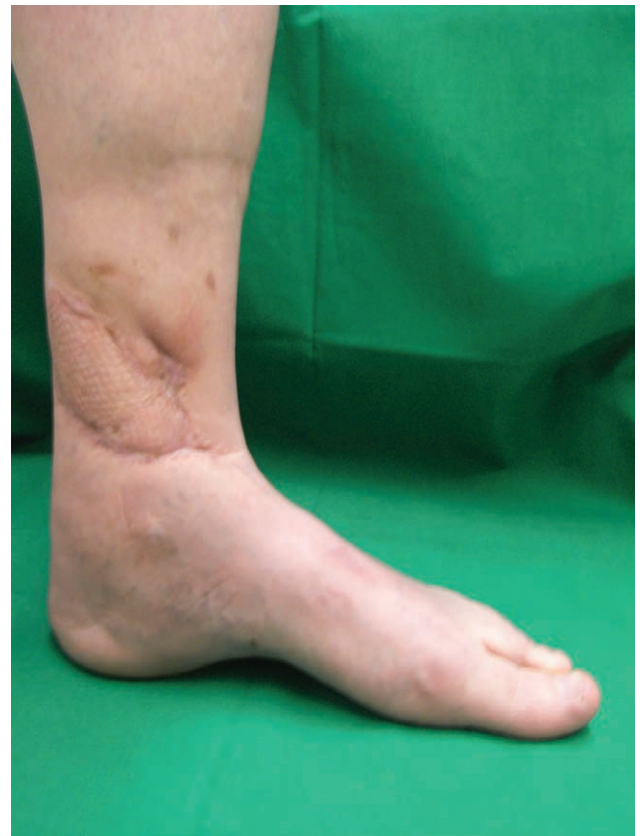

Fig. 4. Long-term result of a PRSMAF 6 months postoperative.

scan. MRI scans to assess perfusion were performed only in individual cases and thus not eligible for statistical analysis.

The primary endpoint of the study was flap survival after 6 months; secondary endpoint was status of osteomyelitis after 6 months. This study was approved by the institutional ethics committee. Statistical analysis was performed by SPSS 22.0. Independent variables not normally distributed were analyzed using a Kruskal-Wallis test, continuous variables using a *t* test and non-parametric variables using a Mann-Whitney U test. Differences were considered statistically significant when $P < 0.05$.

RESULTS

Of the 43 patients included in this study, 23 were treated with a PRSMAF. One patient required a PRSMAF on both legs. In total, the cohort included 34 men and 9 women. The PRSMAF-group included 17 men and 6 women; the PRSAF-group had 17 men and 3 women. The overall mean age was 55 years; 54 years in the PRSMAF-cohort and 57 years in the PRSAF-group.

All defects were the result of traumatic injuries to the distal lower limb, and all included exposed bone or tendon tissue. In total, 51% of injuries were primarily open fractures [22 in total; 12 PRSMAF (52%), 10 PRSAF (50%)]. Four cases [18%, 2 PRSMAF (9%), 2 PRSAF (10%)] of the open fractures were classified as Gustilo 3a, 8 cases [36%, 4 PRSAF (17%), 4 PRSMAF (20%)] as Gustilo 2, and 10 cases [45%, 6 PRSMAF (26%), 4 PRSAF (20%)] as Gustilo 1. The groups did not differ in the distribution statistics.

In total, 14 (32%) of the patients showed preoperatively exposed osteosynthesis implants. Of these, 6 were in the PRSMAF-group (26%) and 8 in the PRSAF-group (40%), $P = 0.43$.

Preoperative wound swabs confirmed bacterial contamination in 17 (39%) cases: 9 (39%) in the PRSMAF-group and 8 (40%) in the PRSAF-group ($P = 0.96$). The microbiological results of the PRSMAF-group included Staphylococcus, Klebsiella, Moraxella, *Serratia marcescens*, and Enterococcus. The PRSAF-group included 7 cases of Staphylococcus and 1 case of MRSA, as well as *Escherichia*

coli, Enterococcus, *Pseudomonas aeruginosa*, Klebsiella, and Micrococcus. There was no statistically relevant difference between the groups.

Primary wound closure was achieved in all cases. No patient suffered a complete loss of the flap within the follow-up period.

The average total procedure time was 86 minutes (SD 43.1) in the PRSMAF-group and 93 minutes (SD 58.64) in the PRSAF-group ($P = 0.78$). The difference was not statistically significant (Fig. 5). Clinical signs of temporary venous stasis (swelling of the flap, dark bleeding, and blue change of color) were observed in 6 (26%) patients in the PRSMAF-group and 7 (35%) patients in the PRSAF-group ($P = 0.62$, ns). Perfusion and venous drainage were not otherwise systematically measured and could therefore not be quantified.

Five (22%) patients in the PRSMAF-group showed postoperative complications. Four cases of superficial wound infection were treated by a second mesh graft. Three cases required revision due to osteomyelitis. One patient underwent amputation due to spreading osteomyelitis and empyema of the ankle, despite a vital sural flap. In the PRSAF-group, 6 (30%) cases had complications. Two cases of superficial necrosis were successfully treated with mesh grafting. One patient required revision after wound dehiscence. Four patients had further operations due to osteomyelitis. In 1 case, ankle arthrodesis was performed. The differences in complications between the PRSMAF and PRSAF groups were not statistically significant ($P = 0.68$) (Figs. 6, 7).

PRSMAF patients stayed in hospital for 12 days (SD 3.8), whereas PRSAF patients spent 13 days on average (SD 6.8). The difference is not statistically relevant ($P = 0.96$). No patients reported a loss of muscular strength of the calf. Six months postoperatively, flap-related walking ability in the affected leg was compared with the uninjured leg, and patients were interviewed about limitations in strength and movement. In both groups, patients reported a median of 9 on a movement scale of 0 to 10

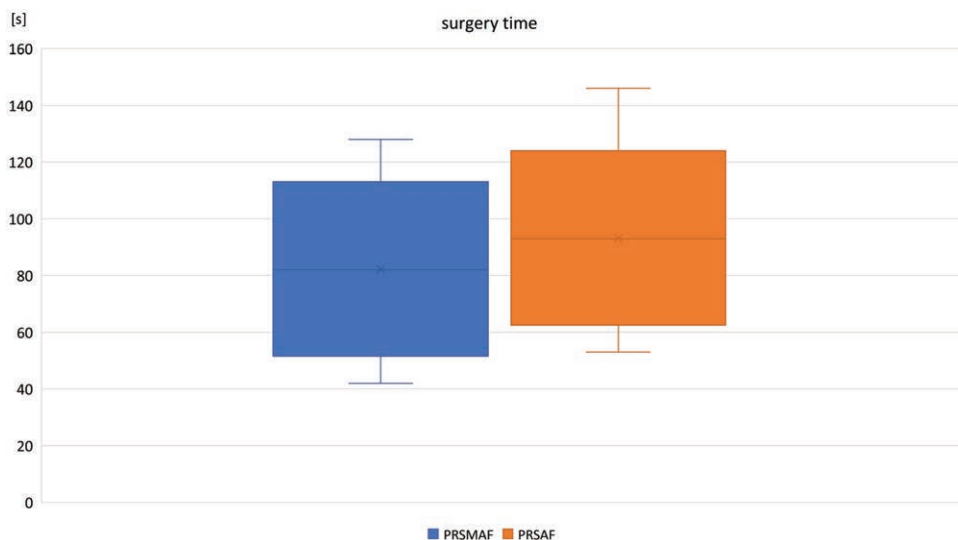


Fig. 5. Operating Time of PRSMAF (SD 43.1) and PRSAF (SD 58.6) $P = 0.78$.

(0 = no movement possible in the affected leg; 10 = equal range of movement and strength in both legs).

Nine (39%) wounds with the infected bone were treated in the PRSMAF-group. Five (17%) of these showed no signs of osteomyelitis after 6 months, resulting in a clearance rate of 56%. In the PRSAF-group, the clearance rate was 50% ($P = 0.95$). The overall risk of developing osteomyelitis was 20% in the PRSAF-group and 17% in the PRSMAF-group ($P = 0.92$). The differences between the groups were not statistically significant (Fig. 8).

DISCUSSION

The distally pedicled sural artery flap was first mentioned by Masquelet⁵ and described shortly afterward by Hasegawa et al.⁶ The high complication rate associated with the flap has made the fasciocutaneous version, in

particular, the subject of much discussion.¹⁶ The main complication associated with the total loss of the flap is venous congestion.^{17,18} In an attempt to negate this problem, surgeons have developed several modifications to the original flap. These include techniques such as flap delay¹⁹ and microsurgical venous augmentation,²⁰ neither of which have reached widespread acceptance. In a recent breakthrough, research groups were able to demonstrate that a minimum pedicle width, combined with limited flap length and a more distally located skin island, lead to an increased survival rate.²¹ Another technique developed in an effort to minimize flap loss and reduce venous congestion is the elimination of the skin area.^{11,12}

A meta-analysis of 900 patients with sural artery flaps recorded a complication rate of 26%, with 3% total losses and 9% partial necrosis. Neurological affections were found to convey a protective advantage, but the delay

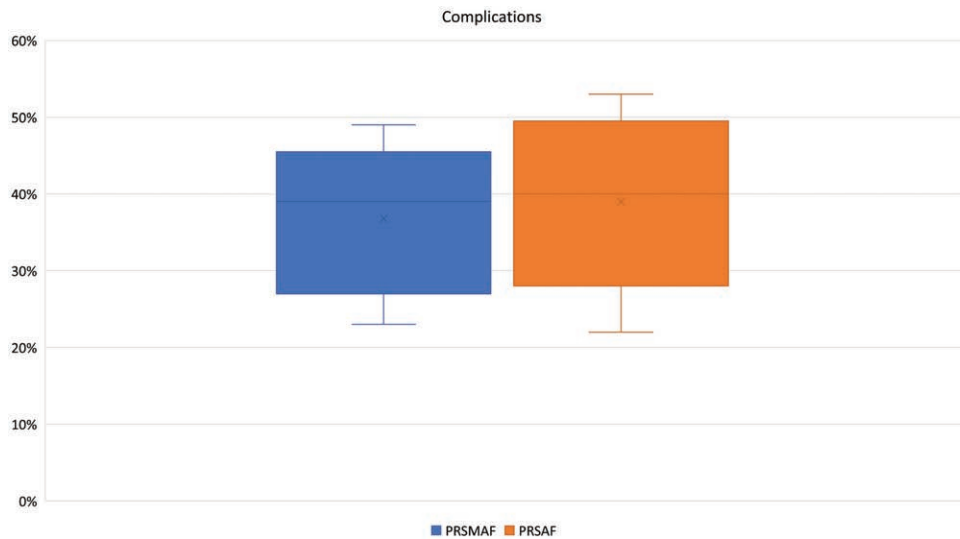


Fig. 6. Rate of complications of PRSMAF and PRSAF.

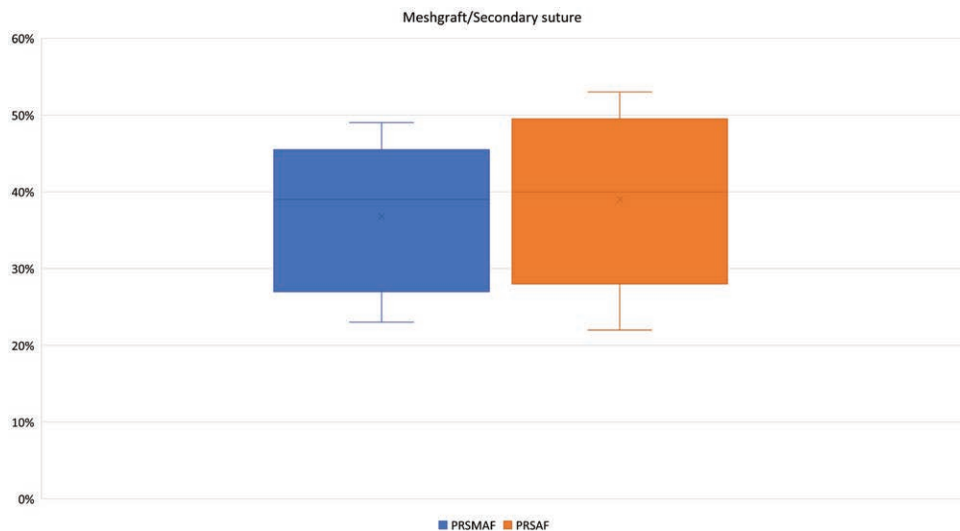


Fig. 7. Rate of revision surgery (secondary closure or secondary mesh graft transplantation).

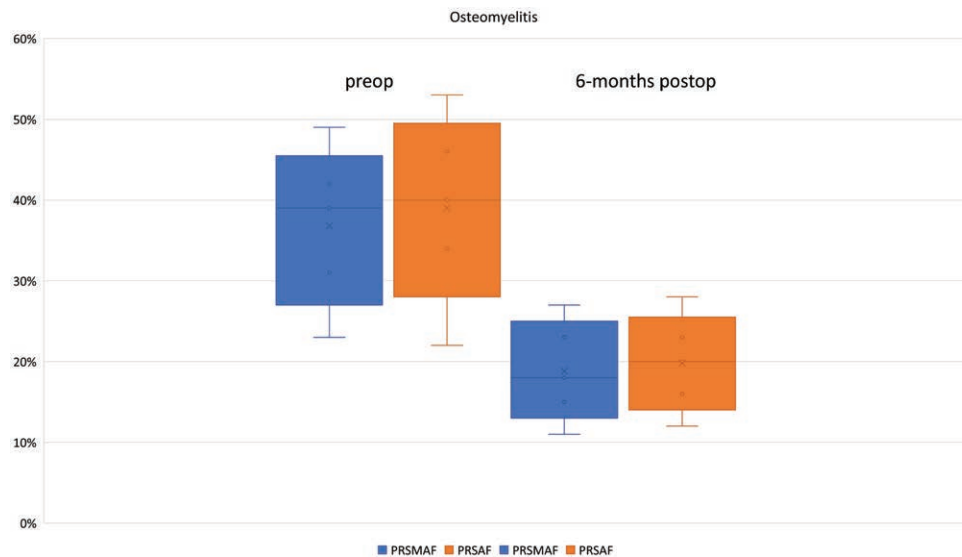


Fig. 8. Osteomyelitis clearance of PRSMAF and PRSAF in comparison: preoperative percentage and long-term outcome.

technique did not significantly improve outcomes.²² Despite all efforts to improve flap technique, venous congestion remained a leading cause for complications.^{17,18}

A separate systematic analysis of the literature compared modifications of more than 5000 pedicled reverse sural artery flaps, where modifications like PRSAFs or PRSMCFs (pedicled reverse sural artery myocutaneous flaps) showed the lowest flap failure rates in this analysis.¹³

The use of a muscle cuff to seal deep-infected bone defects with existing dead-space has previously been shown to improve patient outcomes.²³ It has been postulated that this muscular sealing of defects provides antimicrobial and immunological advantages.²⁴ Additionally, the muscle cuff may improve venous return.⁹

In the current study, inclusion of the muscle cuff did not show negative effects such as increased operative time or donor site morbidity. The authors hypothesized that the combination of the adipofascial sural artery flap with a gastrocnemius muscle cuff helps achieve 2 goals in a single maneuver: improving perfusion and simultaneously filling dead space. This approach adds simple modifications to a well-described surgical technique that is well perceived regarding long-term quality of life in postoperative patients.²⁵ Although the authors were not able to statistically define advantages of this new technique, they observed no evident drawbacks in comparison with the classic sural artery flap. Although more primary-infected group bones than the PRSAF healed after 6 months, this effect was not statistically evident. The results correlate with the data from a recent analysis of more than 5000 PRSFs, where modifications like PRSAFs or PRSMCFs showed improved survival rates but not at a statistically relevant level.¹³

LIMITATIONS

The power of the study could be greatly increased through a multi-centre, prospective, blinded, controlled

approach with a greater number of patients. In this study, perfusion and venous drainage of the flap was not systematically and quantifiably measured, and could therefore not lend support to 1 hypothesis over another. In future studies, direct quantitative measurement of blood flow through the use of ICG-fluorescence or perfusion MRI scans could shed light on this topic.

CONCLUSIONS

This study demonstrates that the pedicled reverse sural artery musculoadipofascial flap is a viable treatment option for deep bony lower limb defects. The inclusion of the muscle spindle in the classic sural artery flap does not result in longer surgery times and donor site morbidities remain comparable. The new technique has yet to demonstrate significant advantages to the adipofascial flap, since early findings indicate that osteomyelitis rates are not influenced by the new modification at a significant level. Randomized prospective studies that include objective visualization of the blood flow through ICG or MRI follow-up imaging should lend support to the findings of this preliminary study.

Karsten Schmidt

Department of Trauma, Hand, Plastic and
Reconstructive Surgery
Julius Maximilians Universität Würzburg
Oberduerrbacherstr. 6
Würzburg D-97080
Germany
E-mail: schmidt_k@ukw.de

REFERENCES

1. Tampe U, Weiss RJ, Stark B, et al. Lower extremity soft tissue reconstruction and amputation rates in patients with open tibial fractures in Sweden during 1998–2010. *BMC Surg.* 2014;14:80.
2. Cherubino M, Corno M, Ronga M, et al. The adipo-fascial ALT flap in lower extremities reconstruction gustillo IIIC-B fractures.

- An osteogenic inducer? *J Invest Surg.* 2019;1–6 [Epub ahead of print].
3. Cho EH, Shammam RL, Carney MJ, et al. Muscle versus fasciocutaneous free flaps in lower extremity traumatic reconstruction: A multicenter outcomes analysis. *Plast Reconstr Surg.* 2018;141:191–199.
 4. Kerfant N, Bertheuil N, Herlin C, et al. Muscle versus fasciocutaneous free flaps in lower extremity traumatic reconstruction: A multicenter outcomes analysis. *Plast Reconstr Surg.* 2018;141:974e–975e.
 5. Masquelet AC, Romana MC, Wolf G. Skin island flaps supplied by the vascular axis of the sensitive superficial nerves: Anatomic study and clinical experience in the leg. *Plast Reconstr Surg.* 1992;89:1115–1121.
 6. Hasegawa M, Torii S, Katoh H, et al. The distally based superficial sural artery flap. *Plast Reconstr Surg.* 1994;93:1012–1020.
 7. Arikawa M, Miyamoto S, Fujiki M, et al. Comparison of donor site drainage duration and seroma rate between latissimus dorsi musculocutaneous flaps and thoracodorsal artery perforator flaps. *Ann Plast Surg.* 2017;79:183–185.
 8. Wong CH, Wei FC. Anterolateral thigh flap. *Head Neck.* 2010;32:529–540.
 9. Al-Qattan MM. A modified technique for harvesting the reverse sural artery flap from the upper part of the leg: Inclusion of a gastrocnemius muscle “cuff” around the sural pedicle. *Ann Plast Surg.* 2001;47:269–74, discussion 274.
 10. Wei JW, Dong ZG, Ni JD, et al. Influence of flap factors on partial necrosis of reverse sural artery flap: A study of 179 consecutive flaps. *J Trauma Acute Care Surg.* 2012;72:744–750.
 11. Schmidt K, Jakubietz M, Djalek S, et al. The distally based adipofascial sural artery flap: Faster, safer, and easier? A long-term comparison of the fasciocutaneous and adipofascial method in a multimorbid patient population. *Plast Reconstr Surg.* 2012;130:360–368.
 12. Suliman MT. Distally based adipofascial flaps for dorsal foot and ankle soft tissue defects. *J Foot Ankle Surg.* 2007;46:464–469.
 13. Schmidt K, Jakubietz M, Meffert R, et al. The reverse sural artery flap—How do modifications boost its reliability? A systematic analysis of the literature. *JPRAS Open.* 2020;26:1–7.
 14. Le Fourn B, Caye N, Pannier M. Distally based sural fasciomuscular flap: Anatomic study and application for filling leg or foot defects. *Plast Reconstr Surg.* 2001;107:67–72.
 15. Schmidt K, Jakubietz M, Harenberg P, et al. The distally based adipofascial sural artery flap for the reconstruction of distal lower extremity defects. *Oper Orthop Traumatol.* 2013;25:162–169.
 16. Baumeister SP, Spierer R, Erdmann D, et al. A realistic complication analysis of 70 sural artery flaps in a multimorbid patient group. *Plast Reconstr Surg.* 2003;112:129–40; discussion 141.
 17. Parrett BM, Pribaz JJ, Matros E, et al. Risk analysis for the reverse sural fasciocutaneous flap in distal leg reconstruction. *Plast Reconstr Surg.* 2009;123:1499–1504.
 18. Sugg KB, Schaub TA, Concannon MJ, et al. The reverse superficial sural artery flap revisited for complex lower extremity and foot reconstruction. *Plast Reconstr Surg Glob Open.* 2015;3:e519.
 19. Kneser U, Bach AD, Polykandriotis E, et al. Delayed reverse sural flap for staged reconstruction of the foot and lower leg. *Plast Reconstr Surg.* 2005;116:1910–1917.
 20. Tan O, Atik B, Bekerecioglu M. Supercharged reverse-flow sural flap: A new modification increasing the reliability of the flap. *Microsurgery.* 2005;25:36–43.
 21. Tsai J, Liao HT, Wang PF, et al. Increasing the success of reverse sural flap from proximal part of posterior calf for traumatic foot and ankle reconstruction: Patient selection and surgical refinement. *Microsurgery.* 2013;33:342–349.
 22. de Blacam C, Colakoglu S, Ogunleye AA, et al. Risk factors associated with complications in lower-extremity reconstruction with the distally based sural flap: A systematic review and pooled analysis. *J Plast Reconstr Aesthet Surg.* 2014;67:607–616.
 23. Lê Thua TH, Boeckx WD, Zirak C, et al. Free intra-osseous muscle transfer for treatment of chronic osteomyelitis. *J Plast Surg Hand Surg.* 2015;49:306–310.
 24. Falagas ME, Rosmarakis ES. Recurrent post-sternotomy mediastinitis. *J Infect.* 2006;52:e151–e154.
 25. Schmidt K, Jakubietz MG, Gilbert F, et al. Quality of life after flap reconstruction of the distal lower extremity: Is there a difference between a pedicled suralis flap and a free anterior lateral thigh flap? *Plast Reconstr Surg Glob Open.* 2019;7:e2114.