

SHORT COMMUNICATION

Current-dependent ocular tilt reaction in deep brain stimulation of the subthalamic nucleus: Evidence for an incerto-interstitial pathway?

Maximilian U. Friedrich¹  | Hazem Eldebakey¹ | Jonas Roothans¹ | Philipp Capetian¹ | Andreas Zwergal^{2,3}  | Jens Volkmann¹ | Martin Reich¹

¹Department of Neurology, University Hospital Wuerzburg, Wuerzburg, Germany

²Department of Neurology, LMU University Hospital Munich, Munich, Germany

³German Center for Vertigo and Balance Disorders, LMU Munich, Munich, Germany

Correspondence

Maximilian U. Friedrich, Department of Neurology, University Hospital Wuerzburg, Josef-Schneider-Strasse 11, 97080 Wuerzburg, Germany.
Emails: Friedrich_M6@ukw.de(M.U.); Reich_M1@ukw.de(M.R.)

Funding information

MF receives funding from the Interdisciplinary Center for Clinical Research (IZKF) Z2-CSP13 at the University Hospital Wuerzburg. MMR and JV were supported by the German Research Foundation (DFG, Project-ID 424778381, TRR 295). This publication was supported by the Open Access Publication Fund of the University of Wuerzburg

Abstract

Background and purpose: The aim was to characterize a combined vestibular, ocular motor and postural syndrome induced by deep brain stimulation (DBS) of the subthalamic nucleus in a patient with Parkinson's disease.

Methods: In a systematic DBS programming session, eye, head and trunk position in roll and pitch plane were documented as a function of stimulation amplitude and field direction. Repeat ocular coherence tomography was used to estimate ocular torsion. The interstitial nucleus of Cajal (INC), zona incerta (ZI) and ascending vestibular fibre tracts were segmented on magnetic resonance imaging using both individual and normative structural connectomic data. Thresholded symptom-associated volumes of tissue activated (VTA) were calculated based on documented stimulation parameters.

Results: Ipsilateral ocular tilt reaction and body lateropulsion as well as contralateral torsional nystagmus were elicited by the right electrode in a current-dependent manner and subsided after DBS deactivation. With increasing currents, binocular tonic upgaze and body retropulsion were observed. Symptoms were consistent with an irritative effect on the INC. Symptom-associated VTA was found to overlap with the dorsal ZI and the ipsilateral vestibulothalamic tract, while lying rather distant to the INC proper. A ZI-to-INC 'incerto-interstitial' tract with contact to the medial-uppermost portion of the VTA could be traced.

Conclusion: Unilateral stimulation of INC-related circuitry induces an ipsilateral vestibular, ocular motor and postural roll-plane syndrome, which converts into a pitch-plane syndrome when functional activation expands bilaterally. In this case, tractography points to an incerto-interstitial pathway, a tract previously only characterized in non-human primates. Directional current steering proved useful in managing this rare side effect.

KEYWORDS

deep brain stimulation, movement disorders, vestibular

Jens Volkmann and Martin Reich contributed equally.

This is an open access article under the terms of the Creative Commons Attribution-NonCommercial License, which permits use, distribution and reproduction in any medium, provided the original work is properly cited and is not used for commercial purposes.

© 2022 The Authors. *European Journal of Neurology* published by John Wiley & Sons Ltd on behalf of European Academy of Neurology.

INTRODUCTION

Deep brain stimulation (DBS) is an established treatment in movement disorders. Connectomic approaches using 'volume of tissue activated' (VTA) models shape understanding of DBS action on functional networks and may help in optimizing treatment efficacy [1]. In single cases of DBS for movement disorders, subtle vestibulo-perceptive signs like deviations of the subjective visual vertical (SVV) and altered motion perception have been reported [2]. Vestibular-ocular motor (VOM) side effects such as an ocular tilt reaction (OTR), however, are highly unusual, probably due to stimulation targets lying remote from mesodiencephalic VOM reflex arcs. Therefore, VOM deficits have so far only rarely been reported in the context of DBS. In one case, ipsiversive OTR and contraversive torsional nystagmus was described after implantation of an electrode into the periaqueductal grey, which required electrode repositioning and deactivation of the impulse generator [3]. The authors assumed irritative effects on the interstitial nucleus of Cajal (INC), which is the neural integrator for vertical-torsional eye and head movements and the projection target for otolith and vertical semicircular canal signals conveyed through the medial longitudinal fasciculus (MLF) [4,5]. This hypothesis is in line with experimental evidence demonstrating ipsiversive OTR as a stereotypically coordinated eye-head synkinesis evoked by electrical stimulation of the rostral midbrain tegmentum [6], as well as seminal work on the mesodiencephalic and pontomedullary circuitry involved in processing of graviceptive signals [7].

CASE DESCRIPTION

History

A 58-year-old patient with Parkinson's disease reported perceiving 'poles tilted like the tower of Pisa' since activation of DBS of the subthalamic nucleus (Boston Scientific® Gevia/Cartesia) implanted 1 year prior. After a DBS programming session 3 months post implantation he started noticing a further increase of these symptoms, which were then accompanied by a rightward head tilt and falling tendency to the right. In this programming session, the right electrode's field was steered towards the lowermost contact in an attempt to alleviate a persisting, moderate left sided hypokinesia. He denied vertigo, diplopia, or other focal neurological signs. He reported two situations where he nearly fell to the right side upon turning. Once a keen cyclist, he had more and more refrained from riding his bike due to perceived trouble keeping his balance. Initially, the patient did not associate these balance issues with preceding DBS programming sessions and rather accounted the symptoms to parkinsonism per se.

Clinical and quantitative neuro-otological and -ophthalmological examination

In the medication/stimulation ON state, a left-dominant hypokinetic-rigid syndrome (Unified Parkinson's Disease Rating Scale III 14

points, DBS improvement in meds-off 62%), rightward head tilt and lateropulsion besides difficulties in tandem walking were noted. Neuro-ophthalmological assessment revealed a complete rightward OTR with conjugate 10° clockwise ocular torsion as disclosed on non-mydratic fundus photography and a binocular rightward 10° SVV deviation using the bedside bucket test [8]. Ocular coherence tomography disclosed residual clockwise ocular torsion of -9.5°/-2.1° (right/left eye) shortly after DBS deactivation decreasing to -4.7°/0.6° after overnight withdrawal (Figure 1a). Apparative neuro-otological assessment (including video head impulse test) was unremarkable.

DBS programming

Systematic testing of DBS parametrization (130 Hz, 60 µs) revealed that OTR was influenced exclusively and reproducibly by contact 14 (facing supero-postero-medially) of the right lead. OTR magnitude could be modulated linearly starting from 5° rightward SVV deviation at 1.8 mA to approximately 10° at 2.2 mA and 25° at 4.5 mA (Figure 1b) accompanied by increasing rightward lateropulsion, skew deviation, and a torsional nystagmus beating to the left (Video S1). Upon further increase, binocular tonic upgaze and diagonal lateropulsion evolved into retropulsion, requiring the exploration to be stopped immediately. The patient felt 'being drawn rightwards'. Anterolateral current steering on the same level reduced vestibular effects (1.4 mA, 7° SVV) while preserving antiparkinsonian effects (Unified Parkinson's Disease Rating Scale III 12 points).

Imaging and VTA modelling

Cranial computed tomography disclosed no intracranial pathologies but a relatively obtuse and caudal trajectory of the right electrode. Lead localization and VTA modelling (Figure 2) disclosed the extension of VOM-syndrome-related VTA portions supero-postero-medially towards the dorsal zona incerta (dZI) (Figure 1b-d). VTA also overlapped with the ipsilateral vestibulo-thalamic tract (iVTT) and a tract projecting from the dZI towards the INC (Figure 1c,d).

DISCUSSION

Several nodes and projections of vestibular, ocular motor, and sensorimotor networks reside in the region of the mesodiencephalic junction and therefore may be potential anatomical substrates of the complex observations reported in this case.

From a clinical and neuroanatomical perspective, the ocular motor and postural findings in our case can primarily be related to the INC, which serves as the integrator of eye and head position along the roll and pitch plane [7]. Converging lines of experimental and clinical evidence on torsional and vertical eye and head control centre around the INC area [5]. Unilateral damage to ascending

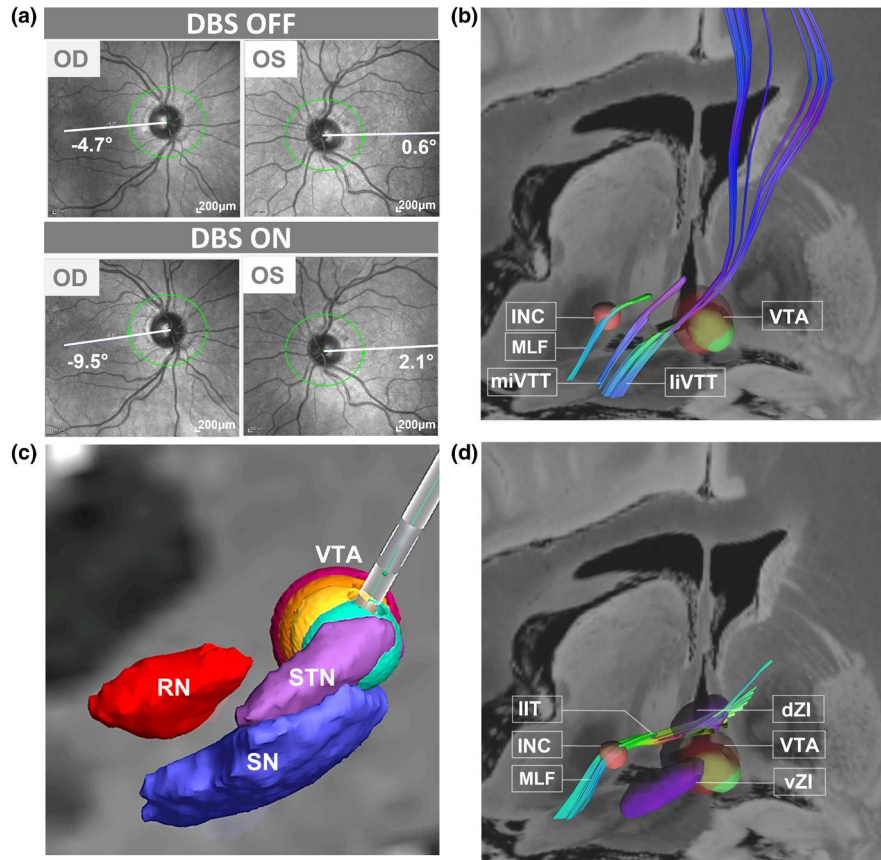


FIGURE 1 Synopsis of findings. (a) Ocular coherence tomography shows a conjugate clockwise ocular torsion in the DBS ON more than the OFF condition. (b) Electrode localization relative to neuroanatomic landmark structures SN (blue), RN (red) and STN (pink). Vestibulo-ocular motor related VTA models for amplitudes generating 5° OTR (green), 10° OTR (yellow), additional tonic upgaze (orange) and 20°–25° OTR and body retropulsion (dark red) are superimposed on an individual coronal T1w magnetic resonance image. Vestibulo-ocular motor related VTAs extend in the supero-medial direction. (c) Visualization of the VTA portions (green, minimal vestibular symptoms; red, maximal vestibular symptoms) relative to the INC, as well as the ipsilaterally ascending medial and lateral vestibular white matter tracts conveying vestibulo-perceptive signals to the cortex via the thalamic paramedian and posterolateral nuclei respectively. VTA lies remote of INC and MLF. (d) Tracing of an incerto-interstitial fibre tract connecting dorsal zona incerta and ipsilateral INC which is reached by the uppermost and medial border of symptom-associated VTA. INC, interstitial nucleus of Cajal; miVTT/liVTT, medial/lateral ipsilateral vestibulo-thalamic tract; MLF, medial longitudinal fascicle; OTR, ocular tilt reaction; RN, red nucleus; SN, substantia nigra; STN, subthalamic nucleus; VTA, volume of tissue activated; dZI/vZI, dorsal/ventral zona incerta. See Supplemental Methods for details

vestibular projections targeting the INC at midbrain level induce a contraversive OTR [9], while damage to the INC somata per se additionally results in ipsiversive torsional nystagmus [5]. In line, contraversive nystagmus with electrical stimulation of the INC has been reported in primates [4]. In our case, it is reasoned that a gradual excitation of projections to the INC can explain the current-dependent OTR ipsilateral to DBS, while contralateral torsional nystagmus at higher currents speaks for additional activation of integrator neurons directly in the INC [4,5]. Importantly, these findings closely correspond to reports of paroxysmal ipsiversive OTR hypothesized to originate from irritative effects of mesodiencephalic lesions on INC and/or rostral interstitial nucleus of the MLF (riMLF) neurons [10,11]. To the best of our knowledge, this case is the first to recapitulate a lesional eye movement disorder in a reversible manner by means of electrical stimulation, thereby corroborating abnormal excitation of the INC as a pathomechanistic underpinning of ipsiversive OTR.

Evolving conjugate tonic upgaze and retropulsion indicate a propagation of excitation across the midline [5]. Given the topographical relations and comparably low stimulation amplitudes, direct current spread over the midline can be excluded as a mechanism. With dense posterior commissure projections interconnecting the bilateral INC [5], synaptic mechanisms for signal transmission to the contralateral INC could be presumed. This transition of ocular motor and postural symptoms from roll to pitch plane with increase of stimulation currents is consistent with the ‘double roll = pitch’ framework [7]. However, conversely, experimental evidence in primates demonstrates a similar upward ocular motor bias with bilateral lesions to the INC areas resulting in downbeat nystagmus [9]. The most parsimonious explanation for this finding may be dose- and tissue-dependent differential effects of DBS like axonal excitation evolving into somatic inhibition, inducing complex network effects [12]. However, the differential

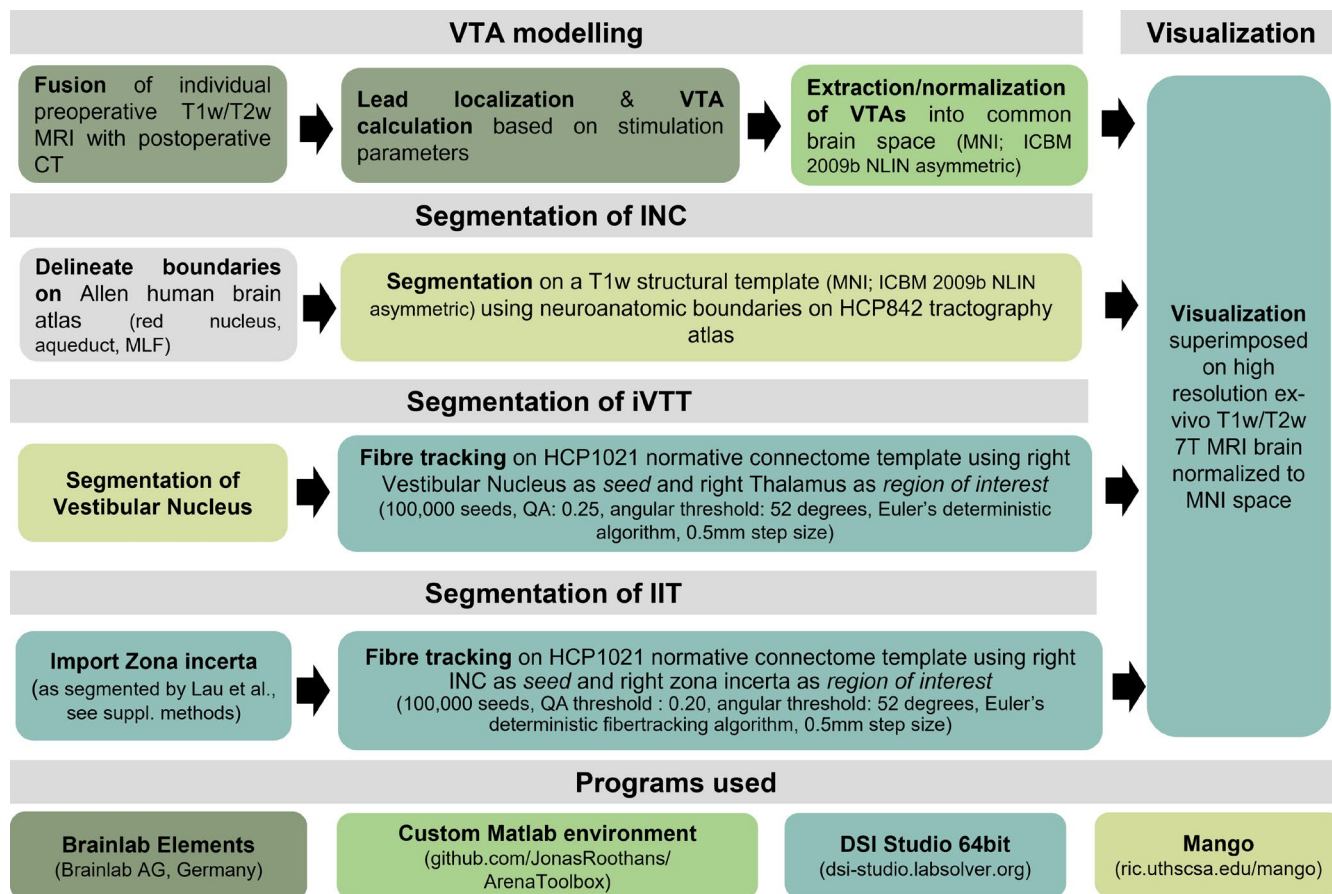


FIGURE 2 Imaging workflow for modelling of volume of tissue activated, segmentation of ipsilateral vestibulothalamic (iVTT), incerto-interstitial (IIT) tracts and interstitial nucleus of Cajal (INC). Worksteps are color-coded depending on the program used. See Supplemental Methods for details

effects of DBS on sensorimotor networks remains an area of active debate.

Involvement of the nuclear centres of eye movement (third and fourth cranial nerve) or the riMLF seems highly unlikely. The binocular pattern of vertical dissociation and torsional conjugacy, as well as the absence of double vision, argue against a lesion to the third and fourth nerve nucleus or fascicle. Ipsilateral excitation of the riMLF by DBS should result in an ipsiversive torsional nystagmus based on previous experimental considerations [5], while a contraversive torsional nystagmus was present in our case.

Neuroanatomical modelling of the VTA indicated no overlap with the INC but only with the ZI and the iVTT. Importantly, however, a projection from the ZI to the INC could be traced (Figure 1d). Therefore, it is hypothesized that INC modulation in this patient was most probably induced through a potentially aberrant 'incerto-interstitial tract'. A similar tract was reported several decades ago in the cat, where stimulation led to excitation of the ipsilateral INC and resulted in an ipsiversive OTR-like pattern [13]. Moreover, simultaneous modulation of iVTT axons may additionally contribute to the enormous SVV deviation [14], in line with theoretical considerations of tissue-dependent differential effects of DBS [12].

These case-based findings should of course be interpreted with caution and confirmed in prospective studies, potentially correlating fine-grain ocular motor assays to VTA topographies. Nonetheless, this case has three relevant aspects: (i) it gives mechanistic insight into the functional anatomy of plane-specific control of the eye, head and body position in the midbrain, (ii) it allows inferences about modes of action of DBS in sensorimotor circuits and (iii) it underscores the utility of directional DBS for optimizing treatment efficacy.

ETHICS AND INSTITUTIONAL REVIEW BOARD APPROVAL, CONSENT TO PARTICIPATE AND DISCLOSE

Patient gave informed written consent to consent, disclose and for publication of this retrospective study which was exempt from local Institutional Review Board approval.

ACKNOWLEDGEMENTS

The authors want to thank Dr Miriam Buerklein (University Hospital Wuerzburg, Department of Otorhinolaryngology) and Professor

Martin Nentwich as well as Christoph Kalantari (University Hospital Wuerzburg, Department of Ophthalmology) for their assistance in neuro-otological and neuro-ophthalmological assessments. Professor Dr Anja Horn-Bochtler (University Munich, Institute of Anatomy and Cell Biology) is thanked for a fruitful discussion. Open access funding enabled and organized by ProjektDEAL.

CONFLICT OF INTEREST

MMR reports grant support and honoraria for speaking from Medtronic and Boston Scientific, outside the submitted work. JV reports grants and personal fees from Medtronic Inc., grants and personal fees from Boston Scientific, personal fees from St Jude, outside the submitted work.

AUTHOR CONTRIBUTIONS

Maximilian Uwe Friedrich: Conceptualization (lead); data curation (lead); formal analysis (lead); investigation (lead); methodology (equal); project administration (lead); validation (equal); visualization (equal); writing—original draft (lead); writing—review and editing (lead). Hazem Eldebakey: Formal analysis (equal); investigation (supporting); methodology (equal); resources (supporting); validation (equal); visualization (equal). Jonas Roothans: Formal analysis (equal); investigation (equal); methodology (equal); software (lead); validation (supporting); visualization (supporting). Philipp Capetian: Data curation (supporting); investigation (supporting); supervision (supporting). Andreas Zwergal: Conceptualization (equal); formal analysis (equal); investigation (equal); supervision (lead); writing—original draft (equal); writing—review and editing (equal). Jens Volkmann: Project administration (equal); resources (lead); supervision (lead); writing—review and editing (equal). Martin Reich: Conceptualization (equal); investigation (equal); methodology (equal); project administration (equal); resources (equal); software (equal); supervision (equal); validation (equal); writing—original draft (equal); writing—review and editing (equal).

DATA AVAILABILITY STATEMENT

Non-identifiable data are available upon reasonable request to the corresponding author.

ORCID

Maximilian U. Friedrich  <https://orcid.org/0000-0002-3695-1268>

Andreas Zwergal  <https://orcid.org/0000-0002-3839-8398>

REFERENCES

- Horn A, Reich M, Vorwerk J, et al. Connectivity predicts deep brain stimulation outcome in Parkinson disease. *Ann Neurol*. 2017;82:67-78.
- Shaikh AG, Straumann D, Palla A. Motion illusion—evidence towards human vestibulo-thalamic projections. *Cerebellum*. 2017;16:656-663.
- Lueck CJ, Hamlyn P, Crawford TJ, et al. A case of ocular tilt reaction and torsional nystagmus due to direct stimulation of the midbrain in man. *Brain*. 1991;114:2069-2079.
- Crawford JD, Cadera W, Vilis T. Generation of torsional and vertical eye position signals by the interstitial nucleus of Cajal. *Science*. 1991;252:1551-1553.
- Büttner U, Büttner-Ennever JA, Rambold H, Helmchen C. The contribution of midbrain circuits in the control of gaze. *Ann N Y Acad Sci*. 2002;956:99-110.
- Westheimer G, Blair SM. The ocular tilt reaction: a brainstem oculomotor routine. *Investig Ophthalmol*. 1975;14(11):833-839.
- Brandt T, Dieterich M. Central vestibular syndromes in roll, pitch, and yaw planes: topographic diagnosis of brainstem disorders. *Neuro-Ophthalmology*. 1995;15:291-303.
- Zwergal A, Rettinger N, Frenzel C, et al. A bucket of static vestibular function. *Neurology*. 2009;72:1689-1692.
- Helmchen C, Rambold H, Fuhry L, Büttner U. Deficits in vertical and torsional eye movements after uni- and bilateral muscimol inactivation of the interstitial nucleus of Cajal of the alert monkey. *Exp Brain Res*. 1998;119:436-452.
- Oh S-Y, Choi K-D, Shin B-S, et al. Paroxysmal ocular tilt reactions after mesodiencephalic lesions: report of two cases and review of the literature. *J Neurol Sci*. 2009;277:98-102.
- Kremmyda O, Frenzel C, Strupp M. Late attacks of paroxysmal ocular tilt reaction. *Neurology*. 2016;87:1304.
- Ashkan K, Rogers P, Bergman H, Ughratdar I. Insights into the mechanisms of deep brain stimulation. *Nat Rev Neurol*. 2017;13:548-554.
- Hyde JE, Toczek S. Functional relation of interstitial nucleus to rotatory movements evoked from zona incerta stimulation. *J Neurophysiol*. 1962;25(4):455-466. doi:10.1152/jn.1962.25.4.455
- Zwergal A, Büttner-Ennever J, Brandt T, Strupp M. An ipsilateral vestibulothalamic tract adjacent to the medial lemniscus in humans. *Brain*. 2008;131:2928-2935.

SUPPORTING INFORMATION

Additional supporting information may be found in the online version of the article at the publisher's website.

How to cite this article: Friedrich MU, Eldebakey H, Roothans J, et al. Current-dependent ocular tilt reaction in deep brain stimulation of the subthalamic nucleus: Evidence for an incerto-interstitial pathway? *Eur J Neurol*. 2022;29:1545-1549. doi:[10.1111/ene.15257](https://doi.org/10.1111/ene.15257)