



Perfusion Changes in Perforator-Based Propeller Flaps

Silvia Bernuth, MD¹ Adrian Vater, MD¹ Konrad F. Fuchs, MD² Rainer H. Meffert, MD²
Rafael G. Jakubietz, MD¹

¹ Department of Plastic and Reconstructive Surgery, Clinic of Trauma, Hand, Plastic and Reconstructive Surgery, University Hospital Wuerzburg, Wuerzburg, Germany

² Clinic of Trauma, Hand, Plastic and Reconstructive Surgery, University Hospital Wuerzburg, Wuerzburg, Germany

Address for correspondence Silvia Bernuth, MD, Department of Plastic and Reconstructive Surgery, Clinic of Trauma, Hand, Plastic and Reconstructive Surgery, University Hospital Wuerzburg, Oberduerrbacher Str. 6, Wuerzburg 97080, Germany (e-mail: Bernuth_s@ukw.de).

J Reconstr Microsurg Open 2023;8:e45–e50.

Abstract

Background To cover soft tissue defects, the perforator-based propeller flap offers the option to rotate healthy tissue into complex wounds. By rotating the flap, the perforator is torqued. As a result, perfusion changes are possible.

Methods A retrospective data analysis of patients was done, who received a propeller flap to cover soft tissue defects of the lower extremity as well as a peri- and postoperative perfusion monitoring with a laser-Doppler-spectrophotometry system. Additionally, patient-specific data were collected.

Results Seven patients were identified. Four patients experienced early complications, two epidermolysis of the distal flap areas, three wound healing disorders, and one partial flap necrosis. Intraoperative perfusion monitoring showed a decline of blood flow after incision of the flap, especially at distal flap site. In case of complications, there were prolonged blood flow declines up to the first postoperative day.

Conclusion Torquing the perforator by rotating the flap can cause an impairment in inflow and outflow. If the impairment is prolonged, perfusion-associated complications are possible. The identification of a viable perforator is particularly important. In addition, a conservative postoperative mobilization is necessary to compensate for the impaired and adapting outflow.

Keywords

- ▶ propeller flap
- ▶ perfusion
- ▶ lower extremity

Soft tissue defects of the lower extremity are often classified as complex wounds. Exposed structures such as tendons, neurovascular bundles, bones, and osteosynthesis material require technical complex methods, often with the need for tissue transfer. Perforator flaps represent a good option for mid-size defects. Although, especially in adipose patients, a free perforator flap may be too bulky to allow for normal footwear postoperatively.

The perforator-based propeller flap is a good alternative as a local flap. Due to its structural similarity to the surrounding tissue, the lack of microvascular anastomosis, and low donor site morbidity, it is particularly well suited for the distal lower extremity and ankle. Perforators are found along the main vessels of the lower extremity.^{1–7} Furthermore, the donor site may be placed over muscle, which shifts the original complex defect over graftable tissue (▶ **Fig. 1**).^{2,8}

received
October 25, 2022
accepted after revision
February 28, 2023
accepted article online
May 4, 2023

DOI <https://doi.org/10.1055/a-2086-4988>.
ISSN 2377-0813.

© 2023. The Author(s).

This is an open access article published by Thieme under the terms of the Creative Commons Attribution-NonDerivative-NonCommercial-License, permitting copying and reproduction so long as the original work is given appropriate credit. Contents may not be used for commercial purposes, or adapted, remixed, transformed or built upon. (<https://creativecommons.org/licenses/by-nc-nd/4.0/>)

Thieme Medical Publishers, Inc., 333 Seventh Avenue, 18th Floor, New York, NY 10001, USA

Complication rates of propeller flaps are reported in up to 12 to 40% of cases.^{2,9–13} Thus, a postoperative, objective perfusion monitoring is advantageous as perfusion areas of perforators can vary individually^{2,14} and rotation of the pedicle brings a higher risk of vascular complications.

The laser-Doppler-spectrophotometry (LDSP) is a useful tool to monitor microperfusion of flaps. It detects tissue oxygenation, relative hemoglobin content, and flow rate of deep dermal and subdermal layers. These parameters not only measure general perfusion, but also allow a differentiation between inflow and outflow changes. Thereby, perfusion changes can be detected faster and more precise than clinical evaluation alone.

Since partial flap necrosis equals a complete flap loss, understanding microcirculation after pedicle rotation is fundamental to assess post rotation flap perfusion. In this study, perioperative perfusion data of propeller flaps were analyzed to elucidate microcirculatory changes.

Methods

A retrospective data analysis of patient treated between 2017 and 2021 was performed. All data were gathered at the department of plastic and aesthetic surgery at the clinic of trauma, hand, plastic and reconstructive surgery at the university hospital in Würzburg, Germany. Only patients with soft tissue defect of the lower extremity were included. Seven patients treated with propeller flaps and monitored peri- and postoperative by a LDSP system were included. Patient data like gender, age, defect cause, and location as well as comorbidities were evaluated. Additionally, perioperative data and complications were evaluated.

Monitoring of propeller flap was performed with the LDSP system (O2C) of LEA Medizintechnik GmbH (Gießen, Germany) was used. Two monitoring points were defined: perforator and farthest point from perforator (distal). Measurements were made preoperative at the planned and marked flap area, intraoperative after incision, rotation, 1 hour after rotation, as well as postoperatively that same day and on the first, third, fifth, and seventh day postoperatively. At every monitoring time point, three consecutive measurements were used to calculate the mean.

The LDSP is a noninvasive diagnostic system that uses an external probe to apply two measurement methods. The spectrophotometry system detects reflected light that was emitted by the probe (830 nm at 30 mW and 500–800 nm at 20 W) and calculates the relative hemoglobin content (rHb in AU) as well as tissue oxygenation (SO₂ in percent). Because emitted light is absorbed completely by vessels with a diameter larger than 100 µm, light detected is reflected by the arterioles and venules of the dermal and subdermal plexus. Additionally, the laser-Doppler method is used to detect the velocity of erythrocytes, which is used to calculate the relative flow rate (flow in AU).

Results

From 2017 to 2021, soft tissue coverage was performed in seven patients using propeller flaps. Of these, six were male

and one was female with a median age of 62 years. All flaps were performed by the same surgeon. The cause of defect was posttraumatic in five patients, of which three patients had a primary posttraumatic defect and two a wound healing disorder after osteosynthetic treatment. One patient had a vascular and one a tumor-related defect genesis.

All defects were located at the lower extremity. Six patients had wound contamination. *Staphylococcus aureus* was the most commonly detected pathogen. All patients underwent regular debridements and wound conditioning using low-pressure wound therapy (vacuum-assisted closure) prior to coverage. Furthermore, all patients received perioperative pathogen-specific intravenous antibiotics. Four of the seven patients had comorbidities, of which arterial hypertension, diabetes mellitus, and arterial occlusive disease were the most common.

Particularly, in the case of defects caused by trauma, there was a clear difference in the time to defect coverage. Primary post-traumatic defects were covered after an average of 15.3 days. In contrast, in wound healing disorder after osteosynthetic treatment, it took an average of 76.5 days until coverage (►Table 1).

Four patients experienced early complications (57%), two epidermolysis of the distal flap areas (29%), three wound healing disorders (43%), and one partial flap necrosis (14%). Among these, partial flap necrosis was the only early complication requiring surgery. In the course of an infectious pseudarthrosis, one patient had a late complication (14%) with a partial flap necrosis in the critical distal flap area also requiring surgical revision.

Intraoperative perfusion monitoring showed a decline of blood flow after incision of the flap up to 1 hour after rotation, especially at distal flap site. In contrast, rHb and SO₂ increased after incision. Subsequently, SO₂ fell and recovered relative with a slight delay to the restoration of the blood flow, especially at distal flap site. The data also showed a prolonged increase in rHb and a slow normalization over the observation period of 7 days (►Fig. 2).

In order to see differences between the cases with complications and complication-free cases, data were analyzed groupwise.

In the complication-free cases, a decrease in blood flow, particularly at the distal flap site, was observed up to 1 hour after rotation, which normalized within the initial postoperative hours. There was also an increase of blood flow and a hyperemic period on the first postoperative day. All measurement parameters normalized during the first postoperative week (►Fig. 3).

With regard to the cases with complications, there was a clear prolonged drop in blood flow at distal flap site up to the first postoperative day. This was reflected in the SO₂ with a slight time lag (►Fig. 4).

An increase in rHb was found in complication-free as well as cases with complications with the highest values at distal flap site of the cases with complications (►Figs. 3 and 4).

Discussion

Covering soft tissue defects with propeller flaps is beneficial in many ways, especially at the distal lower extremity.

Table 1 Patient data

Patients			7
Male			6
Female			1
Median age (y)			62
Diagnosis	Trauma	Posttrauma soft tissue defect	3
		Postoperative wound break down	2
	Tumor		1
	Vascular genesis	Arterial	1
Location of defect	Thigh		2
	Lower leg		1
	Ankle		3
	Foot		1
Perforator		Medial of anterior tibialis posterior	3
		Lateral of anterior fibularis	2
		Medial thigh	2
Mean incision/suture time (h)			02:00
Debridement before reconstruction			3
Days to reconstruction	Trauma	Post-trauma	15.3
		Postoperative wound break down	76.5
Microbial contamination	Positive		6
		Staphylococcus epidermidis	5
		Bacillus species	1
	Negative		1
Intravenous-antibiotics		Cefazolin	3
		Clindamycin	2
		Ampicillin/Sulbactam	1
		Trimethoprim/Sulfamethoxazole	1
		Amoxicillin	1
		Ciprofloxacin	1
		Combination	2
Complications		Over all patients	4
	Early	Epidermolysis	2
		Wound break down	3
		Partial flap necrosis	1
	Late	Partial flap necrosis due to infection pseudarthrosis	1
Revision surgery		Over all patients	2
Comorbidities		Over all patients	4
		Hypertension	3
		Diabetes mellitus	2
		Artery occlusive disease	1
Nicotine abuse		Over all patients	1

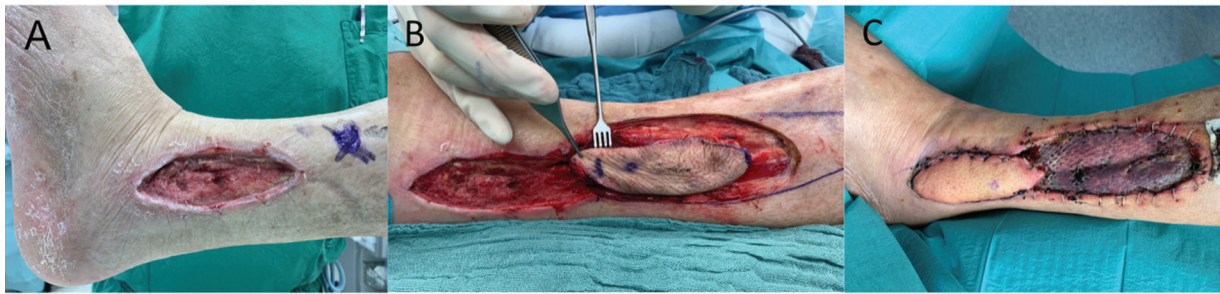

Fig. 1 (A) Soft tissue defect lateral ankle left leg; (B) 4 days postoperatively after propeller flap using a perforator of the fibular artery; (C) 7 days postoperatively.

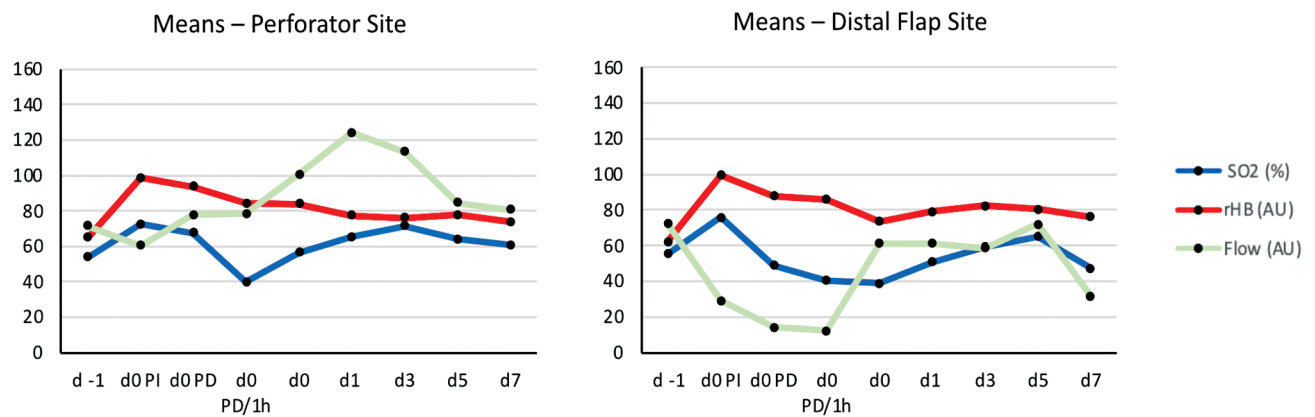


Fig. 2 Means of laser-Doppler-spectrophotometry (LDSP) data of all cases at perforator and distal flap site; measurement quantities: relative flow (in AU), tissue oxygenation (SO₂ in %), relative hemoglobin content (rHb in AU); monitoring points of time: d -1: preoperative, d0 PI: during surgery after incision, d0 PD: during surgery after rotation, d0 1h: 1 hour after rotation, d0: postoperative during day of surgery, d1: first day postoperative, d3: third day postoperative, d5: fifth day postoperative, d7: seventh day postoperative.

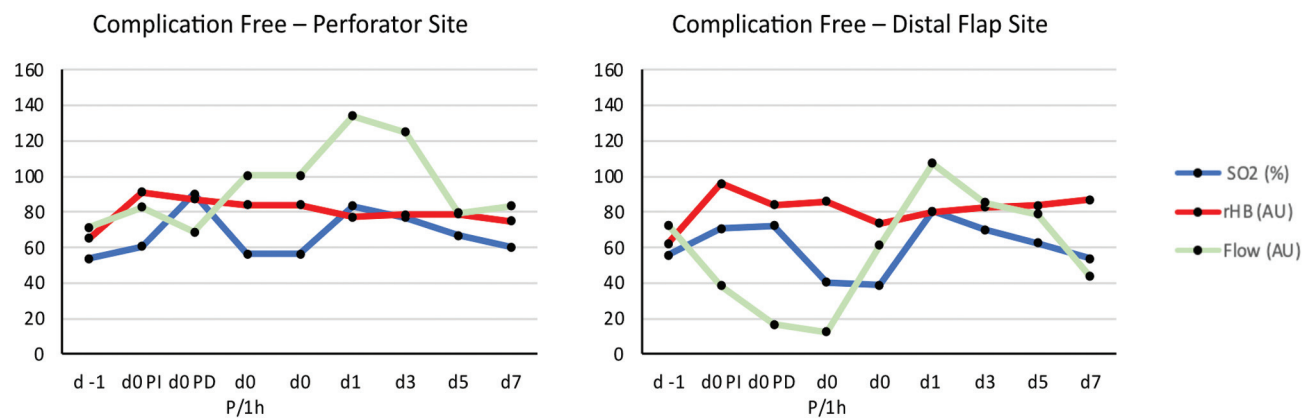


Fig. 3 Laser-Doppler-spectrophotometry (LDSP) data of complication-free cases at perforator and distal flap site; measurement quantities: relative flow (in AU), tissue oxygenation (SO₂ in %), relative hemoglobin content (rHb in AU); monitoring points of time: d -1: preoperative, d0 PI: during surgery after incision, d0 PD: during surgery after rotation, d0 1h: 1 hour after rotation, d0: postoperative during day of surgery, d1: first day postoperative, d3: third day postoperative, d5: fifth day postoperative, d7: seventh day postoperative.

In particular, morphology of this local flap is key for postoperative rehabilitation, function, and aesthetics. However, the design of the flap entails adaptation and alteration of the microcirculation, which can lead to serious complications, especially in the critical distal flap area. Moreover, the perfusion of the critical areas cannot always be clearly foreseen and assessed intraoperatively. In this

regard, the present study can provide a better understanding of perioperative perfusion changes.

A decrease of the relative blood flow (flow) was seen after flap rotation. Compared to the perforator site, there was a greater drop in relative blood flow and a prolonged adjustment period to the preoperative level at the distal flap site (► **Figs. 2** and **3**). Furthermore, SO₂ showed a decline as well a

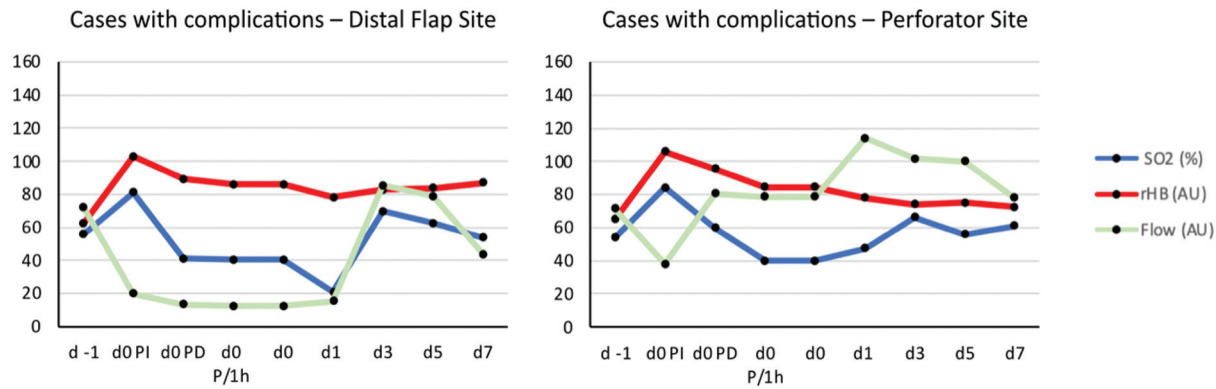


Fig. 4 Laser-Doppler-spectrophotometry (LDSP) data of complicative cases at perforator and distal flap site; measurement quantities: relative flow (in AU), tissue oxygenation (SO₂ in %), relative hemoglobin content (rHb in AU); monitoring points of time: d -1: preoperative, d0 PI: during surgery after incision, d0 PD: during surgery after rotation, d0 1h: 1 hour after rotation, d0: postoperative during day of surgery, d1: first day postoperative, d3: third day postoperative, d5: fifth day postoperative, d7: seventh day postoperative.

slight delay to the restoration of the blood flow. Torqueing of the perforator possibly causes temporary constriction of the vessel, leading to a reduction of flap perfusion and oxygen reserve. The initial SO₂ increase after flap incision is most likely due to preoxygenation during anesthesia and a possible temporary congestion after interruption of venous outflow via the subdermal plexus. As a result, a higher postcapillary oxygenation is registered based on a temporary higher erythrocyte count and a relatively lower oxygen exploitation of the capillary system. This correlates with the increase in rHb above 90 AU after flap incision, which approaches the preoperative level slower than the flow and SO₂. These perfusion changes were even more distinct in the group of the cases with complications.

Prolonged ischemia of several hours can lead to ischemic tissue damage such as epidermolysis or partial flap necrosis. With a rate of 10 to 11%, partial flap necrosis is the most common complication of the propeller flap.^{4,9,13,15} Complete flap loss as well as epidermolysis are reported up to 3 to 3.5% of cases.^{9,13} Torqueing of the perforator is assumed to be one possible cause of temporarily decreased arterial inflow. After a technical simulation, Wong et al recommended, in addition to a rotation angle of less than 180 degrees and a diameter of more than 1 mm, the preparation of the perforator of at least 3 cm length to distribute the torqueing over the distance.^{2,16} This addresses the inversely proportional relationship between rotation arc and pedicle length.¹⁵⁻¹⁸ In addition, the accompanying vein comitans, due to their low intravascular pressure and wall thickness, are particularly susceptible to collapse during torqueing.^{2,15-18} This leads not only to consecutive outflow obstruction with congestion in the flap, but also may lead to thrombosis of the draining vessels. In the present study, transient congestion was also observed due to the increased rHb and decreased flow. The rHb increased after incision of the flap and decreased during the initial postoperative period without reaching preoperative level, especially at distal flap site. Transient venous congestion of 3 to 3.5% has been reported in the literature as well.⁹ However, not only torqueing of the perforator but also interruption of the linking vessels to adjacent angio-

somes, leading to centralization of outflow after incision and contributing to transient congestion. Especially at the lower extremity, the majority of venous outflow occurs via subdermal plexus.¹⁹

Skeletonization of the perforator with the accompanying veins was reported to improve outflow. Especially at fascial level, adherences may compromise blood flow of the fragile and small venae comitans.² A meta-analysis of Bekara et al shows that most surgeons prefer skeletonization of the perforator.⁹ Additionally, intraoperative evaluation of perforator quality seems necessary. Jakubietz et al pointed out risk factors, such as small diameter (< 1 mm), fibrous adherences, arterial plaques, or macroscopic changes of vessel morphology.¹¹

Another influencing factor discussed in literature is the proximity of the perforator to the trauma area. The closer the perforator is located to the defect, the smaller the flap needs to be. This has a positive impact on perfusion at the distal flap site.²⁰ In case of trauma-related defects, however, traumatization of the surrounding tissue and thus possible posttraumatic perfusion impairment cannot be ruled out.⁸ Jakubietz et al therefore recommend a distance between perforator and defect of at least 3 cm,¹¹ despite there is no evidence of a correlation between trauma and complications so far.⁹

In addition to the previously mentioned technical influencing factors, if intraoperative clinical assessment of perfusion after rotation is difficult, intraoperative angiography with indocyanine green is possible. This allows the perfusion of the entire flap to be visualized in real time.^{21,22} Cho et al further use color Doppler ultrasonography (CDS) intra- and postoperatively to select and monitor the perforator based on flow velocity.²³

Of the four patients experiencing early complications three had arterial hypertension. The patient with partial necrosis had arterial hypertension, diabetes mellitus, and nicotine abuse as comorbidities. However, because of the small study size, these data are not statistically relevant. Nevertheless, similar observations suggesting a correlation between comorbidities affecting microcirculation and vascular-related complications are already described in the literature.¹⁰

Despite the limitations of the study such as the low number of patients and the punctual measurements of LDSP, microcirculatory changes could be seen peri- and postoperatively. With some experience, the LDSP can provide evidence of a vascular complication even before the visual clinical signs of inflow or outflow obstruction.^{24–26} However, for intraoperative and postoperative perfusion monitoring of flaps, indocyanine green angiography as well as CDS are more suitable in clinical practice, as they directly visualize blood flow in the perforator as well as in the peripheral vascular plexus. LDSP uses indirect imaging via perfusion parameters and is more suitable for physiological and pathophysiological study purposes.

Despite the previously mentioned recommendations for perforator selection and preparation, disruption of the linking vessels and consecutive centralization of outflow requires a longer adjustment. To minimize the risk of overcharging the flap, postoperative mobilization should be adapted to the free-flap protocol for the lower extremity.

Conclusion

Torquing the perforator by rotating the flap can cause an impairment in inflow and outflow. If the impairment is prolonged, perfusion-associated complications are possible. The identification of a viable perforator is particularly important. In addition, a conservative postoperative mobilization is necessary to compensate for the impaired and adapting outflow. The propeller flap is a viable option to cover lower extremity soft tissue defects. If the perforator meets the selection criteria as well as preparation recommendations and a postoperative adjustment period is given, the propeller flap can be superior to free flap coverage in selected cases.

Conflict of Interest

None declared.

References

- Jakubietz RG, Jakubietz MG, Gruenert JG, Kloss DF. The 180-degree perforator-based propeller flap for soft tissue coverage of the distal, lower extremity: a new method to achieve reliable coverage of the distal lower extremity with a local, fasciocutaneous perforator flap. *Ann Plast Surg* 2007;59(06):667–671
- Teo TC. The propeller flap concept. *Clin Plast Surg* 2010;37(04):615–626, vi
- Pignatti M, Ogawa R, Hallock GG, et al. The “Tokyo” consensus on propeller flaps. *Plast Reconstr Surg* 2011;127(02):716–722
- Gir P, Cheng A, Oni G, Mojallal A, Saint-Cyr M. Pedicled-perforator (propeller) flaps in lower extremity defects: a systematic review. *J Reconstr Microsurg* 2012;28(09):595–601
- Schaverien M, Saint-Cyr M. Perforators of the lower leg: analysis of perforator locations and clinical application for pedicled perforator flaps. *Plast Reconstr Surg* 2008;122(01):161–170
- Rad AN, Singh NK, Rosson GD. Peroneal artery perforator-based propeller flap reconstruction of the lateral distal lower extremity after tumor extirpation: case report and literature review. *Microsurgery* 2008;28(08):663–670
- Attinger C, Cooper P, Blume P. Vascular anatomy of the foot and ankle. *Operat Techniq Plastic Reconstruct Surg* 1997;4(04):183–198
- Quaba O, Quaba A. Pedicled perforator flaps for the lower limb. *Semin Plast Surg* 2006;20(02):103–111
- Bekara F, Herlin C, Somda S, de Runz A, Grolleau JL, Chaput B. Free versus perforator-pedicled propeller flaps in lower extremity reconstruction: what is the safest coverage? A meta-analysis. *Microsurgery* 2018;38(01):109–119
- Masia J, Moscattello F, Pons G, Fernandez M, Lopez S, Serret P. Our experience in lower limb reconstruction with perforator flaps. *Ann Plast Surg* 2007;58(05):507–512
- Jakubietz RG, Jakubietz DF, Gruenert JG, Schmidt K, Meffert RH, Jakubietz MG. Reconstruction of soft tissue defects of the Achilles tendon with rotation flaps, pedicled propeller flaps and free perforator flaps. *Microsurgery* 2010;30(08):608–613
- Kneser U, Beier JP, Schmitz M, et al. Zonal perfusion patterns in pedicled free-style perforator flaps. *J Plast Reconstr Aesthet Surg* 2014;67(01):e9–e17
- Nelson JA, Fischer JP, Brazio PS, Kovach SJ, Rosson GD, Rad AN. A review of propeller flaps for distal lower extremity soft tissue reconstruction: is flap loss too high? *Microsurgery* 2013;33(07):578–586
- Taylor GI, Palmer JH. The vascular territories (angiosomes) of the body: experimental study and clinical applications. *Br J Plast Surg* 1987;40(02):113–141
- Topalan M, Bilgin SS, Ip WY, Chow SP. Effect of torsion on microarterial anastomosis patency. *Microsurgery* 2003;23(01):56–59
- Wong CH, Cui F, Tan BK, et al. Nonlinear finite element simulations to elucidate the determinants of perforator patency in propeller flaps. *Ann Plast Surg* 2007;59(06):672–678
- Salgarello M, Lahoud P, Selvaggi G, Gentileschi S, Sturla M, Farallo E. The effect of twisting on microanastomotic patency of arteries and veins in a rat model. *Ann Plast Surg* 2001;47(06):643–646
- Selvaggi G, Anicic S, Formaggia L. Mathematical explanation of the buckling of the vessels after twisting of the microanastomosis. *Microsurgery* 2006;26(07):524–528
- Saint-Cyr M, Schaverien M, Arbique G, Hatfeg D, Brown SA, Rohrich RJ. Three- and four-dimensional computed tomographic angiography and venography for the investigation of the vascular anatomy and perfusion of perforator flaps. *Plast Reconstr Surg* 2008;121(03):772–780
- Chang SM, Zhang F, Xu DC, Yu GR, Hou CL, Lineaweaver WC. Lateral retromalleolar perforator-based flap: anatomical study and preliminary clinical report for heel coverage. *Plast Reconstr Surg* 2007;120(03):697–704
- Jakubietz RG, Schmidt K, Bernuth S, Meffert RH, Jakubietz MG. Evaluation of the intraoperative blood flow of pedicled perforator flaps using indocyanine green-fluorescence angiography. *Plast Reconstr Surg Glob Open* 2019;7(09):e2462
- Scaglioni MF, Macek A. Perforator propeller flaps in lower limb reconstruction: a literature review and case reports. *Plast Aesthet Res* 2019; Doi: 10.20517/2347-9264.2019.41
- Cho MJ, Kwon JG, Pak CJ, Suh HP, Hong JP. The role of duplex ultrasound in microsurgical reconstruction: review and technical considerations. *J Reconstr Microsurg* 2020;36(07):514–521
- Rothenberger J, Amr A, Schaller HE, Rahmanian-Schwarz A. Evaluation of a non-invasive monitoring method for free flap breast reconstruction using laser Doppler flowmetry and tissue spectrophotometry. *Microsurgery* 2013;33(05):350–357
- Hölzle F, Loeffelbein DJ, Nolte D, Wolff KD. Free flap monitoring using simultaneous non-invasive laser Doppler flowmetry and tissue spectrophotometry. *J Craniomaxillofac Surg* 2006;34(01):25–33
- Hölzle F, Rau A, Loeffelbein DJ, Mücke T, Kesting MR, Wolff KD. Results of monitoring fasciocutaneous, myocutaneous, osteocutaneous and perforator flaps: 4-year experience with 166 cases. *Int J Oral Maxillofac Implants* 2010;39(01):21–28